

**CARBON DIOXIDE**  
**DIGITAL SUBTRACTION**  
**ANGIOGRAPHY**  
**&**  
**INTERVENTION**

Jim Caridi  
Tulane School of Medicine  
jimcaridi@gmail.com

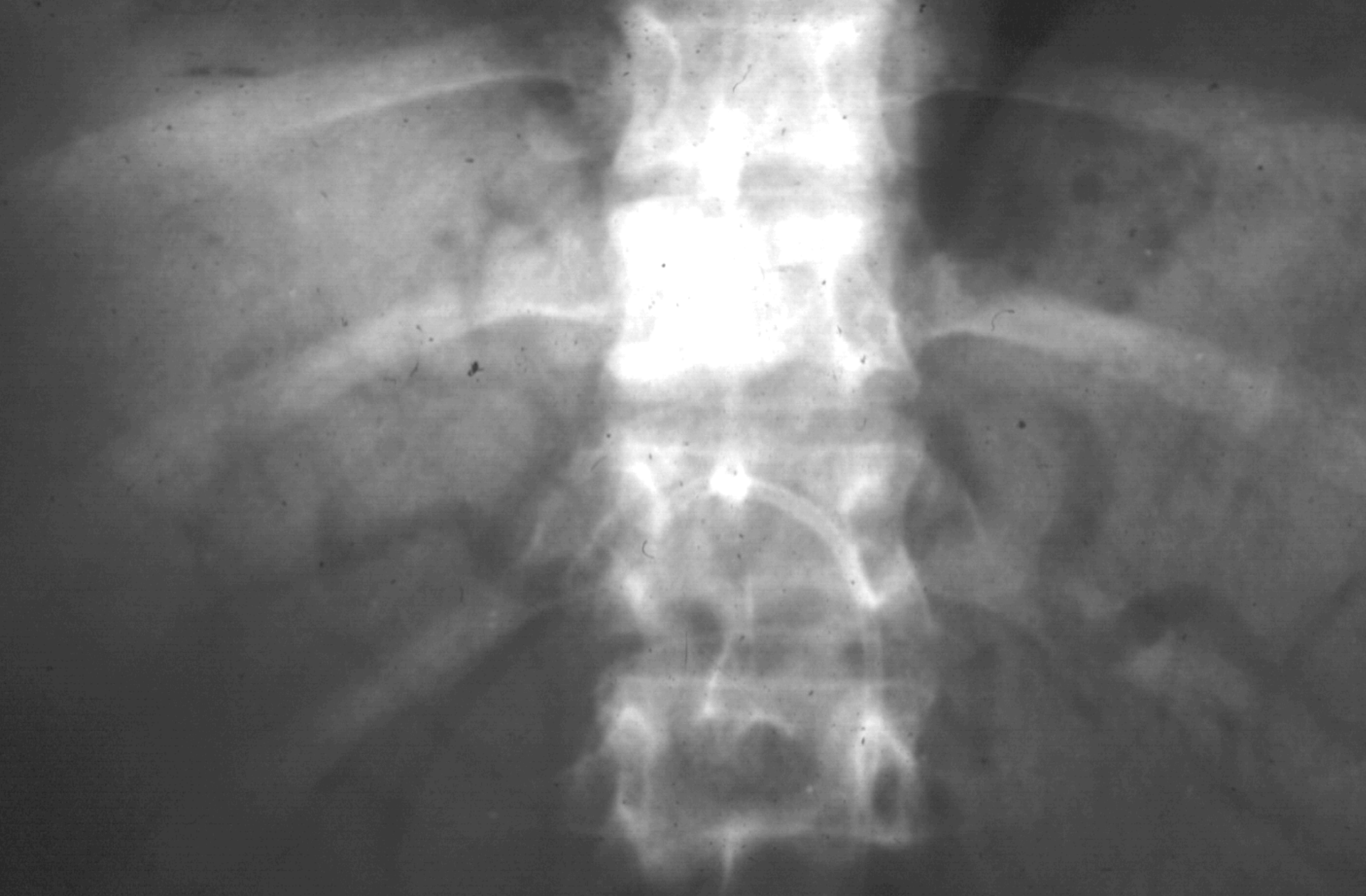# **DISCLOSURES**

**Intravascular CO<sub>2</sub> is not FDA approved**

**Reference:**

**Carbon Dioxide DSA: A comprehensive user  
guide for all operators**

**VASCULAR DISEASE MANAGEMENT  
2014;11(10):E221-E256**



**Celiac axis cut film taken in 1971 during accidental injection of room air that lead to Dr. Hawkins investigating CO<sub>2</sub> as an**

# CO<sub>2</sub> ADVANTAGES

- **Non-allergic**
- **Non-nephrotoxic (unlimited volumes)**
- **Rapidly absorbed (20 - 30X O<sub>2</sub>)**
- **Low viscosity (1/400 iodinated contrast)**
  - **Easier to use with microcatheters**
  - **Can inject in-between catheter and wire**
  - **Better detection of bleeding, AVF**
  - **Portal vein visualization**
- **Central reflux**
  - **Ability to identify vessel (ostium) central to catheter tip**
- **Cost (100 cc = .03)**

# **CO<sub>2</sub> DISADVANTAGES**

- 1. Requires unique delivery system**
- 2. Invisible – concern for undetected contamination**
- 3. Cerebral vessels should be avoided**
- 4. Bowel gas can interfere with abdominal images**
- 5. Potentially more labor intensive**

# CO<sub>2</sub> UNIQUE PROPERTIES

- **Endogenous gas**
- **Invisible**
- **Low viscosity**
- **Buoyant**
- **Compressible**

# CO<sub>2</sub> CONCERNS

- **Contamination**
- **Excessive volumes**
- **Intracerebral exposure**
- **Compressive delivery**
- **COPD**
- **Nitrous oxide anesthesia**
- **Pulmonary HTN**

# **INVISIBLE**

## **? CONTAMINATION**

### **1. Reusable CO<sub>2</sub> cylinder**

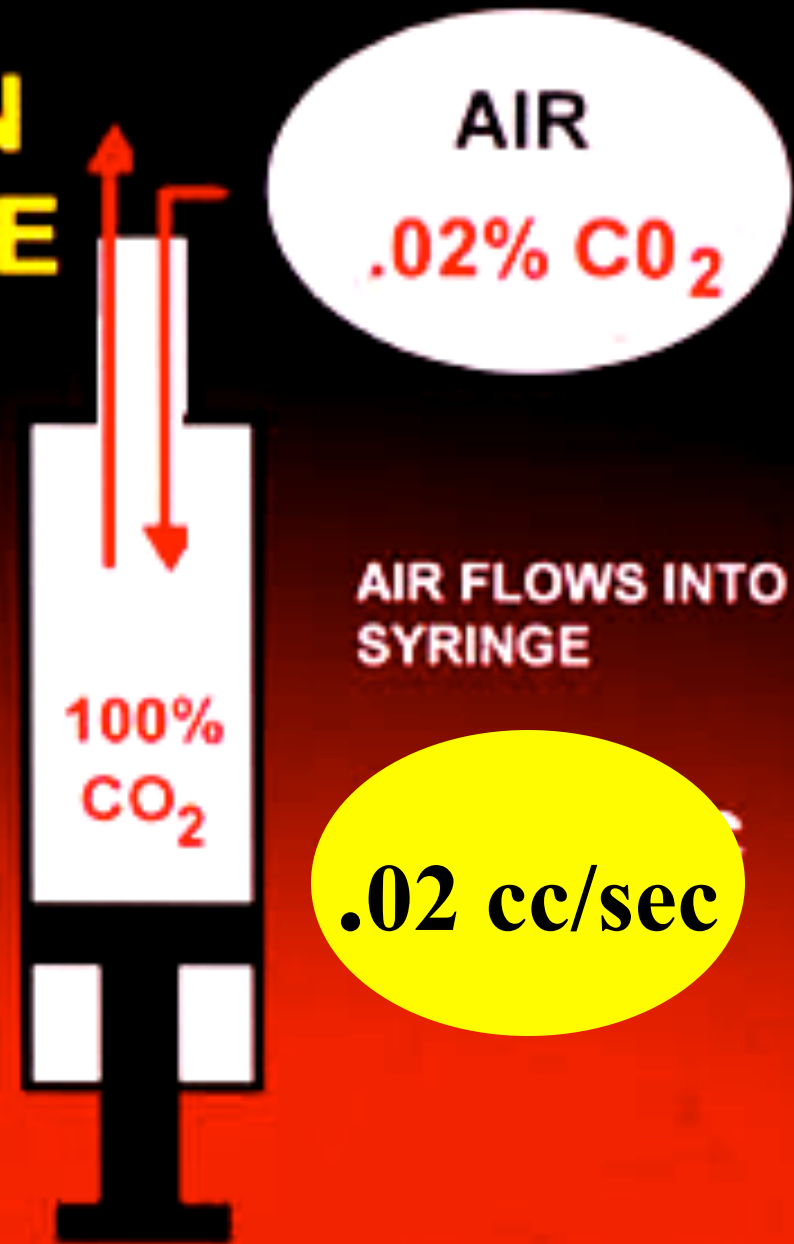
**Rust, methane, H<sub>2</sub>O, particulate matter,  
carbonic acid found over time**

### **2. Room air**

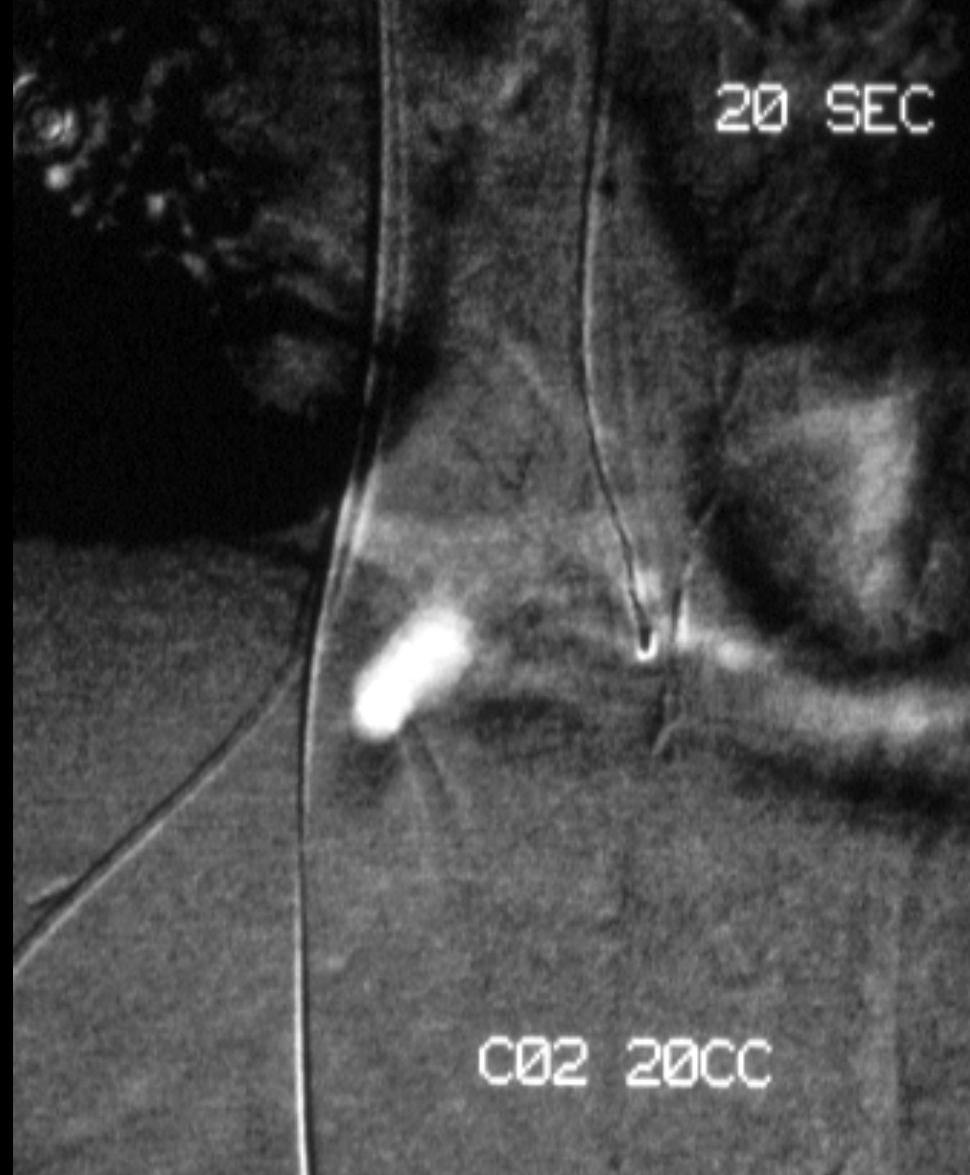
**diffusivity with open syringe  
malpositioned stopcock  
inadequate flushing**

# AIR CONTAMINATION HIGH DIFFUSION RATE FICK'S LAW

An 20 cc open  
syringe containing  
pure CO<sub>2</sub> is replaced  
by room air in 16  
min



**CO dissipates in ~ 20 secs in pulmonary artery during venous injections. If not one has to consider contamination.**



# PREVENT CONTAMINATION

1. Use a disposable source of medical grade CO<sub>2</sub>
2. Use a closed delivery system
3. Eliminate stopcocks if possible
4. Glue connections
5. Flush system 2-3 times



# CO<sub>2</sub> UNIQUE PROPERTIES

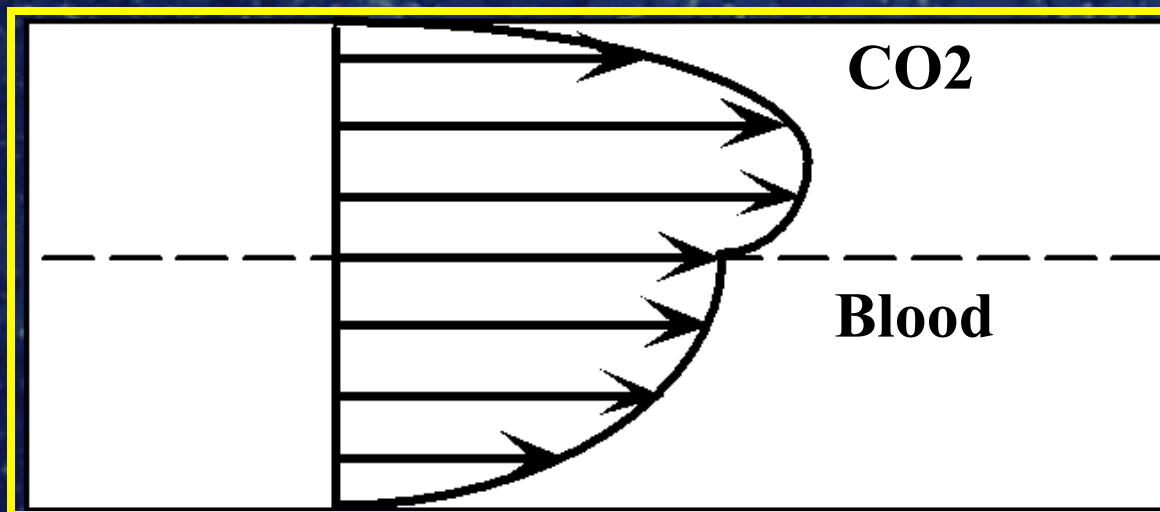

**CO<sub>2</sub> IS BOUYANT**




# BUOYANT

- **CO<sub>2</sub> doesn't mix with blood - it displaces it**
- **CO<sub>2</sub> rises to a non dependent position**
- **Anterior images easily visualized**
- **Posterior imaging depends upon displacement  
of blood**

# CO<sub>2</sub> FLOW DYNAMICS



# Buoyancy of CO<sub>2</sub>



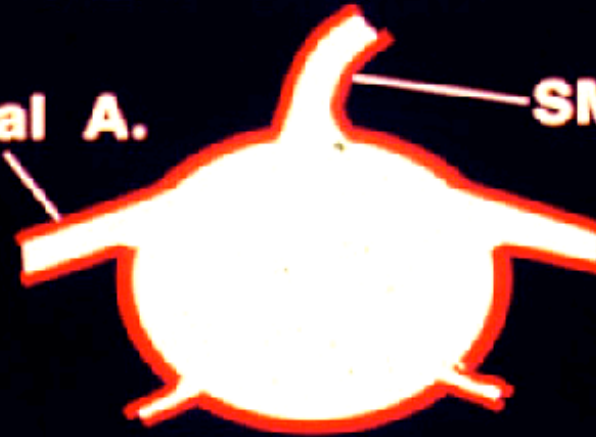
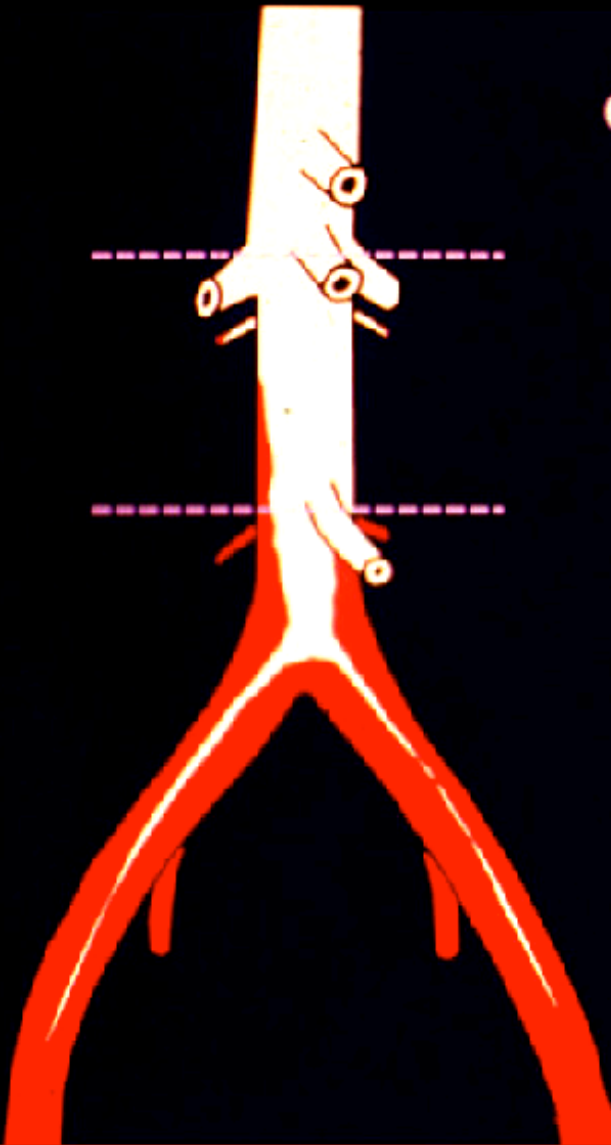
**CO<sub>2</sub> Totally Displaces Blood**

**Renal A.**


**SMA**

**Incomplete Displacement**

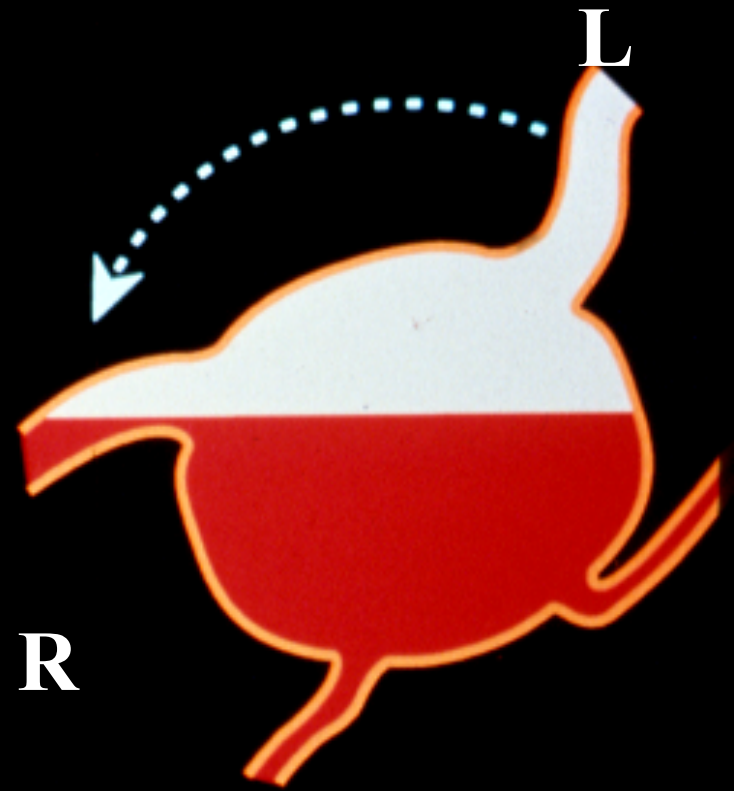
**IMA**



**Lack of total displacement potentiates spurious result**

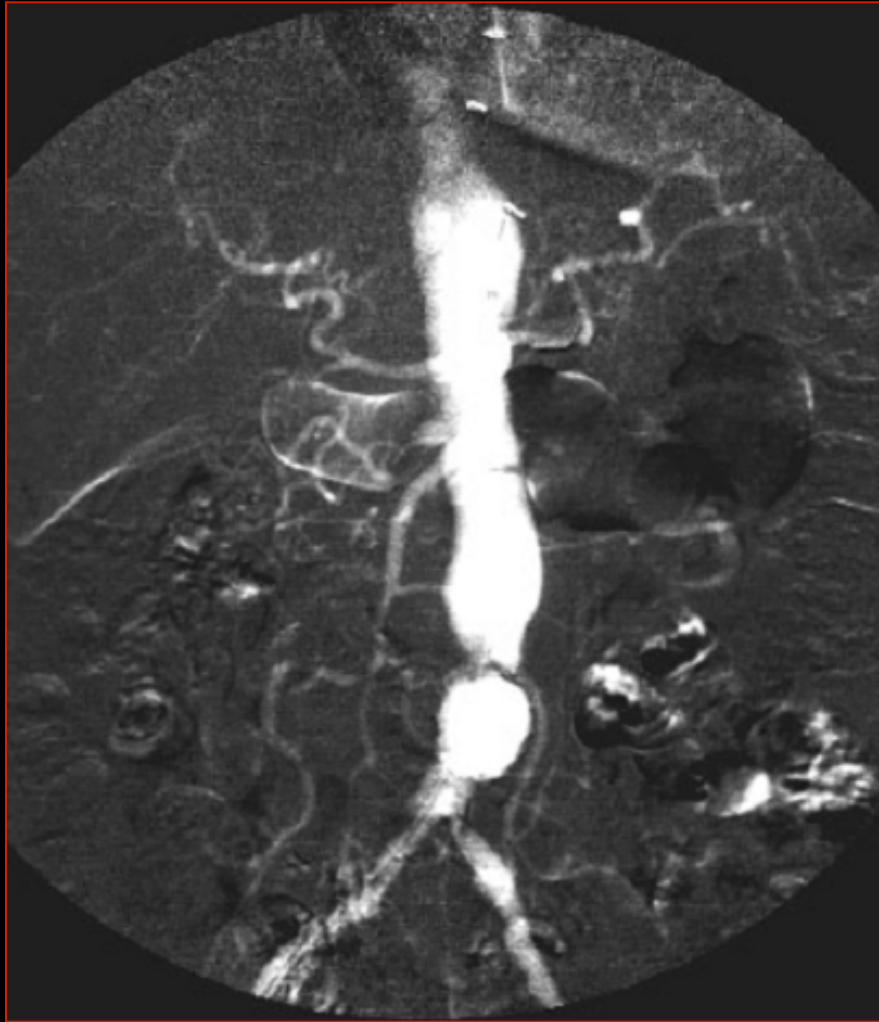

**Supine: L renal  
not visualized**

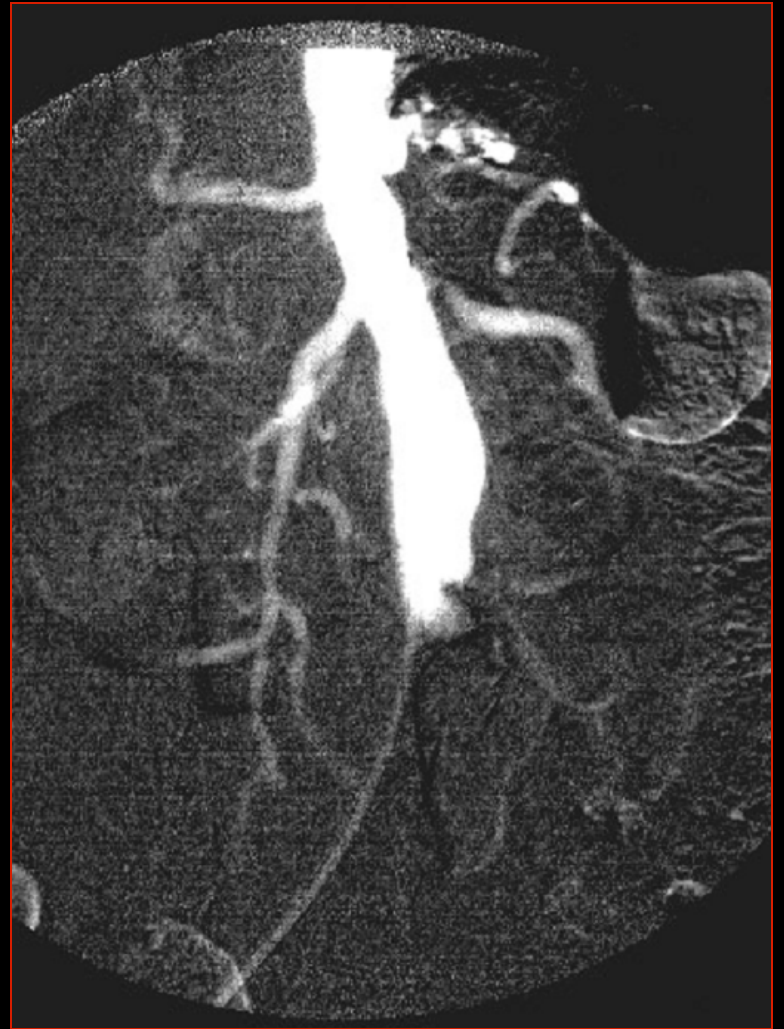

**L side up: L renal  
fills**

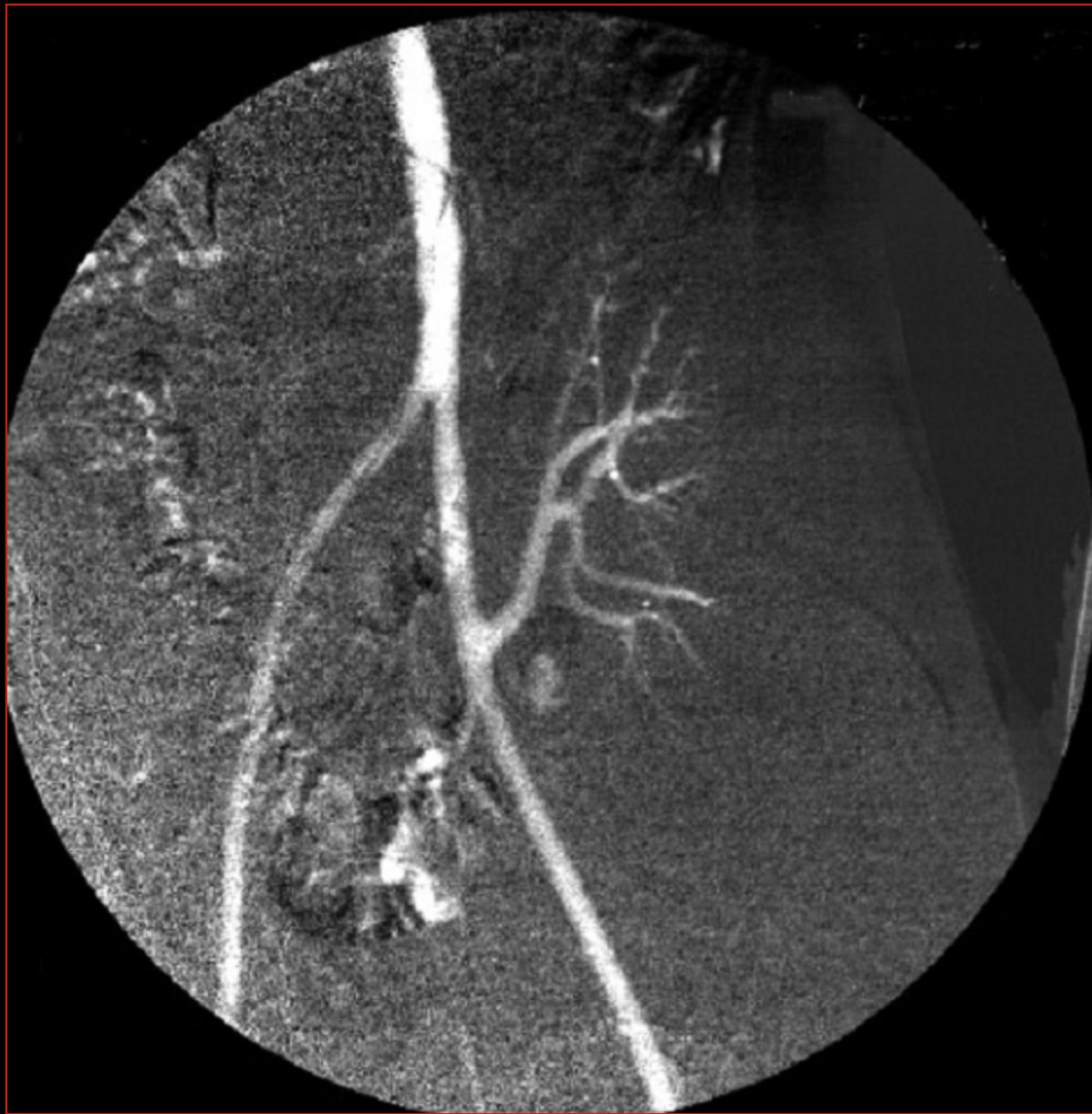
**Advantage: can rotate area of interest to better demonstrate it**



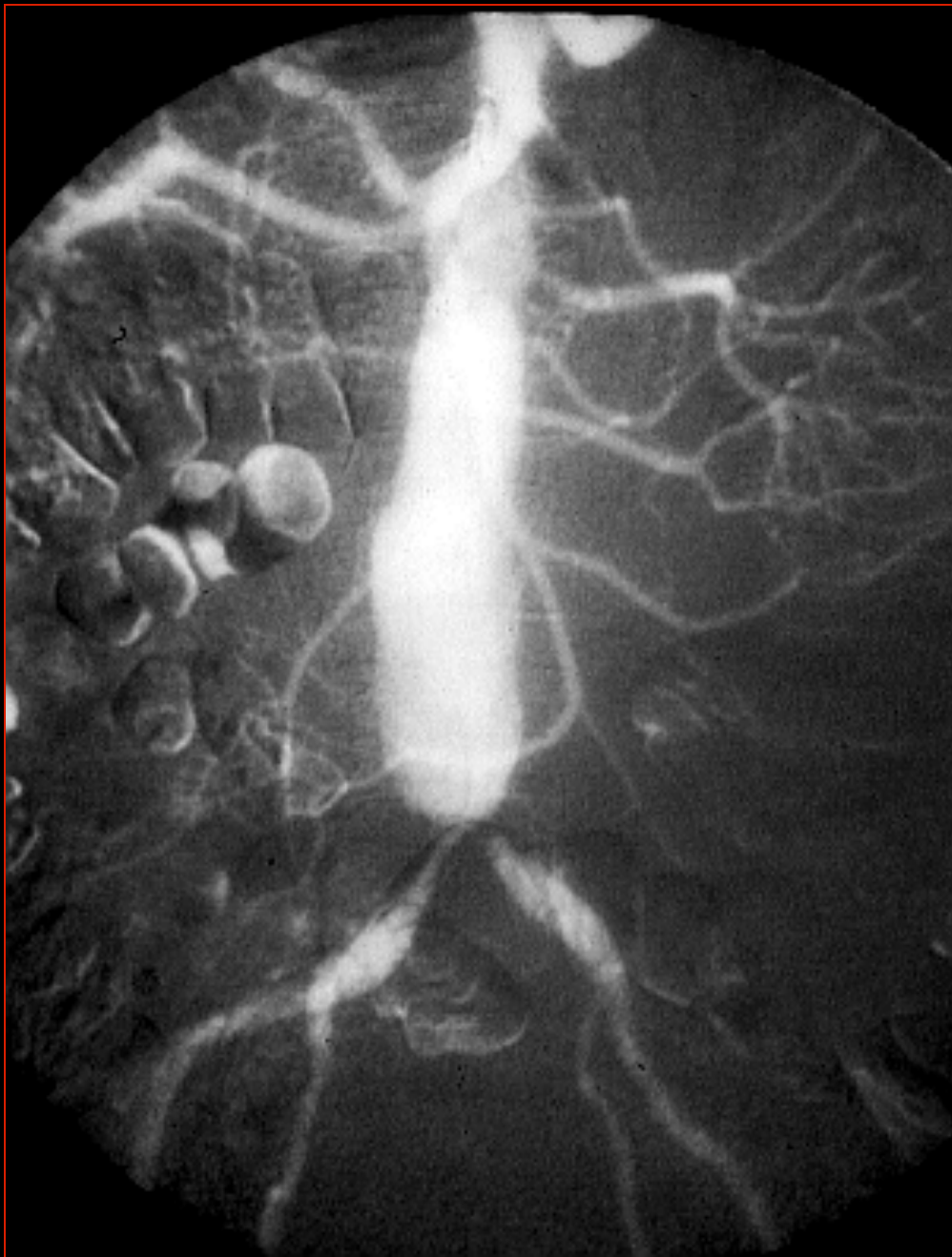**Supine**



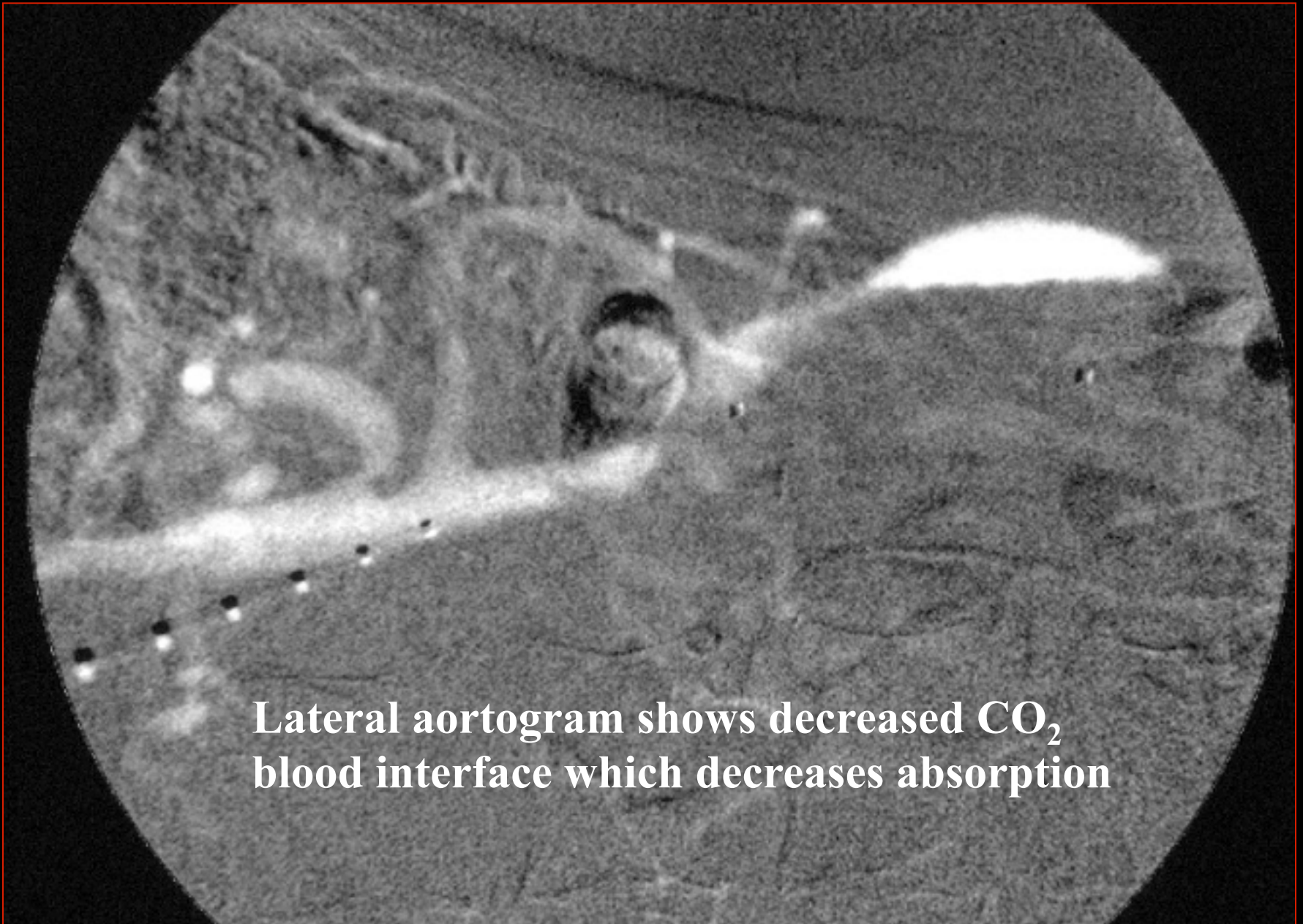
**Left Side Up**



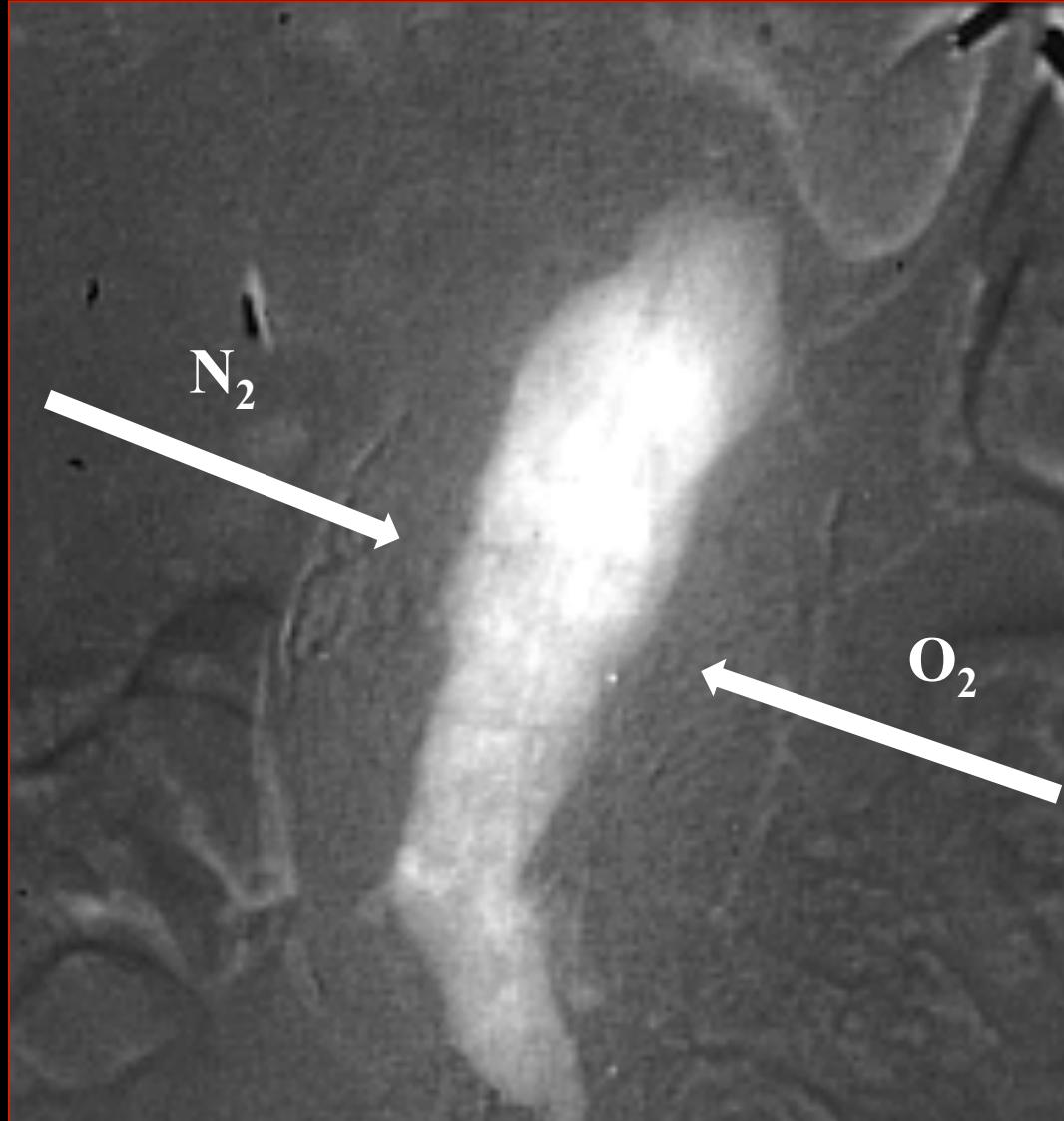
**Renal Tx arteries arise anteriorly and are easier to opacify<sup>21</sup>**



**CO<sub>2</sub> in abdominal aortic aneurysms must be monitored**



**Lateral aortogram shows decreased CO<sub>2</sub> blood interface which decreases absorption**



**If left unabsorbed for a prolonged period more occlusive gases can replace CO<sub>2</sub> over time**

# PHYSICAL PROPERTIES OF CO<sub>2</sub> AND PHYSIOLOGICALLY RELATED GASES


	<b>CO<sub>2</sub></b>	<b>O<sub>2</sub></b>	<b>N<sub>2</sub></b>
<b>Molecular wt</b>	<b>44</b>	<b>32</b>	<b>28</b>
<b>Solubility</b>	<b>0.87</b>	<b>0.03</b>	<b>0.016</b>

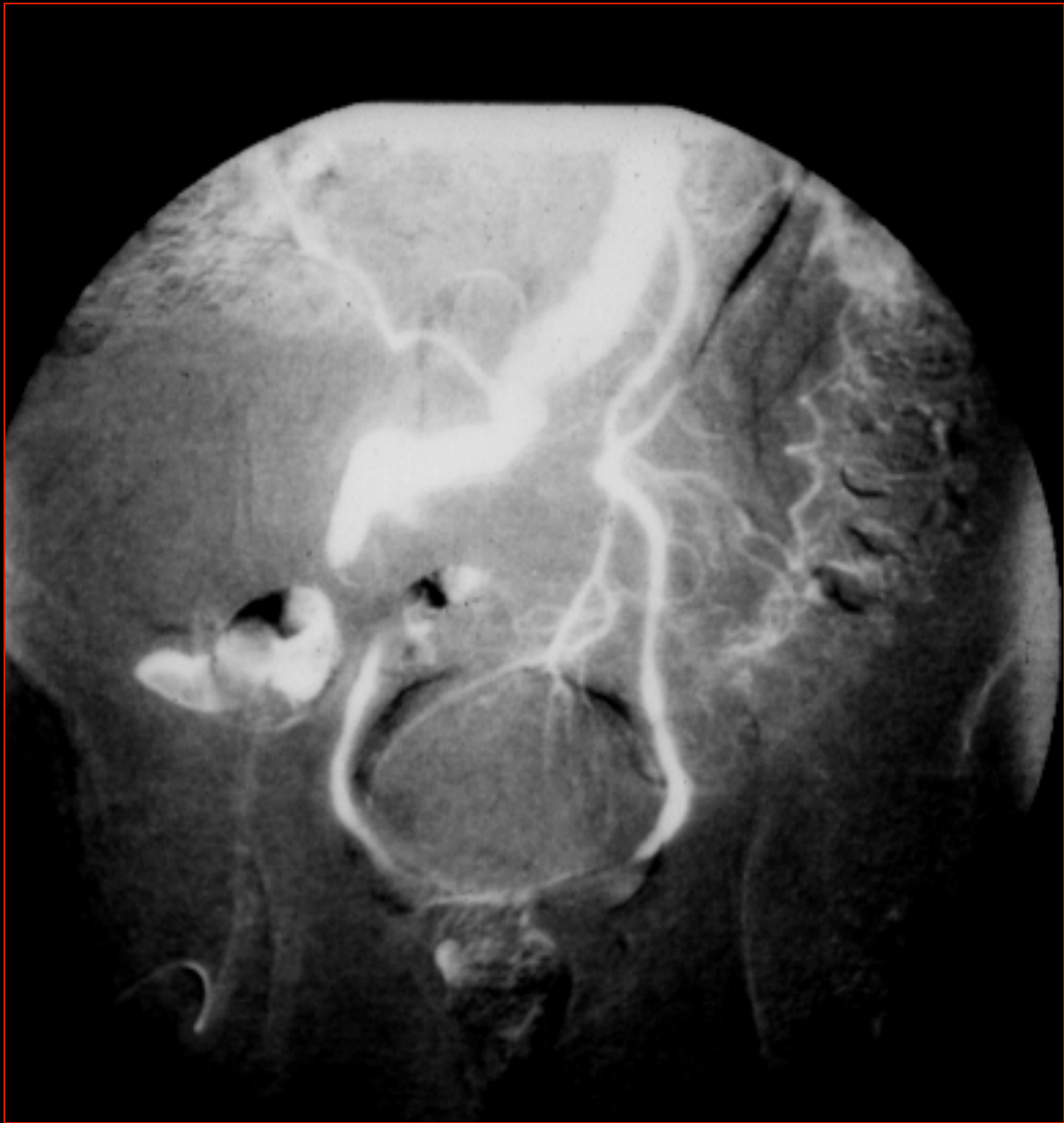Solubility of CO<sub>2</sub> is 29 x that of O<sub>2</sub>

# Very rare but potential “TRAPPING” and ischemia if CO<sub>2</sub> is not absorbed

CO<sub>2</sub> does not mix with blood and pressure can prevent Collateral circulation

Wait for CO<sub>2</sub> to absorb before another injection!





**CO<sub>2</sub> – BUOYANCY**

**+**

**ABERRANT ANATOMY  
OR EXCESSIVE VOLUME**



**POTENTIAL “TRAPPING”**



**POTENTIAL VAPOR LOCK**



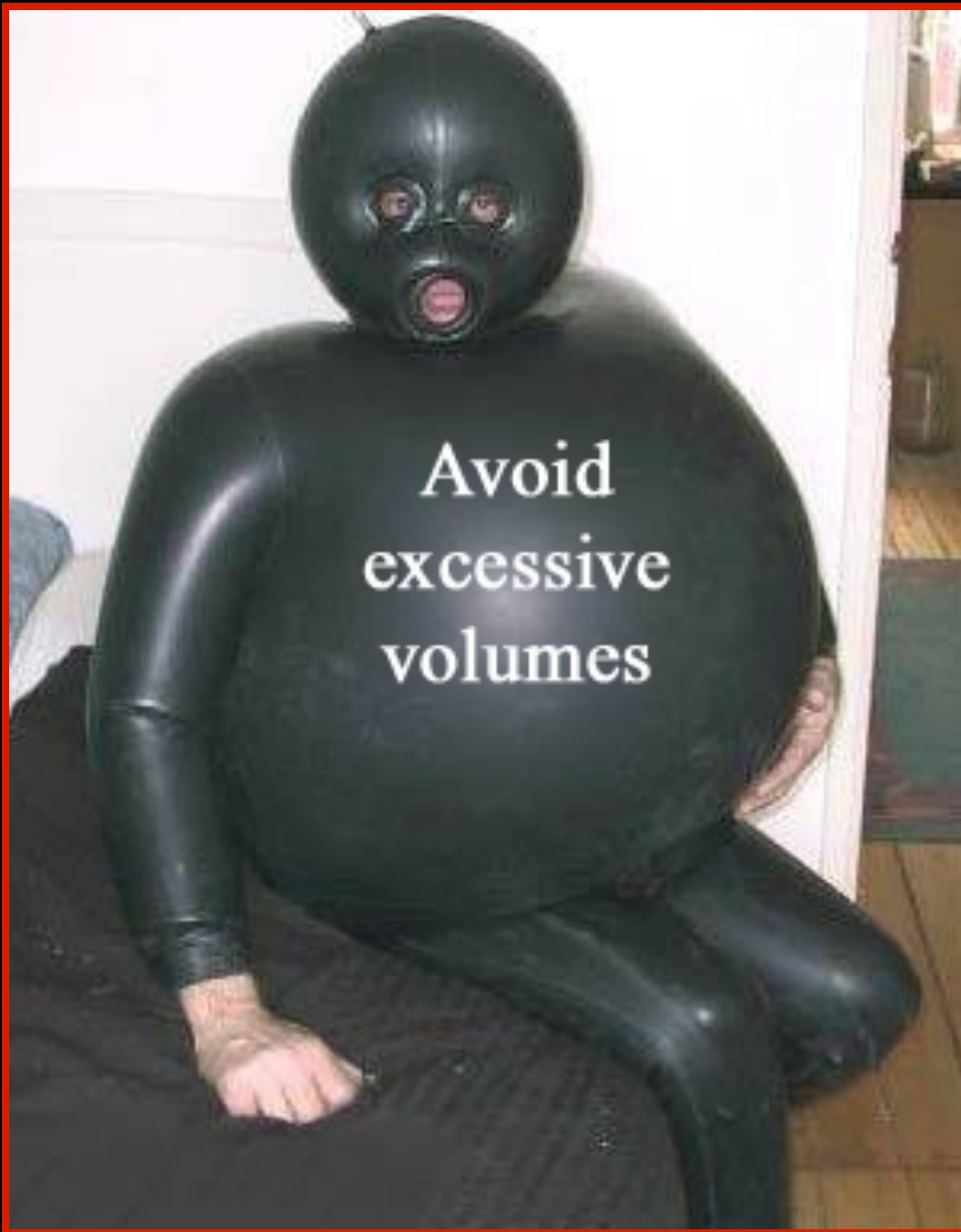**ISCHEMIA**

# PREVENT TRAPPING

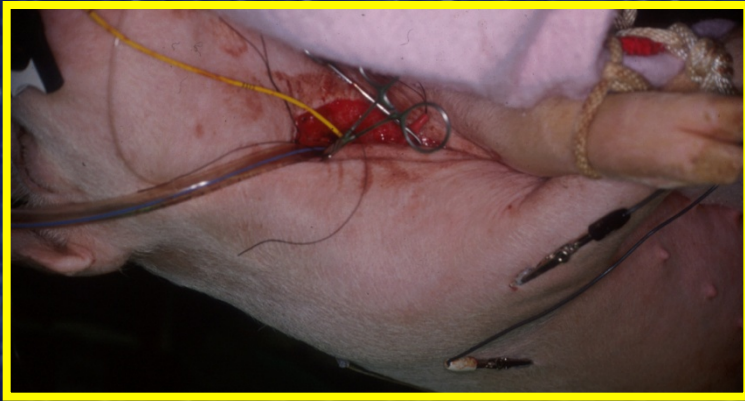
- Prevent excessive volumes
- Monitor with fluoroscopy
- Wait between injections
- Aspirate if necessary



- **\*\* CHANGE THE PATIENT'S POSITION \*\***



# THE HEMODYNAMIC AND VENTILATORY RESPONSES TO INTRACAVAL ADMINISTRATION OF ASCENDING DOSES OF GASEOUS CARBON DIOXIDE: EXPERIMENTAL STUDY IN 20 SWINE – Kyung Cho



- $\text{CO}_2$ : 0.2 -6.4 cc/kg

- Position in supine, LLD, RLD

- Monitoring:

HR,

RR,

BP,

PA,

SaO<sub>2</sub>,

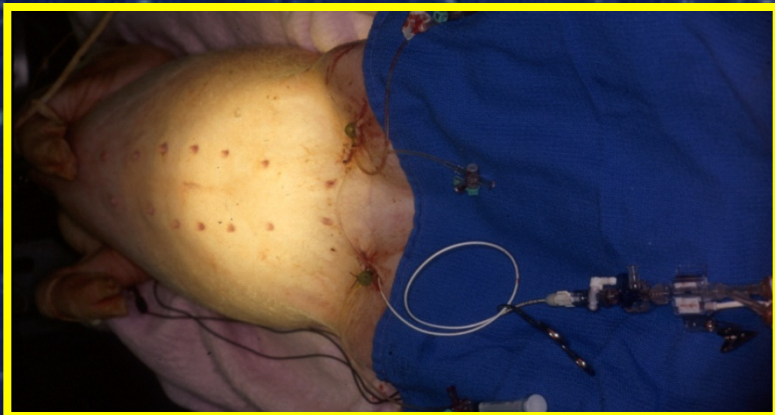
pCO<sub>2</sub>,

pO<sub>2</sub>,

pH,

HCO<sub>2</sub>,

ETCO<sub>2</sub> at 1,3,5, & 10 min post  $\text{CO}_2$



# CONCLUSIONS

- Higher volumes showed various changes in recorded parameters
- CO<sub>2</sub> in doses of 0.2-1.6 cc/kg (112 cc in 70Kg) caused no cardiopulmonary effects.
- Intravenous diagnostic CO<sub>2</sub> DSA may increase PA pressure, CO<sub>2</sub> should be used cautiously in patients with pulmonary hypertension.
- Giving appropriate doses and allowing absorption there is no total limit of CO<sub>2</sub>

# PREVENT EXCESSIVE VOLUMES

- **Excessive Volume :**
  - 1 large bolus exceeding recommendations
  - multiple small injections without delay
- **NEVER connect directly to a CO<sub>2</sub> cylinder!!!!!!!!!!**
- **Deliver known volumes - non-compressed system**
- **Wait 1-2 min. between injections**
- **Limit volumes to < 100 cc' s / injection**
- **Use stacking software**

# COMPRESSIBLE

- **EXPLOSIVE DELIVERY**

**Pain, N&V**

**Reflux - potential trapping, neurotoxicity**


- **INDETERMINATE VOLUMES**

**Compressed gas can lead to false volumes**

**Can lead to accidental excessive volumes**

# PREVENT EXPLOSIVE DELIVERY

- Use a non-compressed closed system
- Purged to atmospheric pressure
- Purge catheter of saline or blood before definitive injection



# OTHER POTENTIAL CONCERNS

- **NEUROTOXICITY**
- **NITROUS OXIDE ANESTHESIA**
- **COPD**
- **Pulmonary HTN**

# **INTRACEREBRAL EXPOSURE**

- **No definitive proof of neuro toxicity  
however prudent to:**
- **Avoid direct or reflux exposure**
- **Avoid arterial injections above the  
diaphragm or upper extremity (reflux)**

# COPD

- **CO<sub>2</sub> endogenous production 250 cc/min**
- **No problem unless in respiratory failure**
- **Precaution: decrease volume and increase interval between delivery**

# **NITROUS OXIDE ANESTHESIA**

- **$N_2$  can diffuse from soft tissue to  $CO_2$  bubble**
- **$CO_2$  bubble becomes 5-6 X more occlusive**
- **Avoid nitrous oxide anesthesia with  $CO_2$  procedure like TIPS**

# PULMONARY HTN

- **Avoid high volume venous procedures if patient has know pulmonary HTN**
- **Potential PFO**

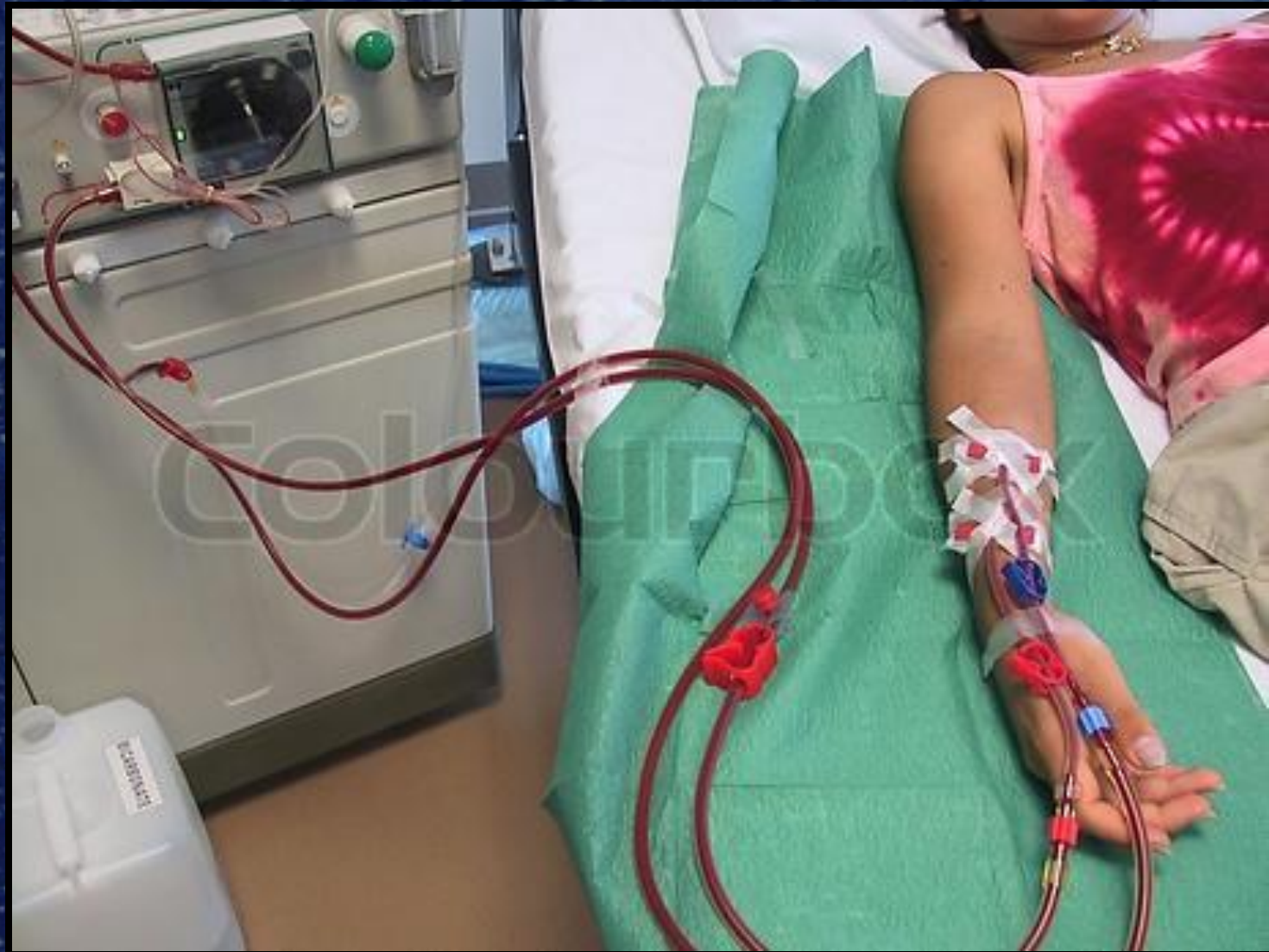# CONTRAINDICATIONS

- **Supra-diaphragmatic **arterial** injections (intracranial CO<sub>2</sub>)**
- **Use with nitrous oxide anesthesia**
- **Known left to right shunts**

# INDICATIONS

- **Iodinated contrast allergy**
- **Renal insufficiency**
- **High volume contrast procedures**
- **Detection of arterial bleeding**
- **Intervention**

# NON-NEPHROTOXIC



# **DEFINITION OF CIN**

## **(contrast induced nephropathy)**

- **Rise in serum Cr  $>$  .5 mg/dl**
- **Rise of serum Cr  $>$  25% baseline**

# CIN

- **2<sup>nd</sup> or 3<sup>rd</sup> most common cause of hospital acquired acute renal failure (behind shock and nephrotoxic drugs)**
- **The overall incidence of CIN is 7%**
- **Risk of CIN requiring dialysis is**
  - **4% with renal insufficiency**
  - **3% when undergoing percutaneous coronary intervention**

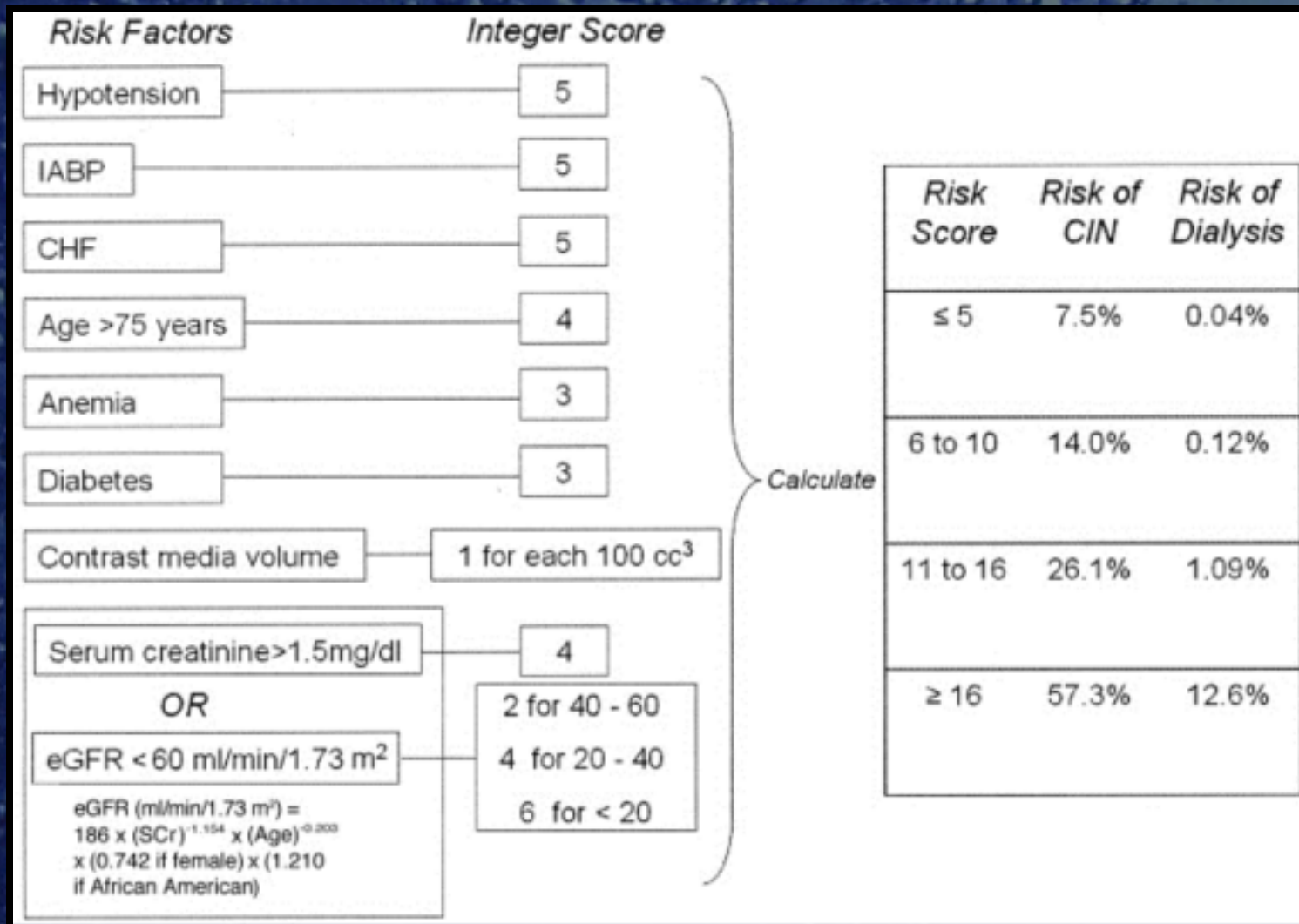
# **CLASSIC CONTRAST INDUCED NEPHROPATHY RISKS:**

- **Diabetic nephropathy**
- **Myeloma**
- **Large volume contrast**
- **Intravascular volume depletion**

# OTHER RISK FACTORS

- Hypotension (SBP < 80 mmHg)
- Heart Failure (NYHA III/IV)
- Use of intra-aortic balloon pump (IABP)
- Preexisting renal dysfunction SC > 1.5 mg/dl OR CrCI < 60 ml/min
- Age ≥ 75 years
- Diabetes
- Hematocrit < 39% for men, or < 36% for women
- Dehydration
- Concomitant use of nephrotoxic drugs and/or renal perfusion reducing agents  
ACEI's, Aminoglycosides, Vancomycin, Diuretics, NSAID's, etc

# CIN RISK FACTORS



Scheme to define contrast-induced nephropathy (CIN) risk score. Anemia = baseline hematocrit value <39% for men and <36% for women; CHF = congestive heart failure class III/IV by New York Heart Association classification and/or history of pulmonary edema; eGFR = estimated glomerular filtration rate; hypotension = systolic blood pressure <80 mm Hg for at least 1 h requiring inotropic support with medications or intra-aortic balloon pump (IABP) within 24 h periprocedurally.

# HOSPITAL ACQUIRED CIN

**Risk of death (34%) ↑ 6 x**

**Hospitalization ↑ 2 x**

**1 and 2 year mortality ↑ 2 x**

**Increase comorbid complications**

# HOSPITAL ACQUIRED CIN

**7500 Patients**

**In hospital mortality (22% vs 1.4%)**

**1 and 5 year mortality 4 x**

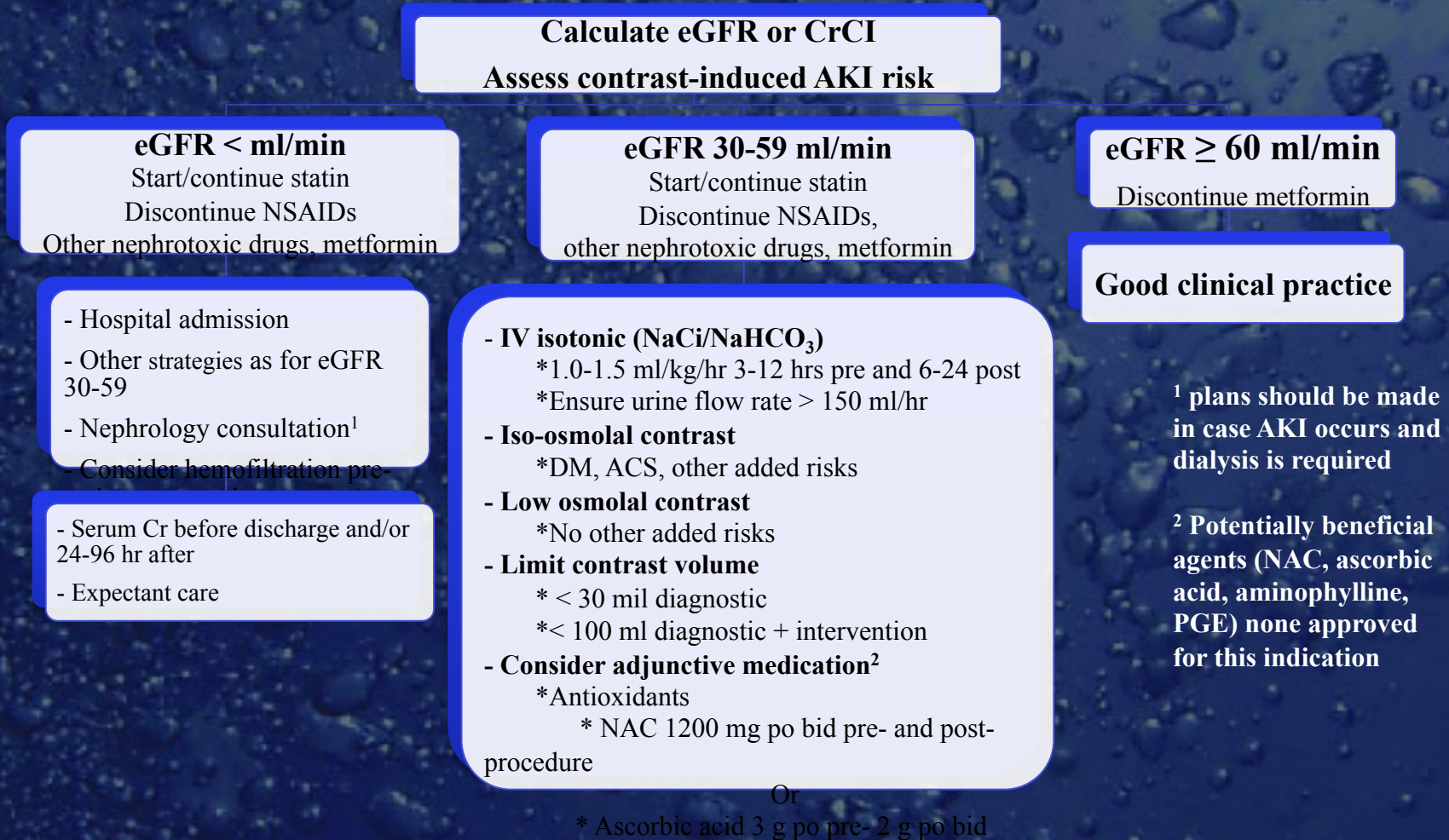
# CIN

- **Vascular interventional procedures are increasing**
- **Diabetes is increasing**
- **Patient population is aging**
- **CLI and Claudication 45% had RAS, 16% severe, 12% bilateral**
- **Creatinine clearance subnormal in > 80% of PAOD patients**
- **Serum Cr is inaccurate in 30% 40-49 yo and 90% > 70 yo**
- **30% of Cr Clearance abnormal for > 70 yo**

# CIN

- **Average increased cost of CIN without dialysis**
- **\$10,345 in hospital and \$11,812 1<sup>st</sup> year**

# ALGORITHM TO AVOID CIN



**Figure Legend: Advanced Algorithm for Management of Patients Receiving Iodinated Contrast Media.** ACS = acute coronary syndromes; bid = twice daily; Cr = creatinine; DM = diabetes mellitus; IV = intravenous; NAC = N-acetylcysteine; NSAIDs = nonsteroidal anti-inflammatory drugs; PGE<sub>1</sub> = prostaglandin E<sub>1</sub>; po = by mouth; other abbreviations as in Figure 2.

# CIN VARIABLES

- 1. Underlying clinical state (renal insufficiency)**
- 2. Site of administration of contrast**
- 3. Volume of contrast!!!!**

**REDUCE OR PREVENT CIN**

**LIMIT THE VOLUME OF  
CONTRAST!!!!!!!**

# DELIVERY

# Plastic Bag Delivery System

Hawkins, Caridi, and Kerns. AJR 165: 1995:1487-1489

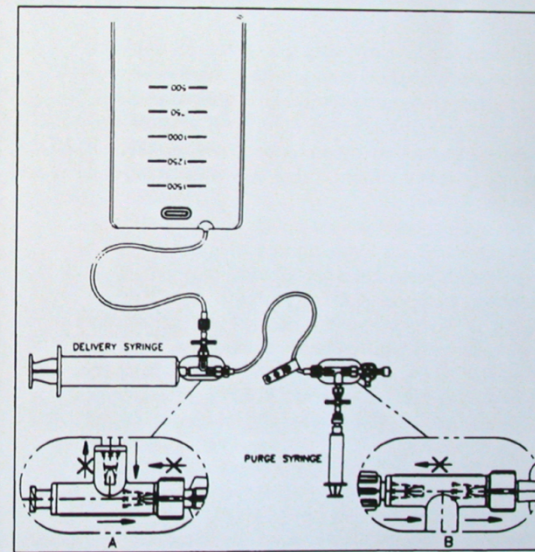
## Plastic Bag Delivery System for Hand Injection of Carbon Dioxide

Irvin F. Hawkins, Jr.<sup>1</sup>, James G. Caridi, Scott R. Kerns

Digital subtraction angiography with carbon dioxide as a contrast agent provides images useful in making a diagnosis and occasionally gives information not obtainable with use of iodinated contrast material. However, delivery of the gas is difficult because carbon dioxide is compressible and invisible [1, 2]. Over the past 10 years, we have developed a reliable, user-friendly, computer-controlled injector, which is not yet approved by the Food and Drug Administration. We describe a hand-delivery system designed on the basis of principles learned from the development of the computer-controlled injector system.

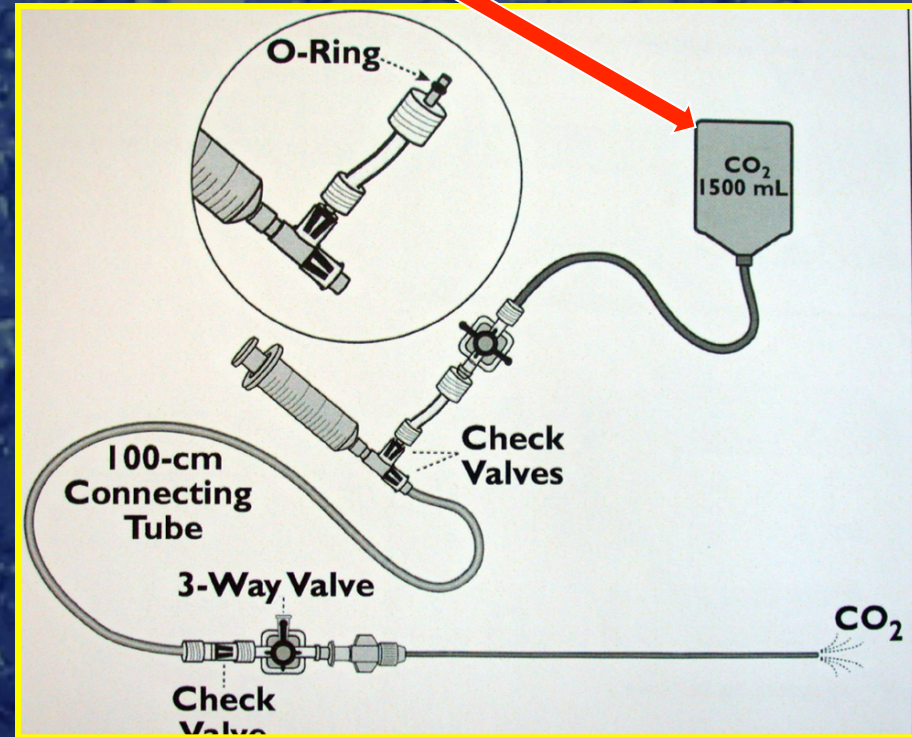
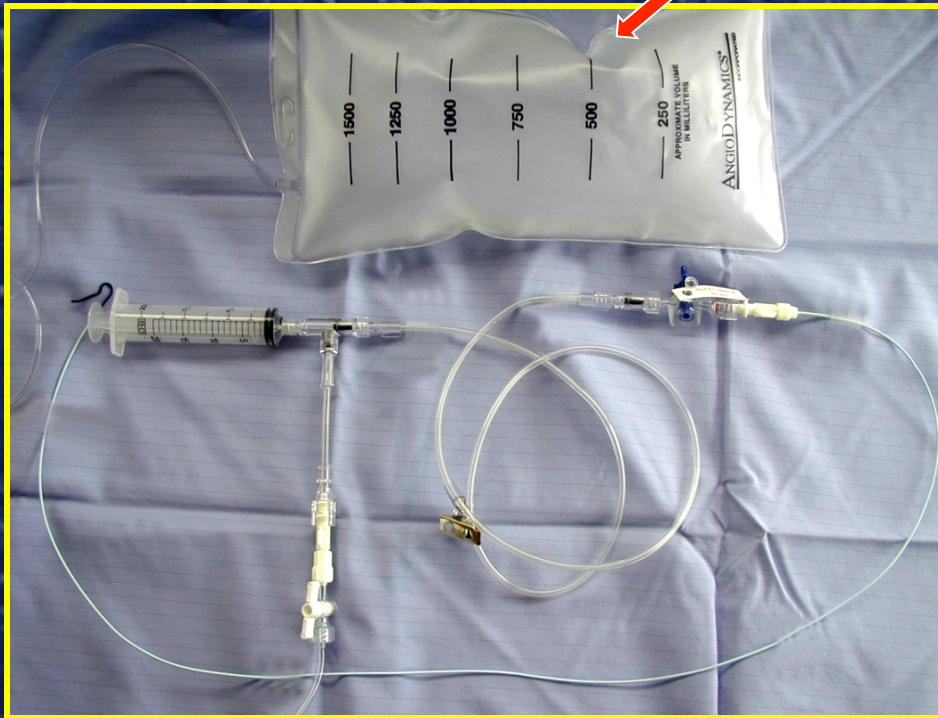
### Materials and Methods

The system has two major components (Fig. 1): a plastic bag (AngioFill Bag Collection System; AngioDynamics, Queensbury, NY) that is used as a reservoir for the carbon dioxide and a closed fluid (or gas) delivery system (AngioFlush II, AngioDynamics) consisting of multiple check valves, stopcocks, and a connecting tube. In order to remove residual air from the connecting tubing and the bag, a special female-to-female adaptor is connected to the one-way stopcock. After air is removed from the bag, the stopcock is

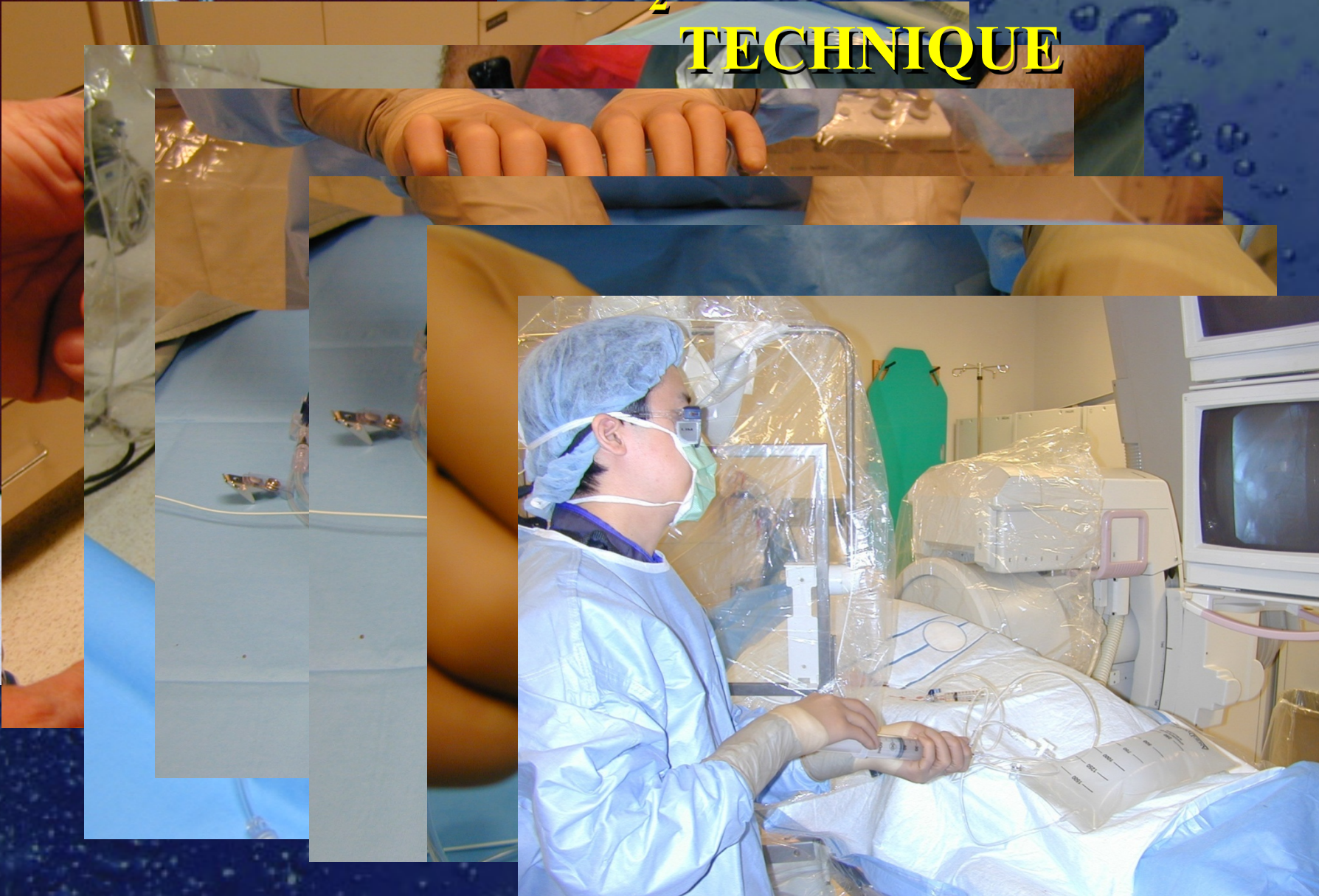

**AngioFill Bag Collection System and Angioflush 11.  
AngioDynamics**

# FLACCID CO<sub>2</sub> RECEPTACLE



# CO<sub>2</sub> ANGIOGRAPHY TECHNIQUE




# MERIT MEDICAL CUSTOM WASTE BAG AND CONTRAST DELIVERY SET



**Flaccid reservoir**

**One way valves**

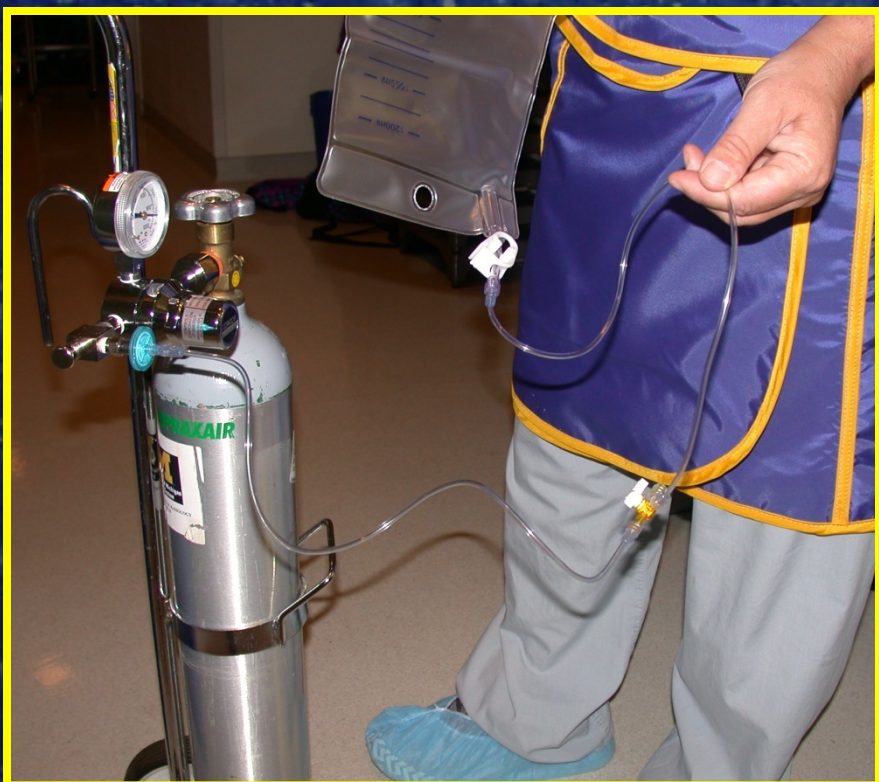

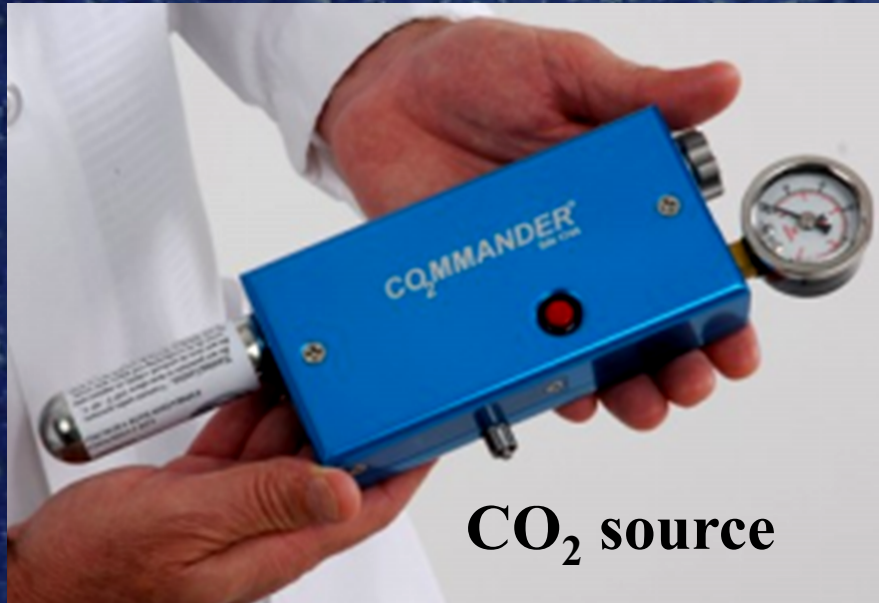**Clamp**

**Catheter**

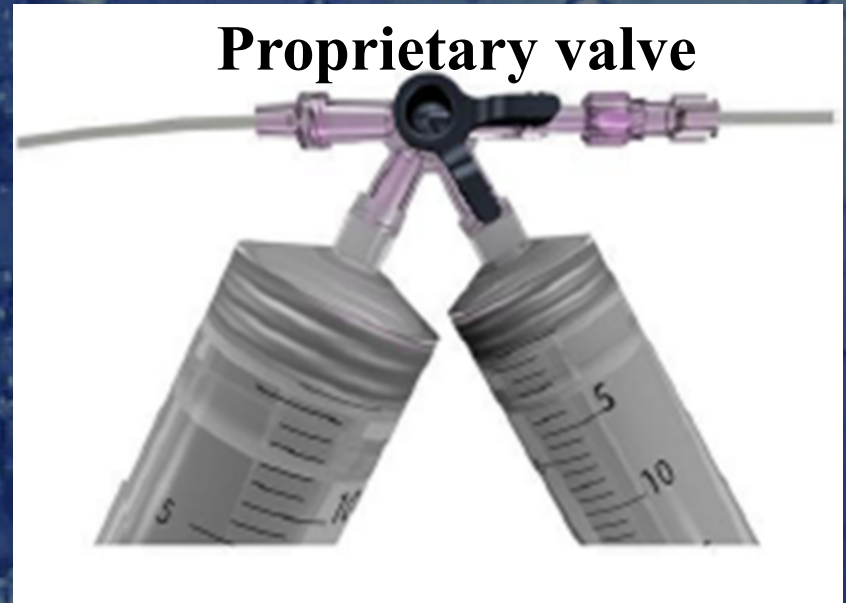**Delivery syringe**

# MERITMEDICAL CUSTOM WASTE BAG AND CONTRAST DELIVERY SET



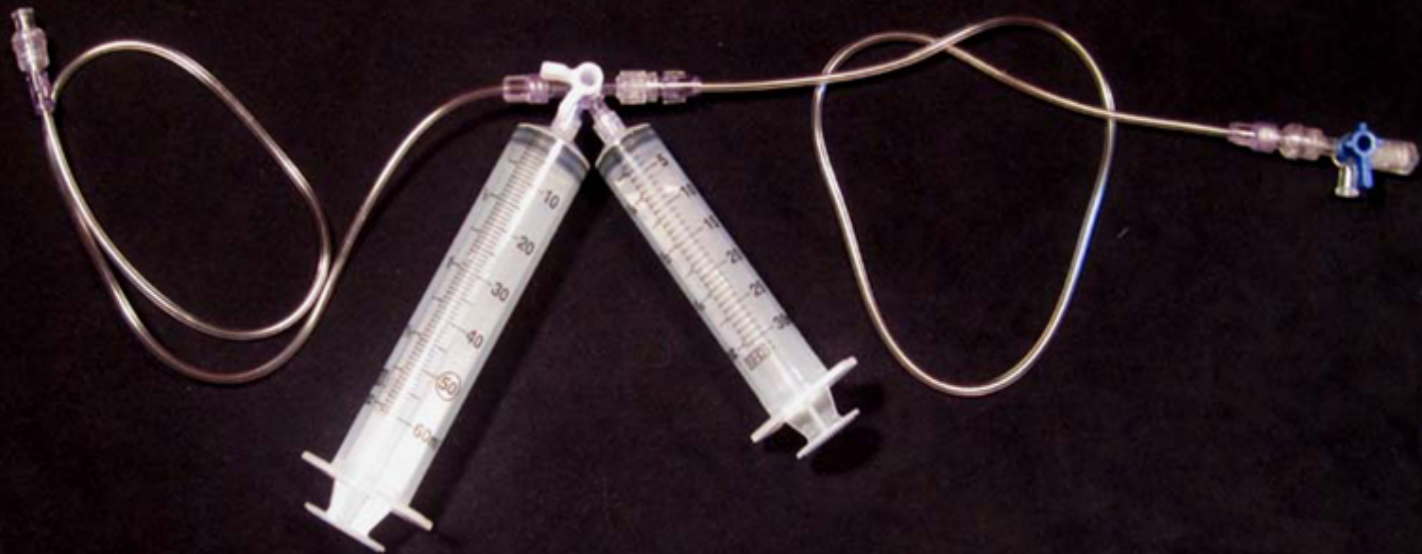

**CO<sub>2</sub> source**



**Proprietary valve**

**Pre-assembled delivery system with one way valves**





**CO<sub>2</sub>MMANDER® II**

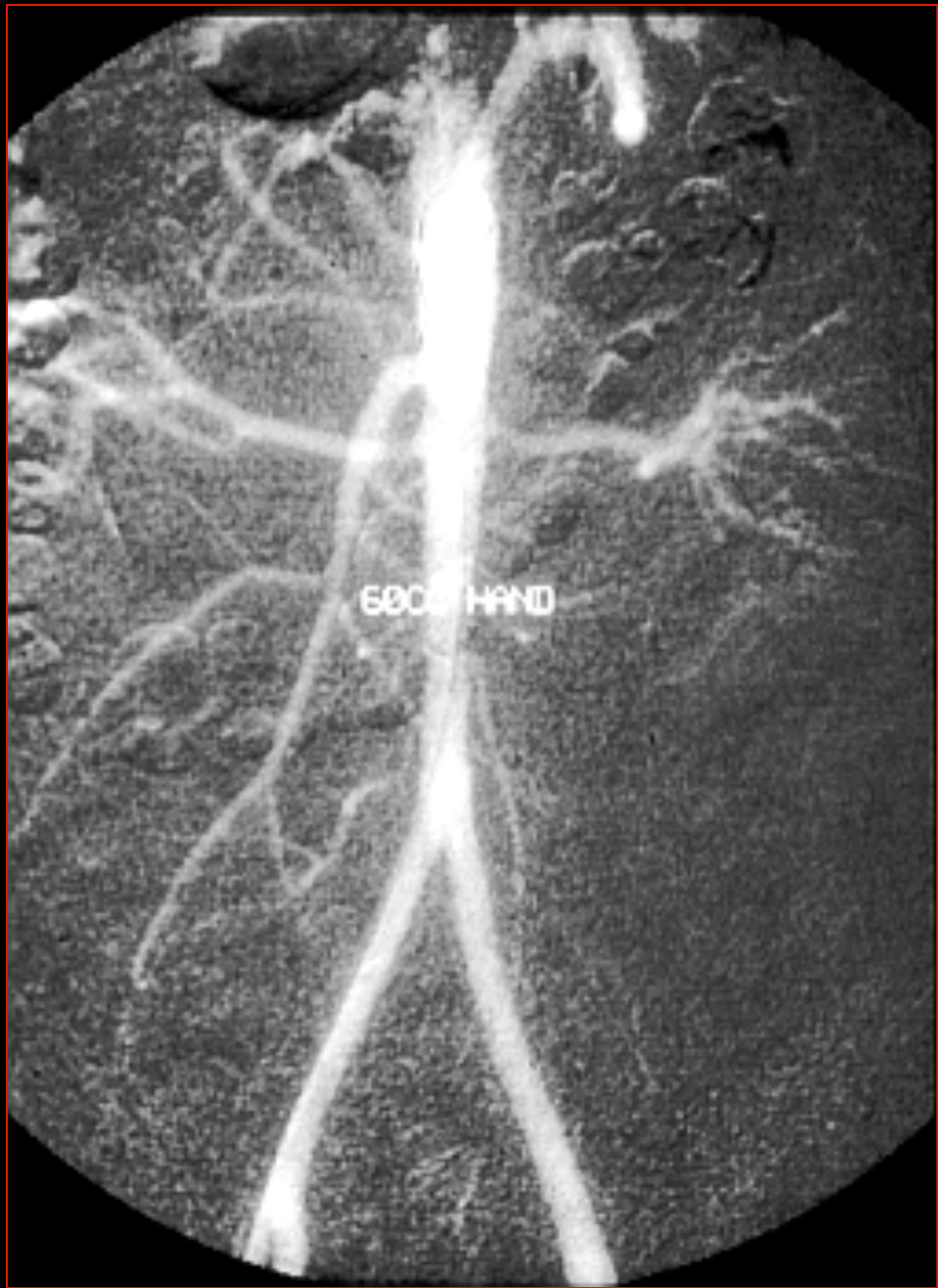
S/N 4001

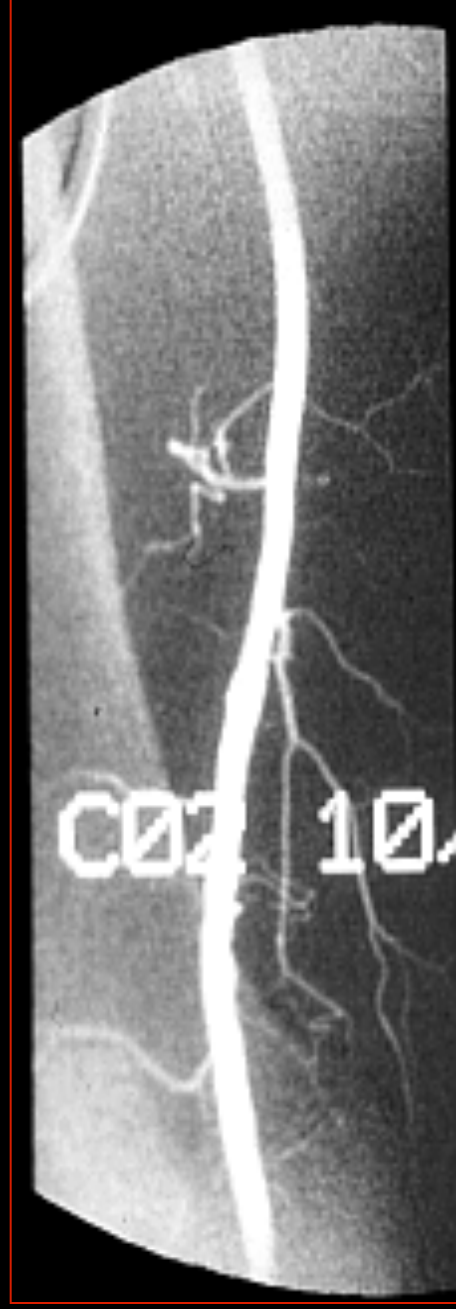
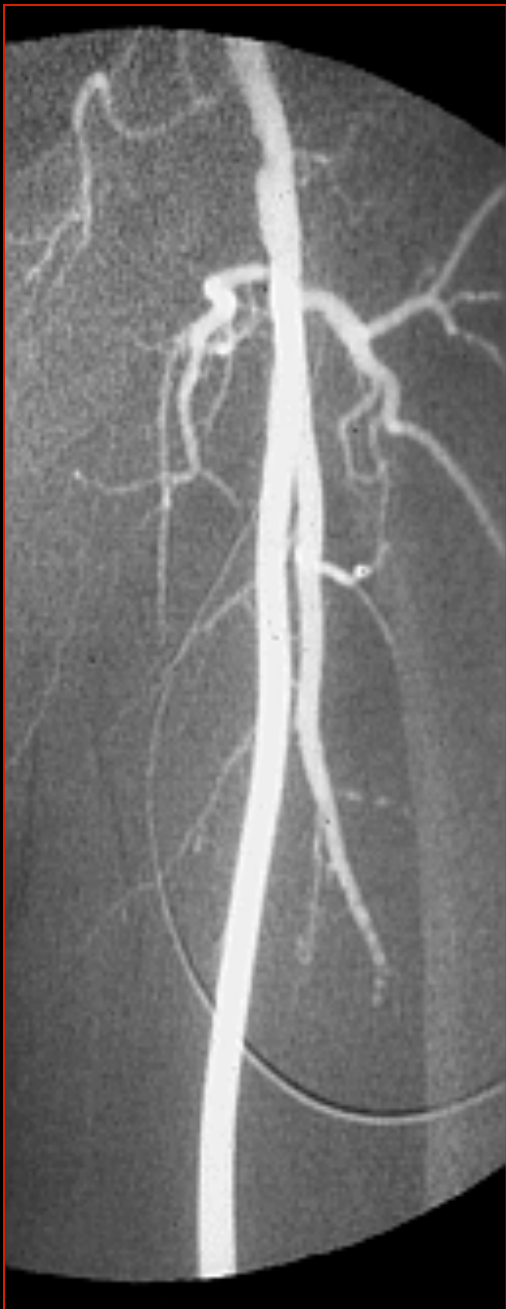

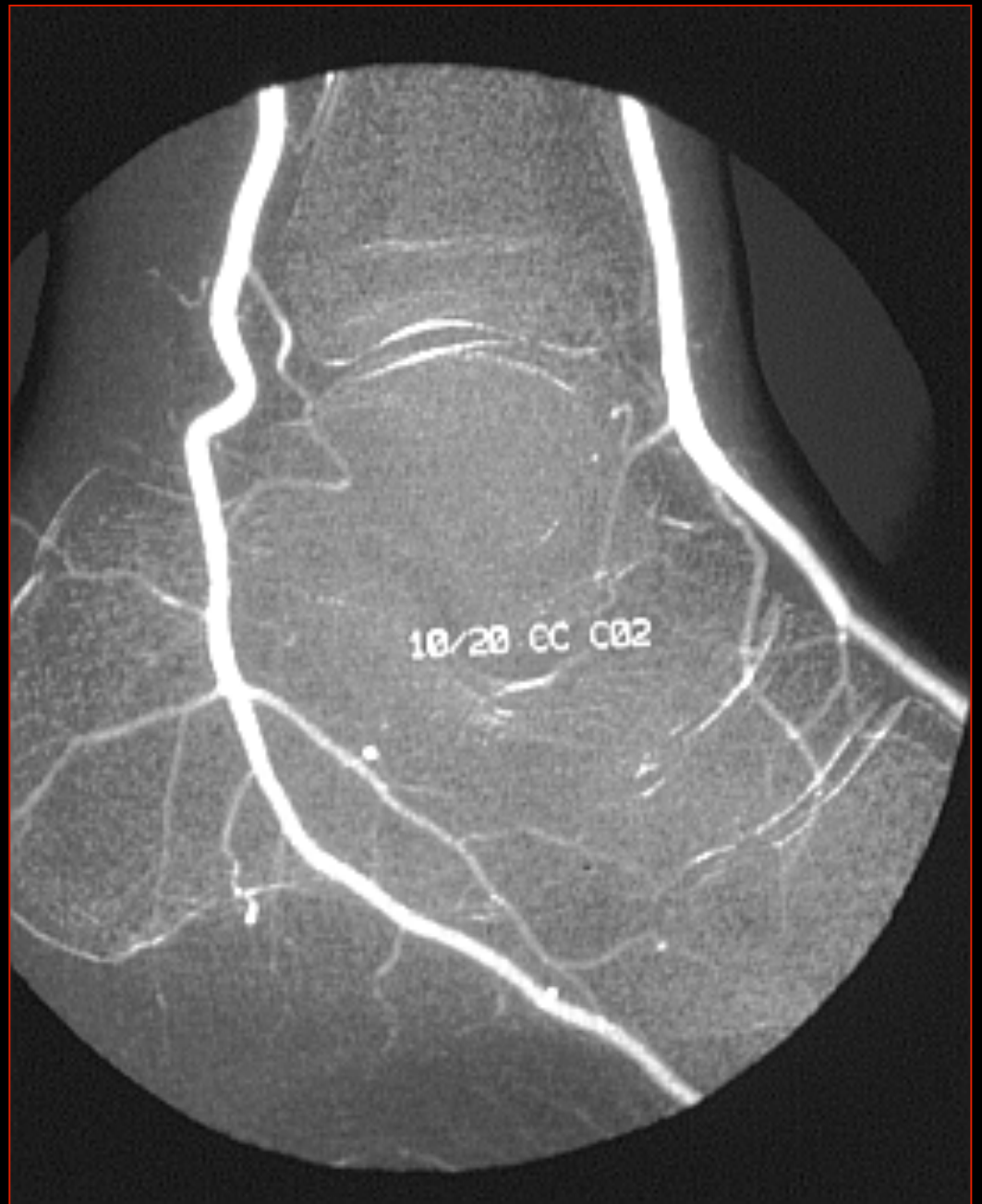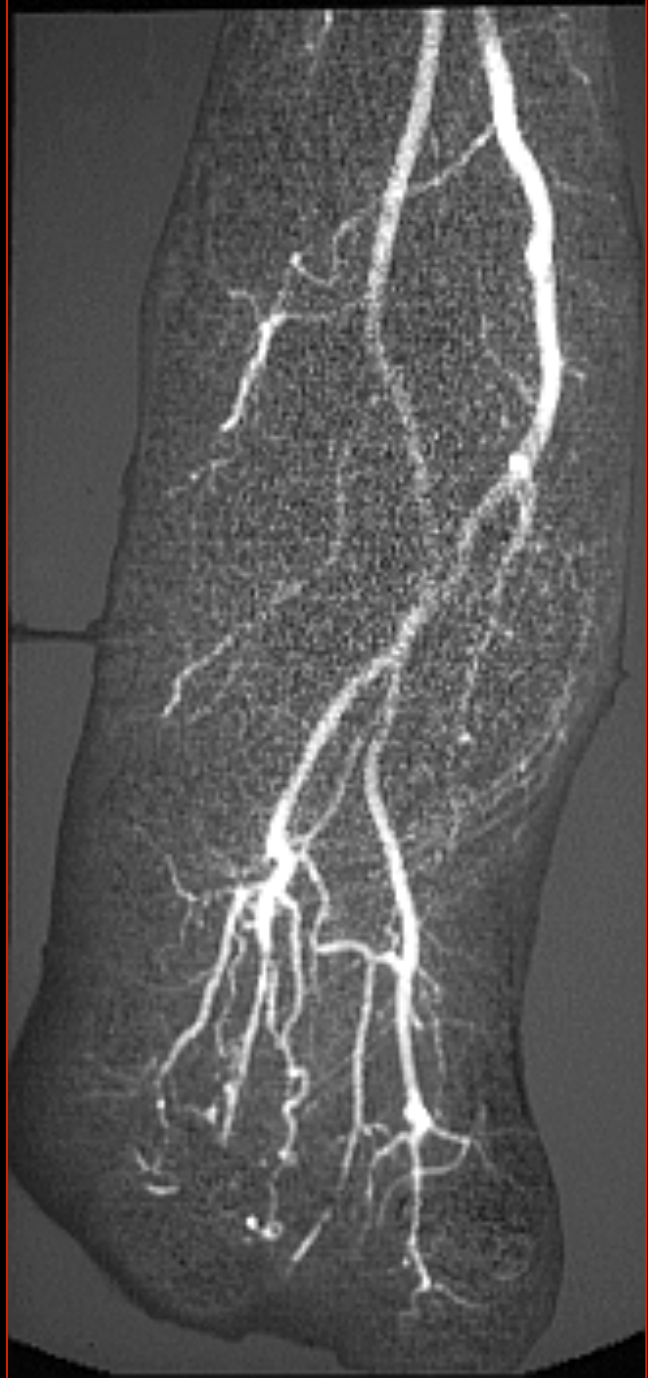# DELIVERY SYSTEM

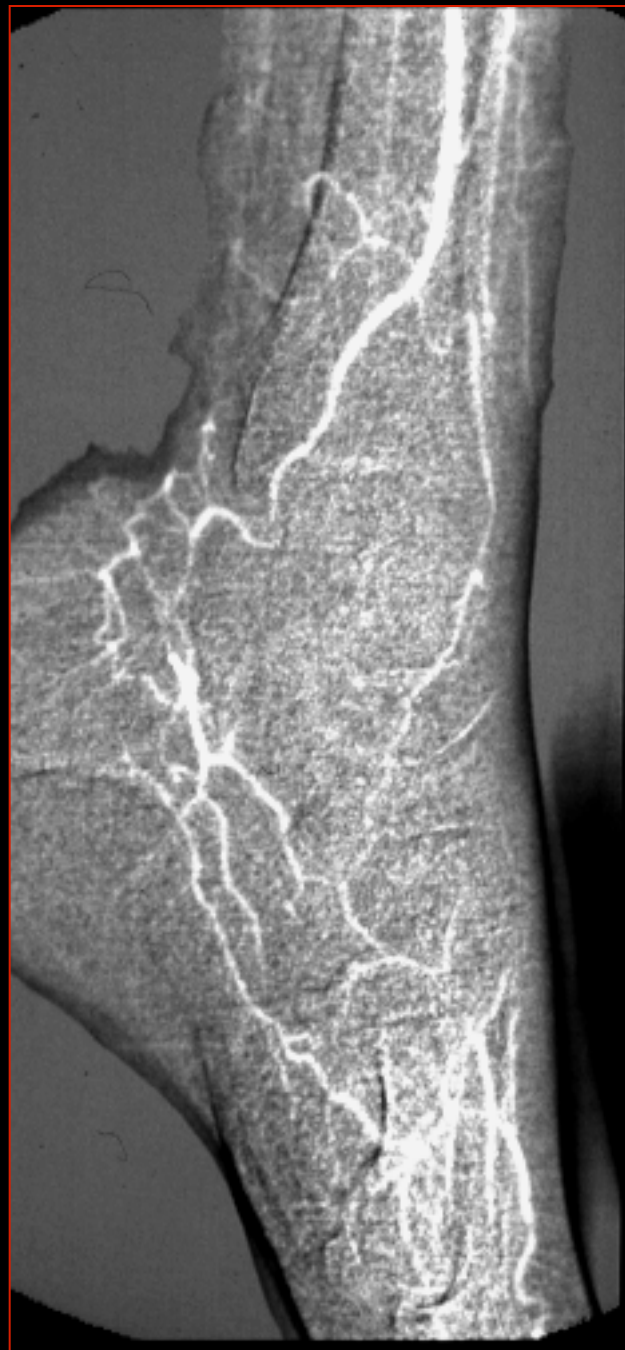
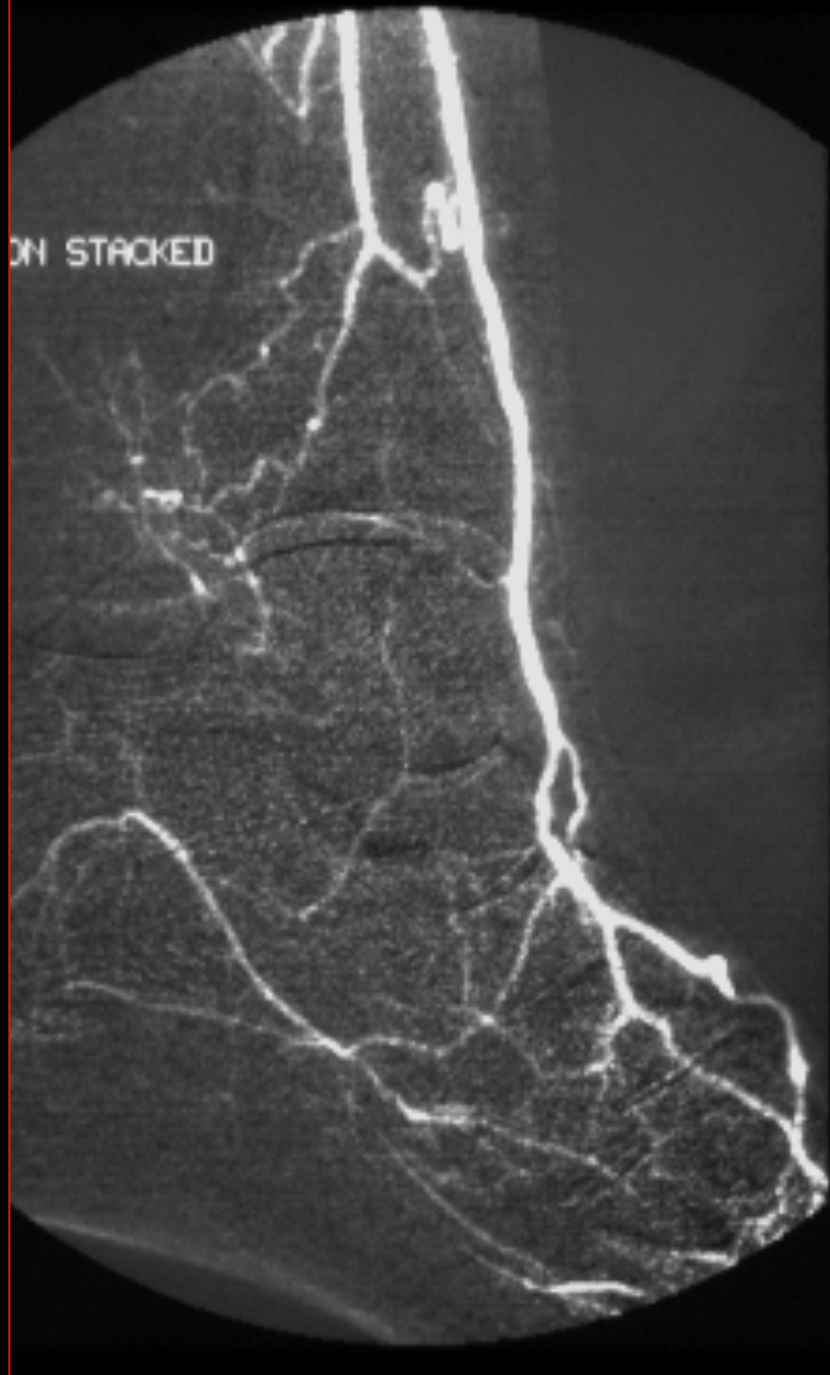
- **Non-compressed** - for accurate volume and prevent explosive delivery
- **Closed system** – to prevent contamination
- **One way valves** - prevent reflux and necessity to remove delivery syringe
- **Glued components** - helps prevent air contamination
- **Hand injection** - purge catheter first to prevent explosive delivery

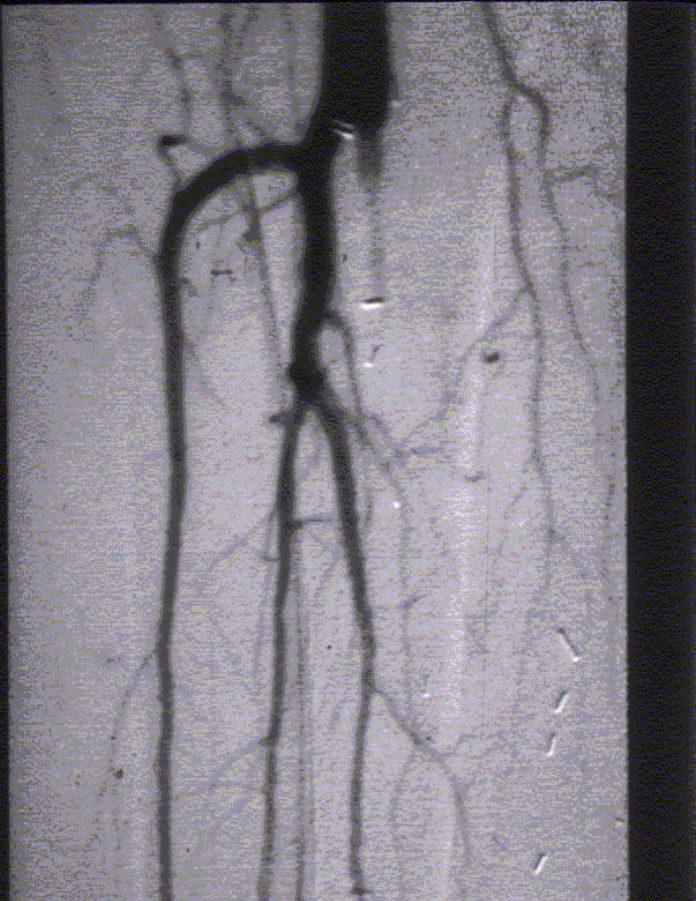# ARTERIAL DIAGNOSIS



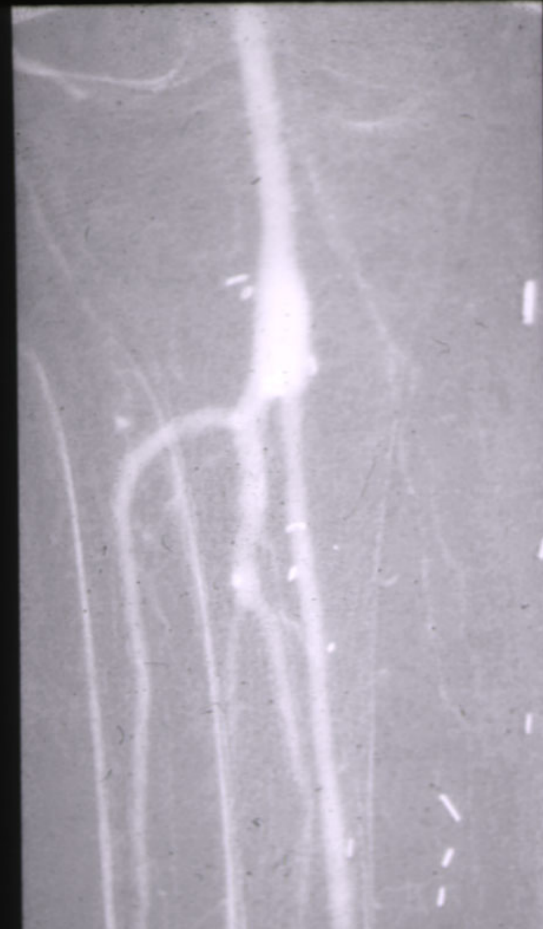







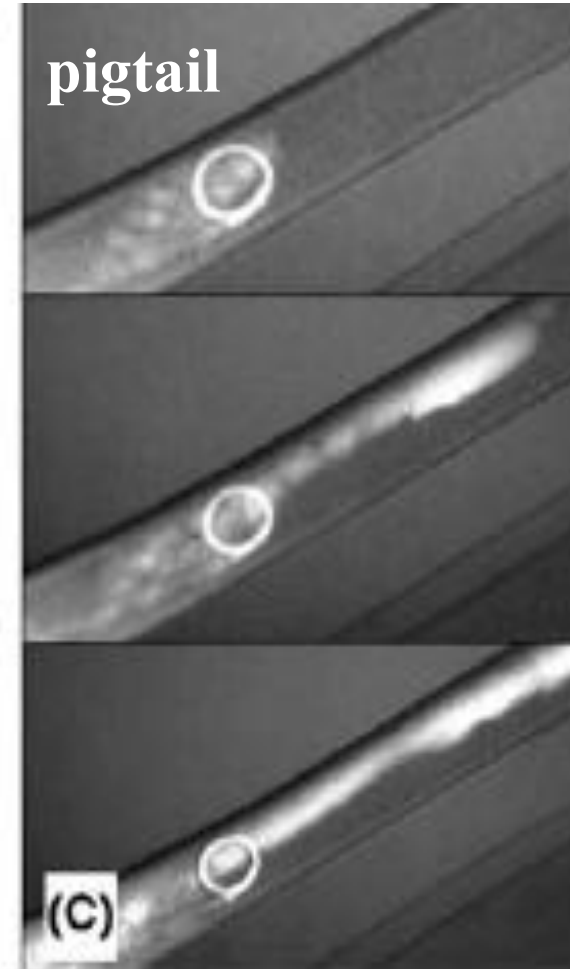
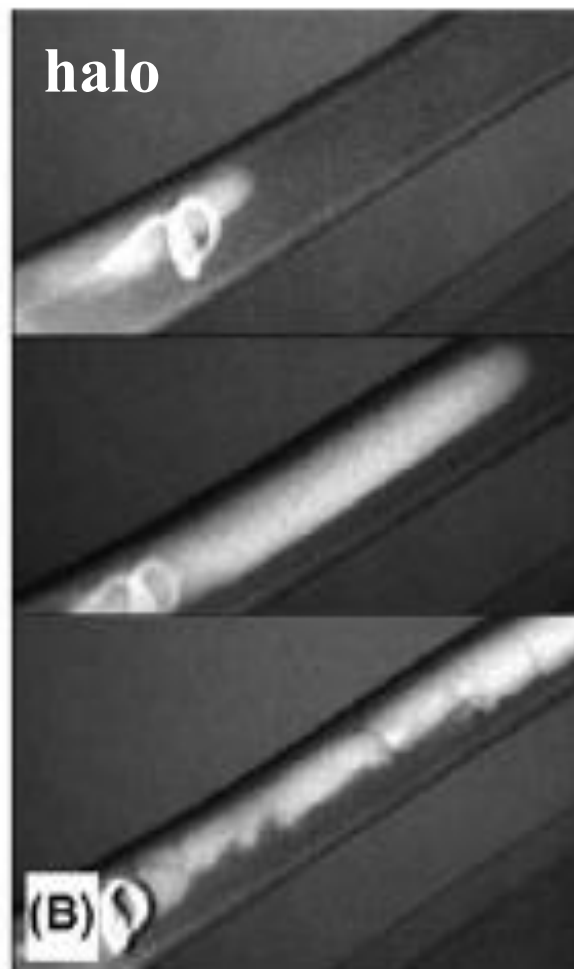

**Thicker contrast spuriously suggests distal graft is occluded. CO<sub>2</sub> demonstrates patency**



# TIPS FOR IMPROVING (RUNOFF) IMAGING

- Reduce motion
- Gentle non explosive delivery
- Faster exposure (6 frames/sec)
- Increase pulse width (60 ms)
- Endhole catheter
- Increase CO<sub>2</sub> volume
- (super) Selective injections
- Elevate the extremity or area of interest
- Reflux CO<sub>2</sub>
- Vasodilator (NTG 100 mcg)
- Stacking software

# CO<sub>2</sub> DISPERSION PATTERNS FORM WITH DIFFERENT CATHETERS



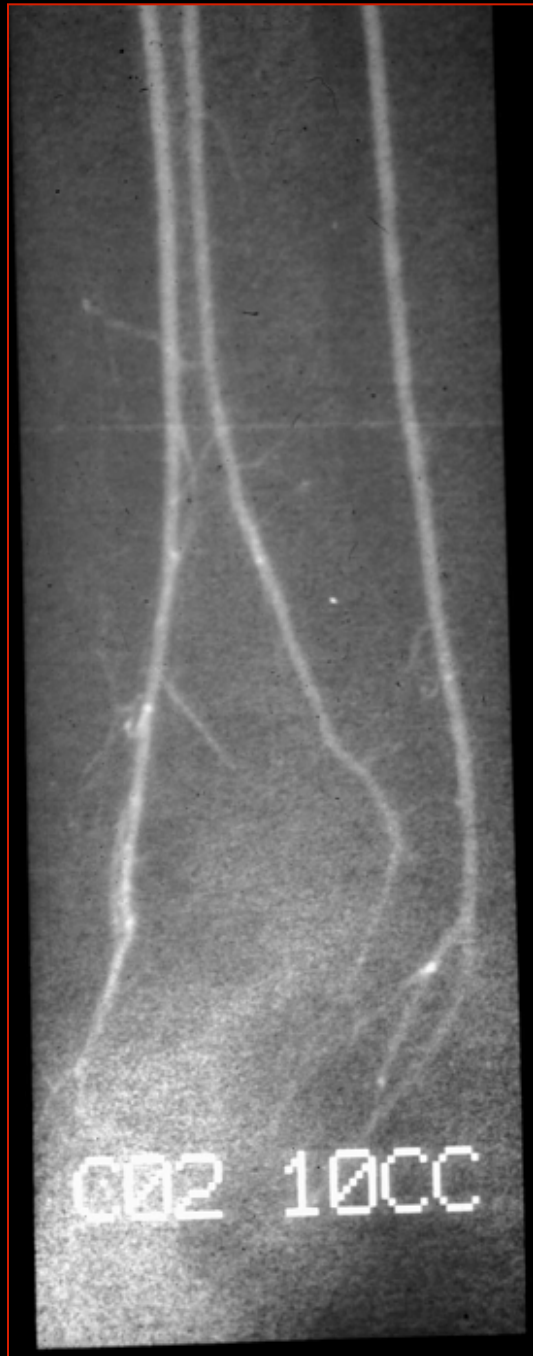
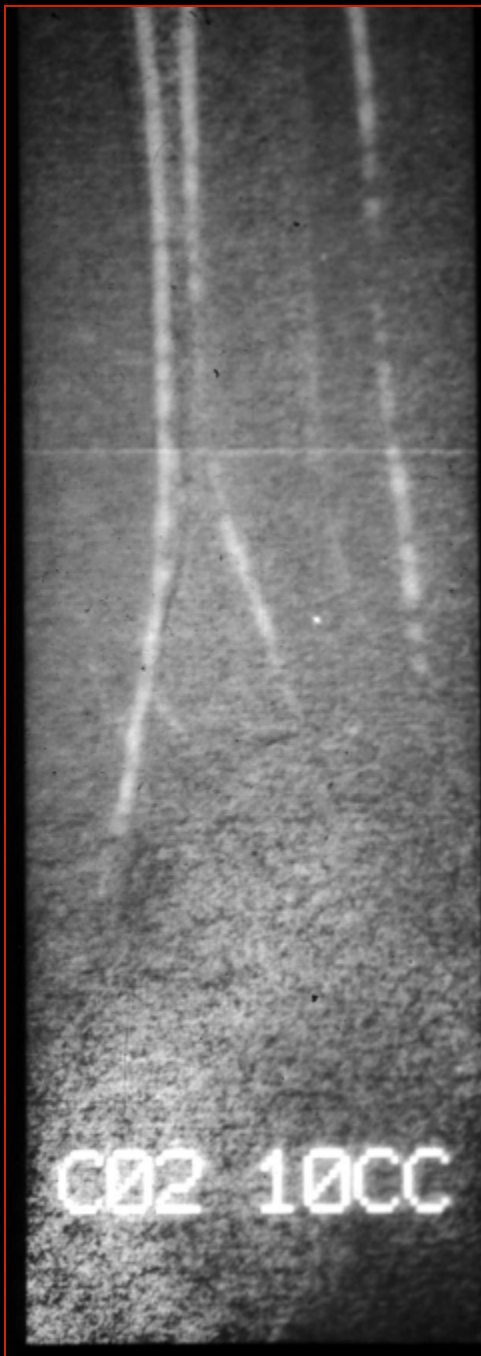
**End hole catheter is best for  
CO<sub>2</sub> providing better bolus  
and less “bubbling”**

# STACKING SOFTWARE

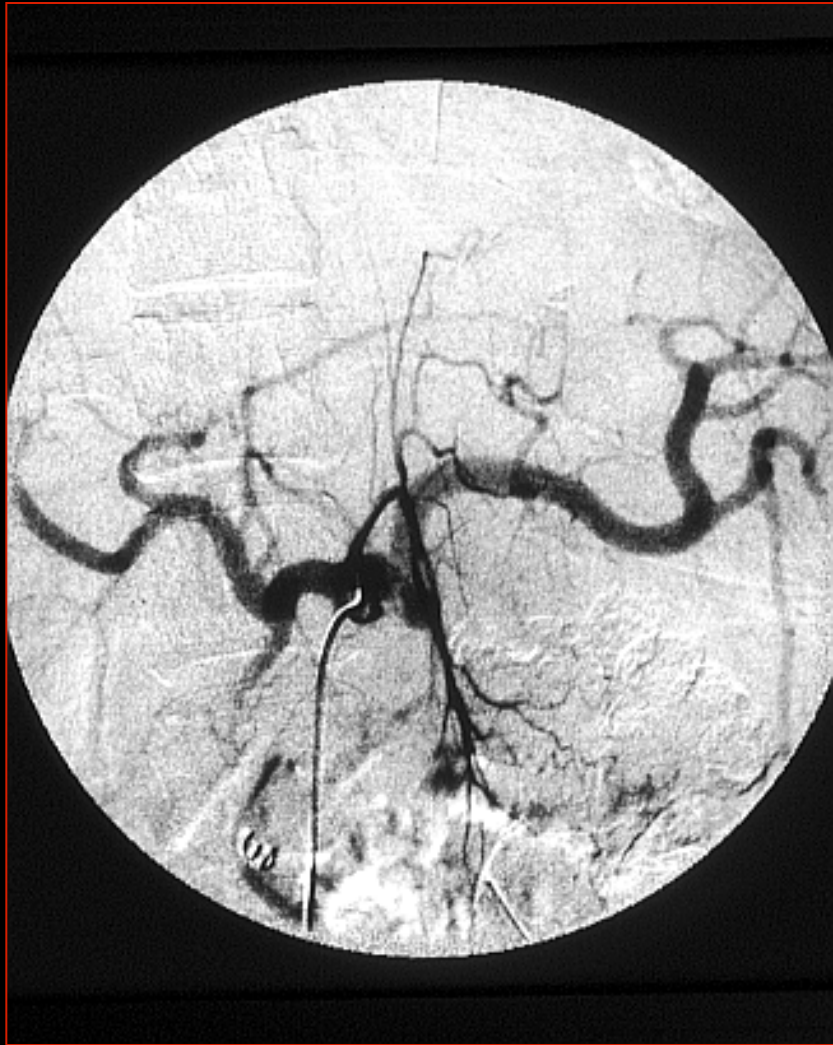
**Superimposes multiple frames to  
yield a composite image**

# STACKING SOFTWARE

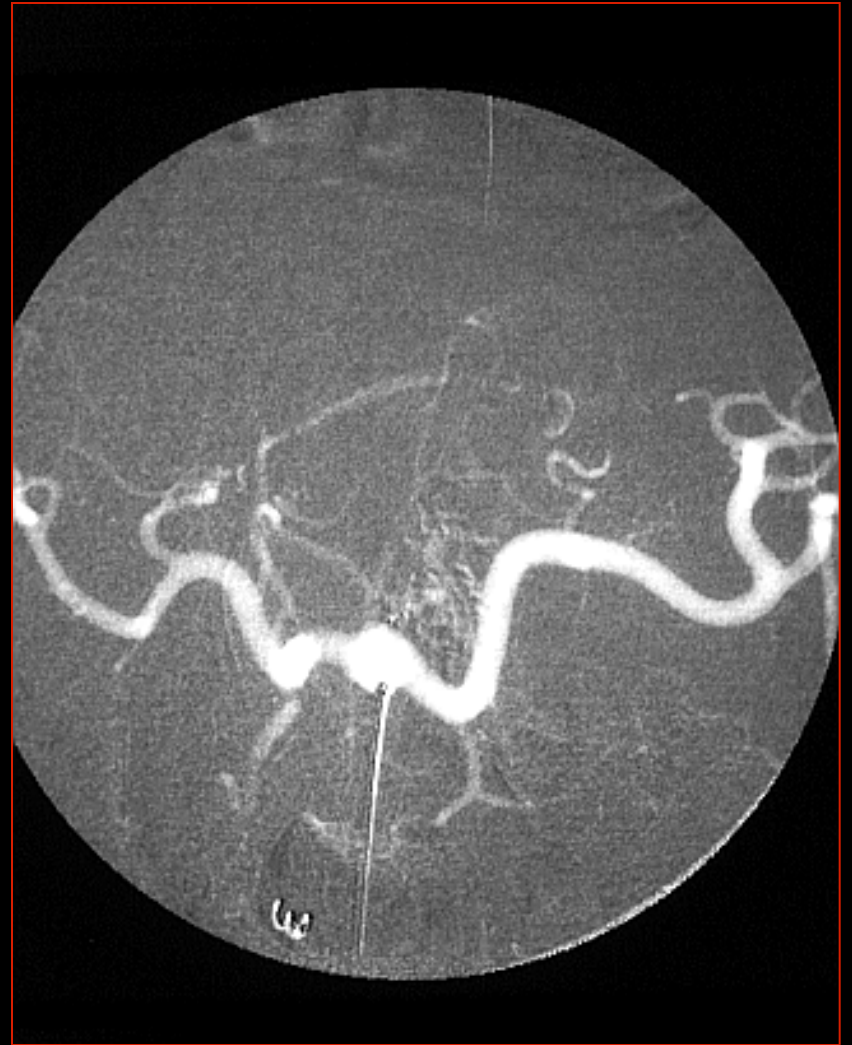



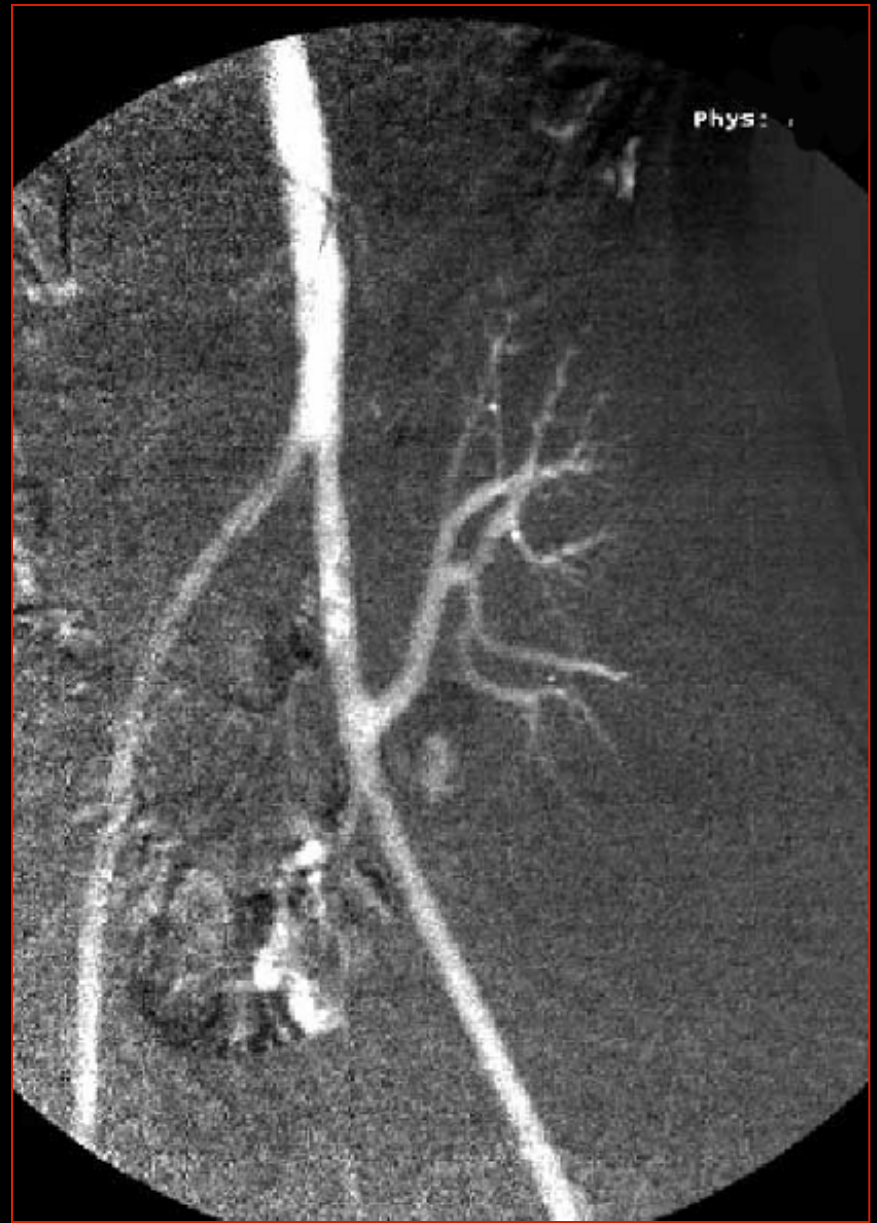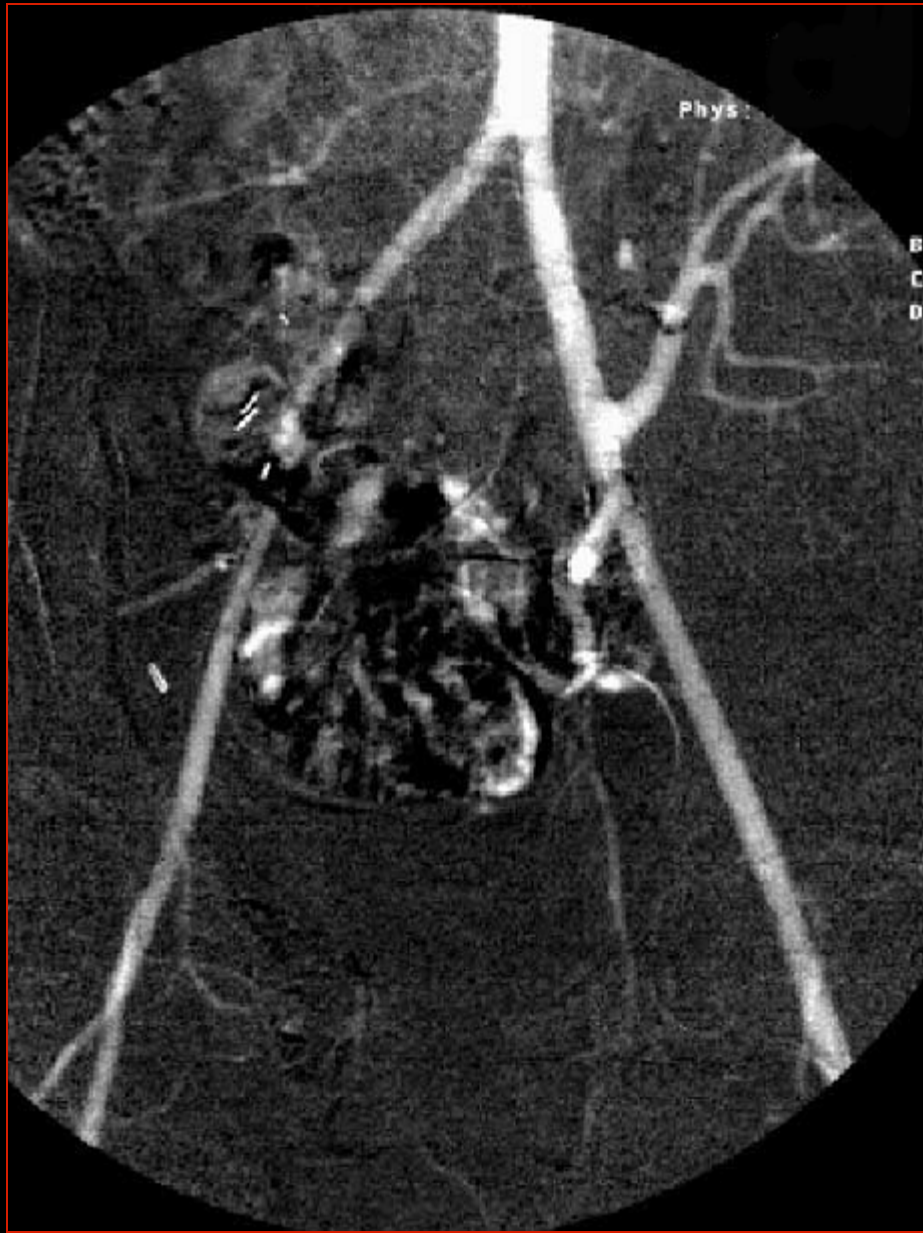**VESSELS LESS THAN  
10 MM HAVE 1/1  
CORRELATION WITH  
CONTRAST**

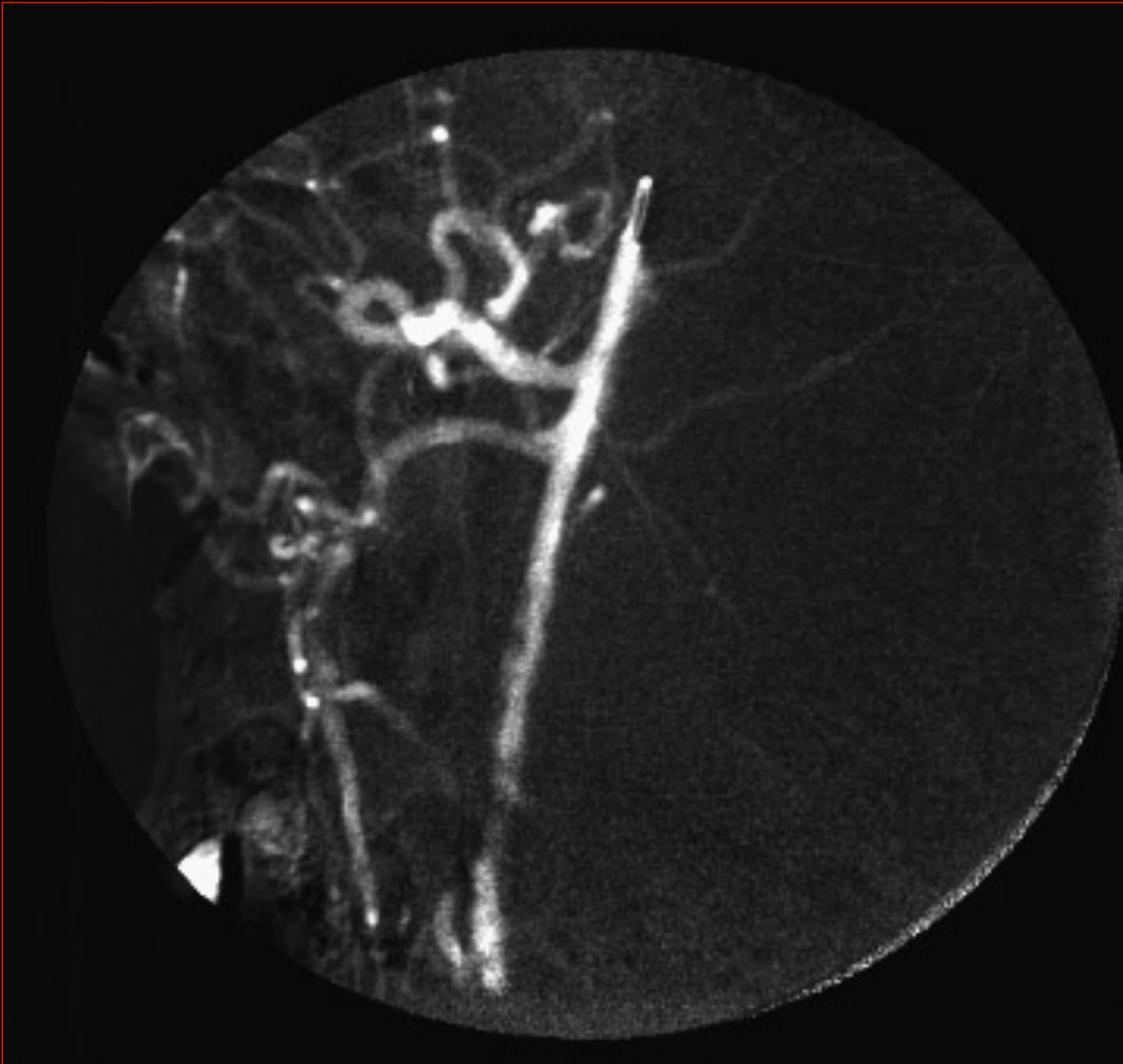


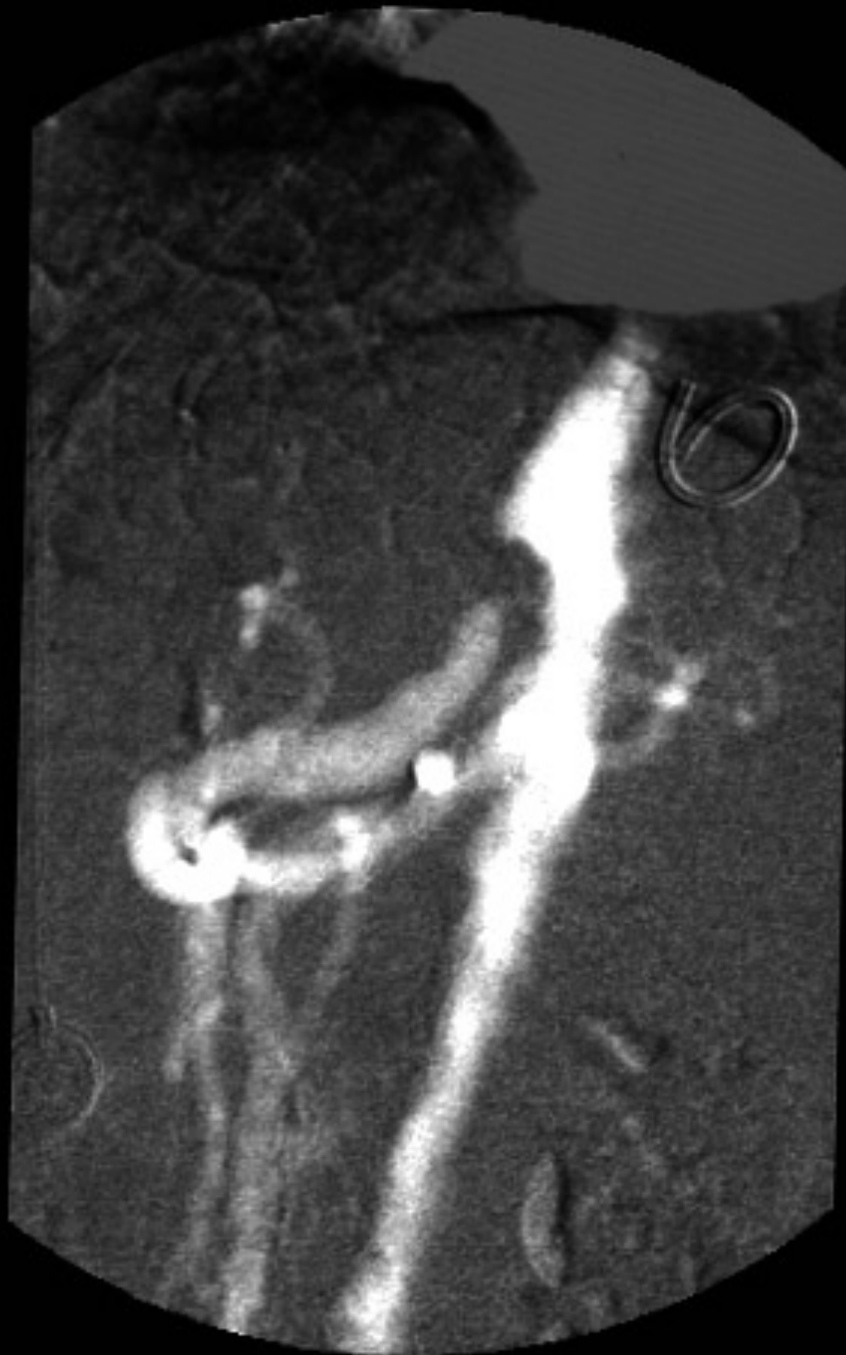
**Contrast**



**CO<sub>2</sub>**





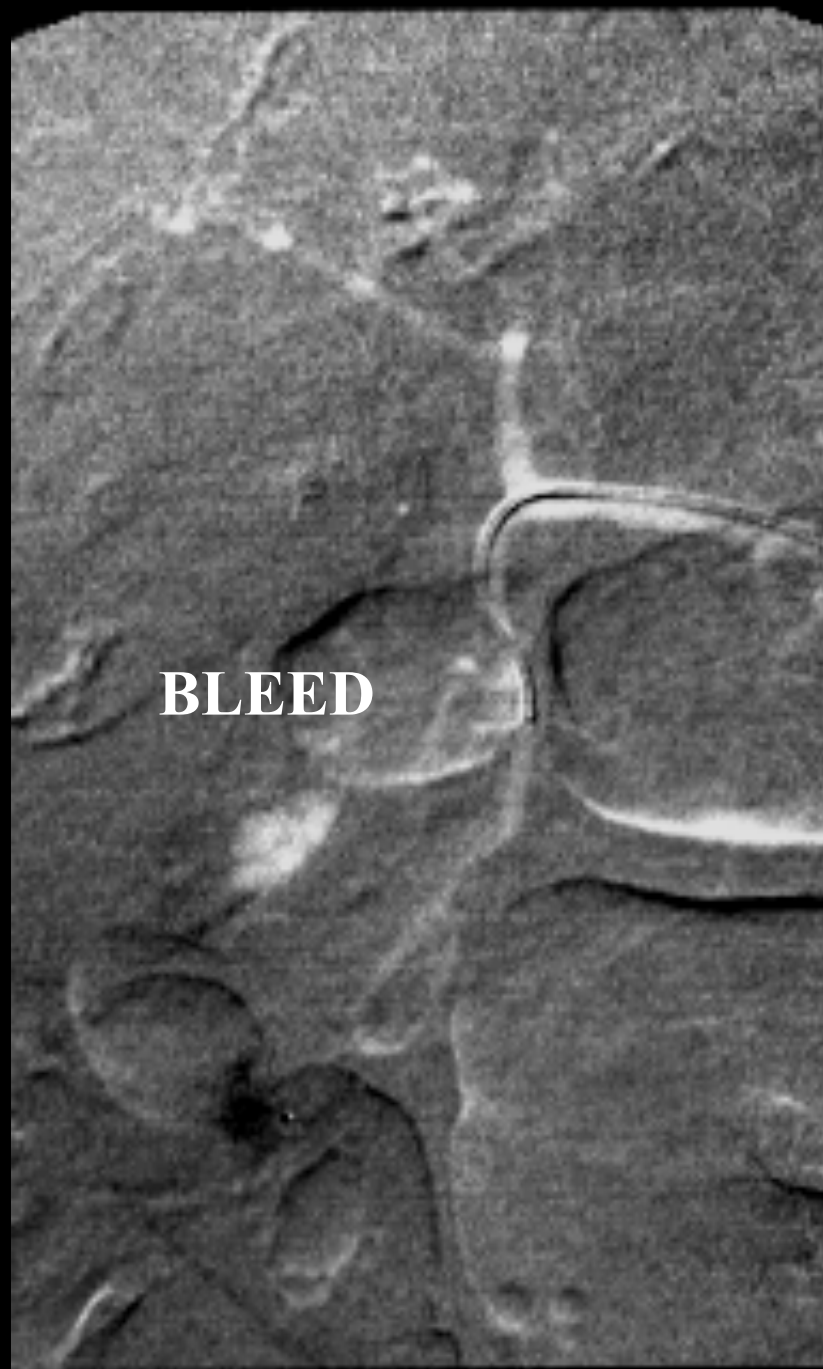
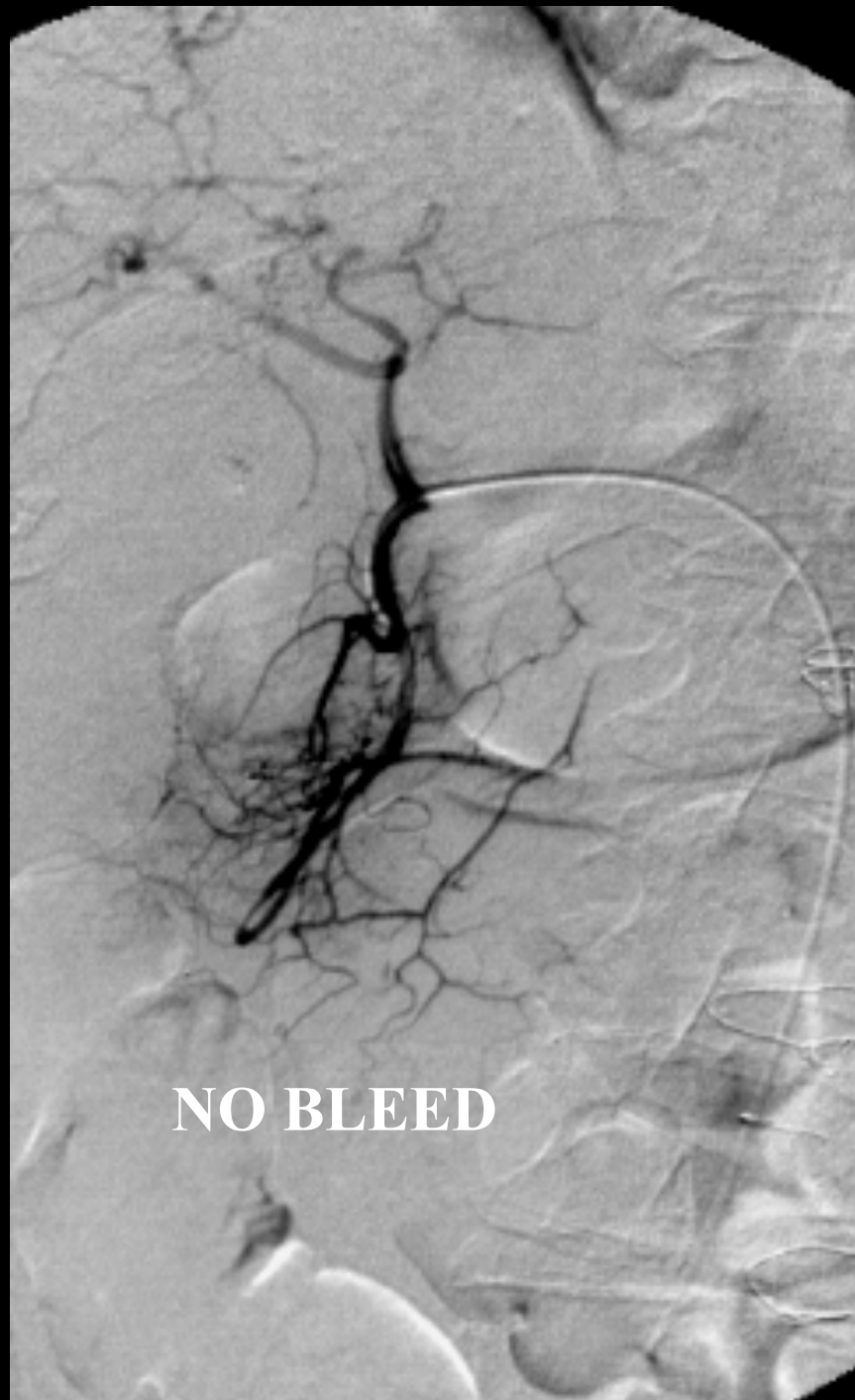

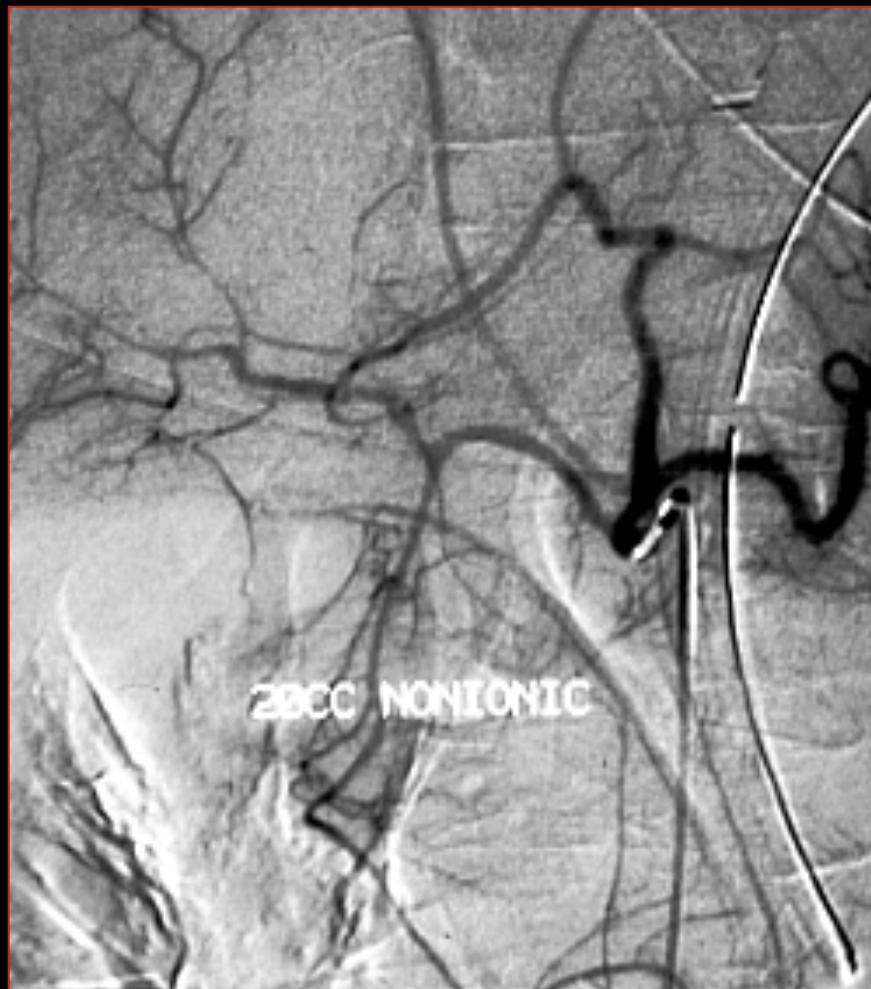# **IMPROVED DETECTION OF BLEEDING / FISTULA**

- 1. CO<sub>2</sub> - low viscosity**
- 2. CO<sub>2</sub> exits the vessel and expands**
- 3. Little or no capillary phase to obscure CO<sub>2</sub>**
- 4. CO<sub>2</sub> is not diluted by blood**

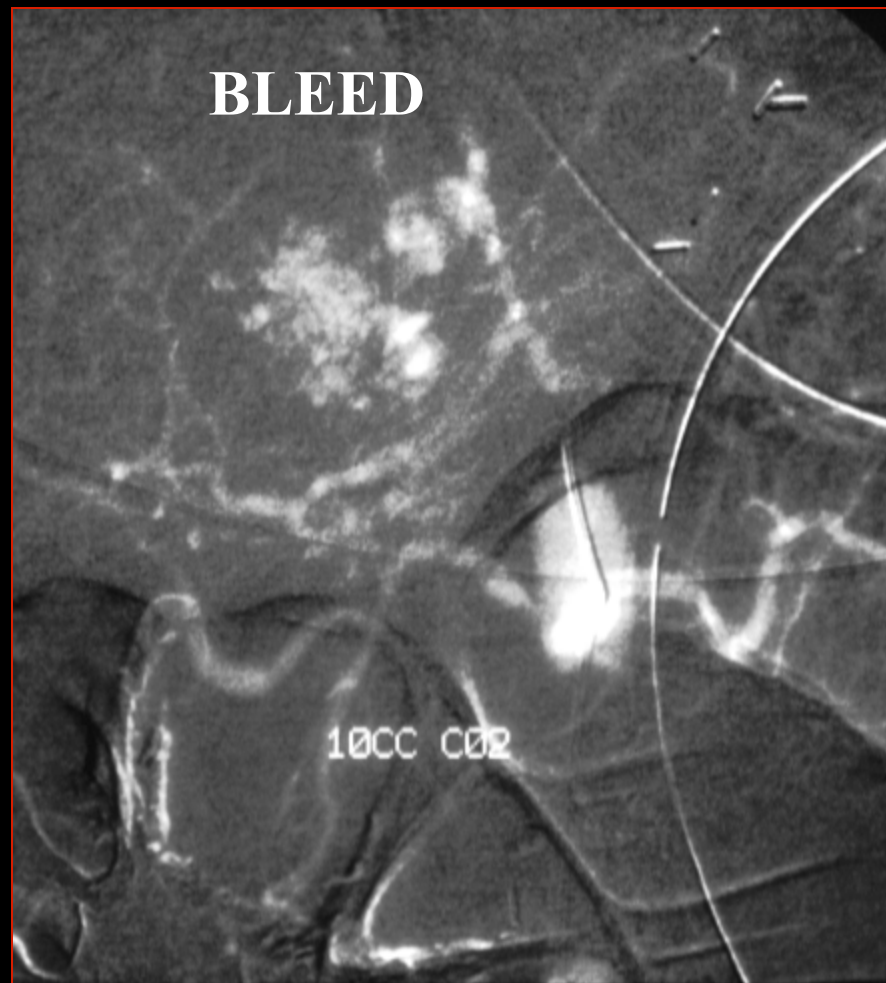
**Hashimoto et al, Sem Interven Rad 1997; 14:163-173**

**Hawkins et al, Sem Interven Rad 1997; 14:175-180**

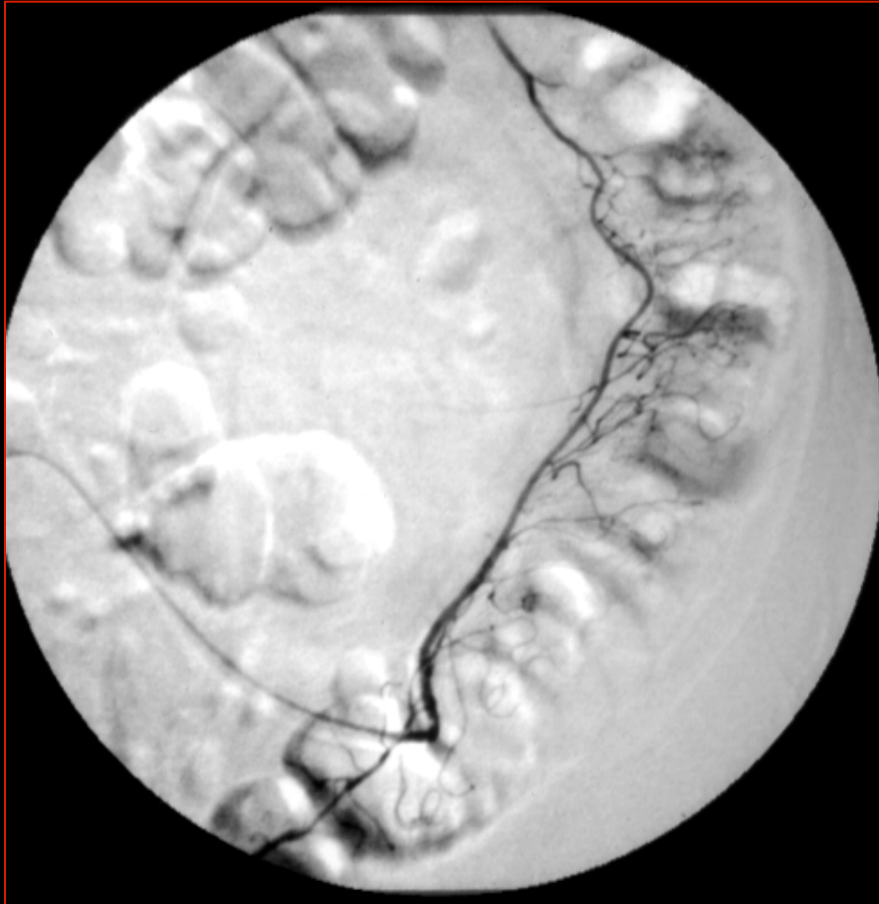



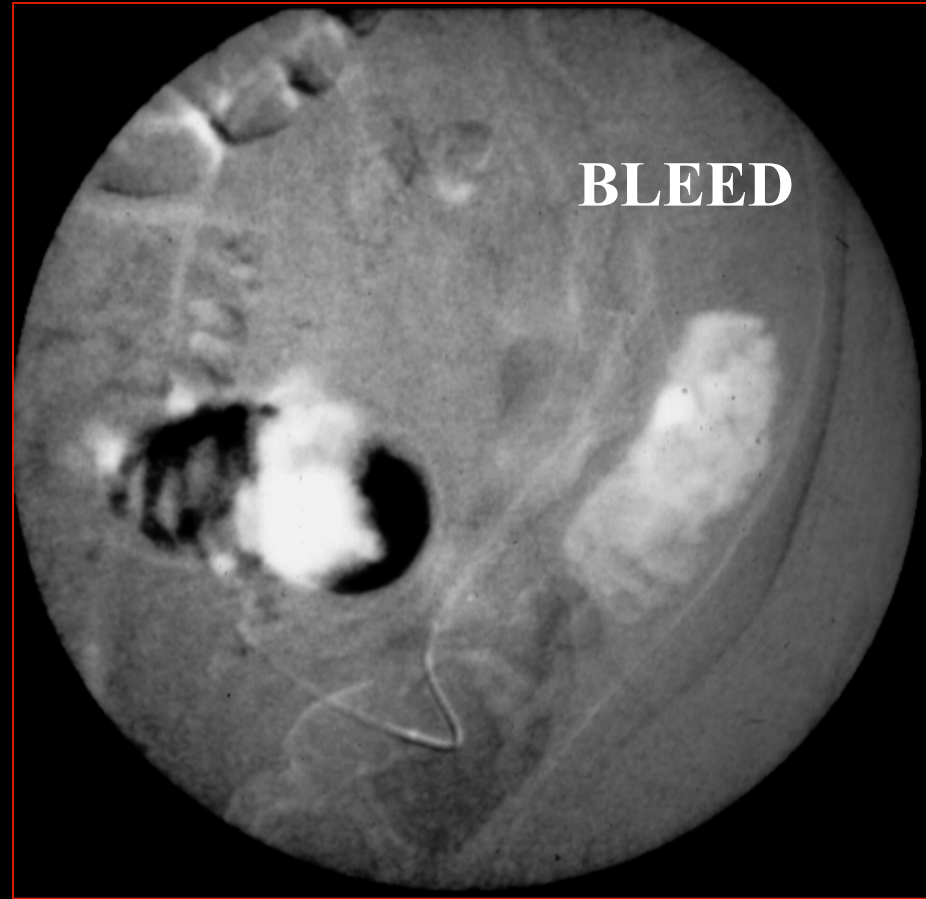
**CONTRAST**



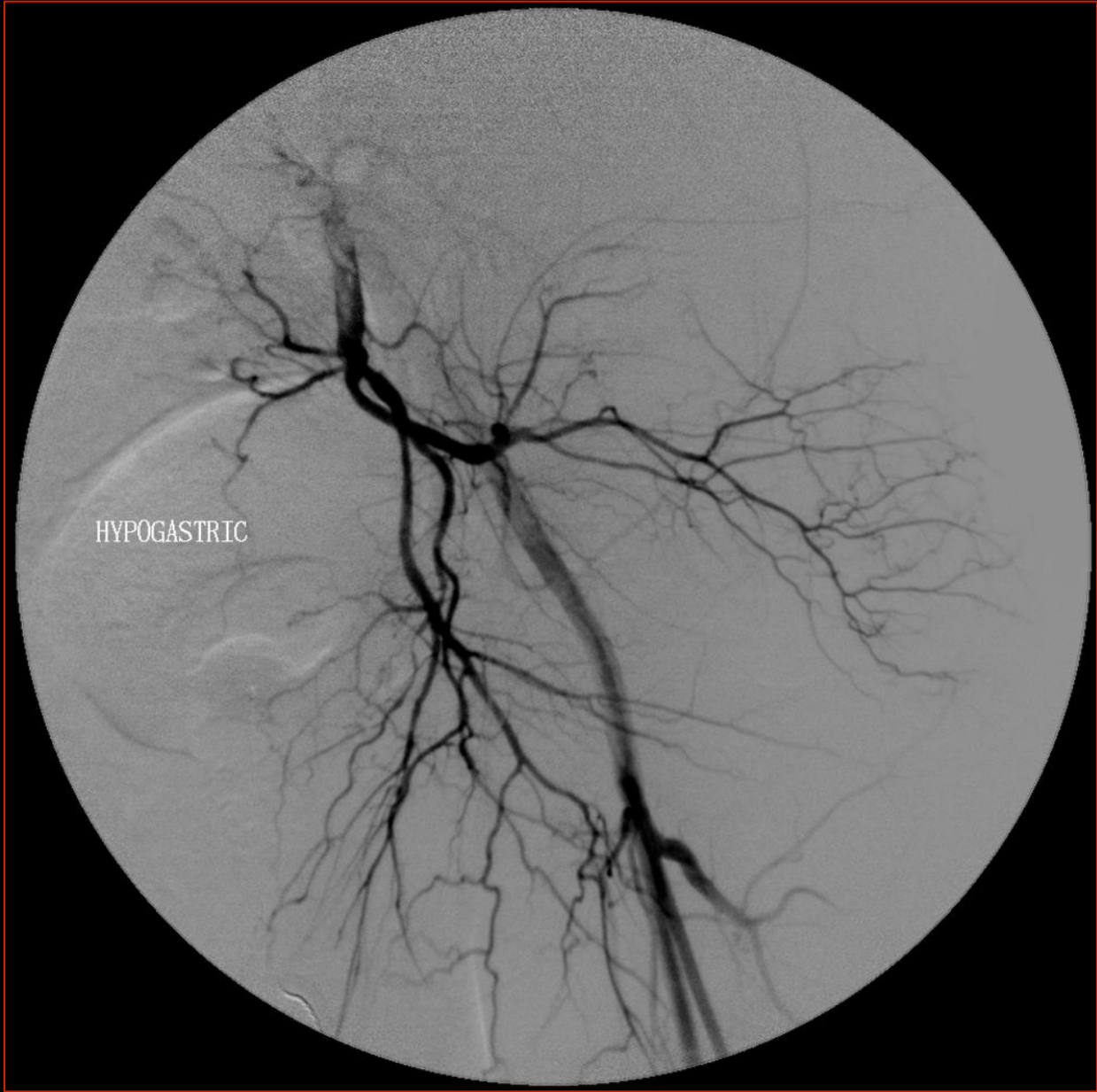**CO<sub>2</sub>**

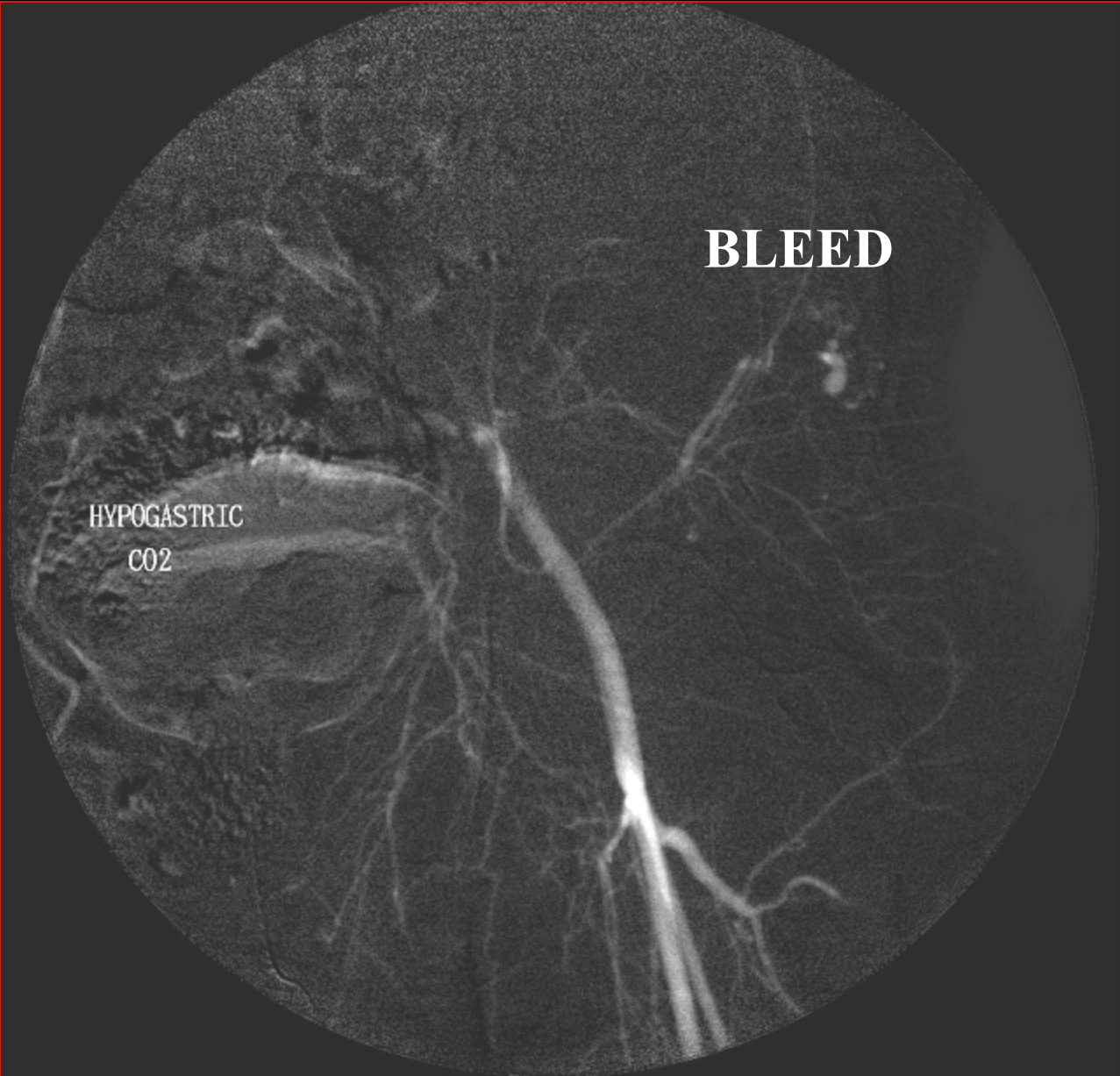


**CONTRAST**



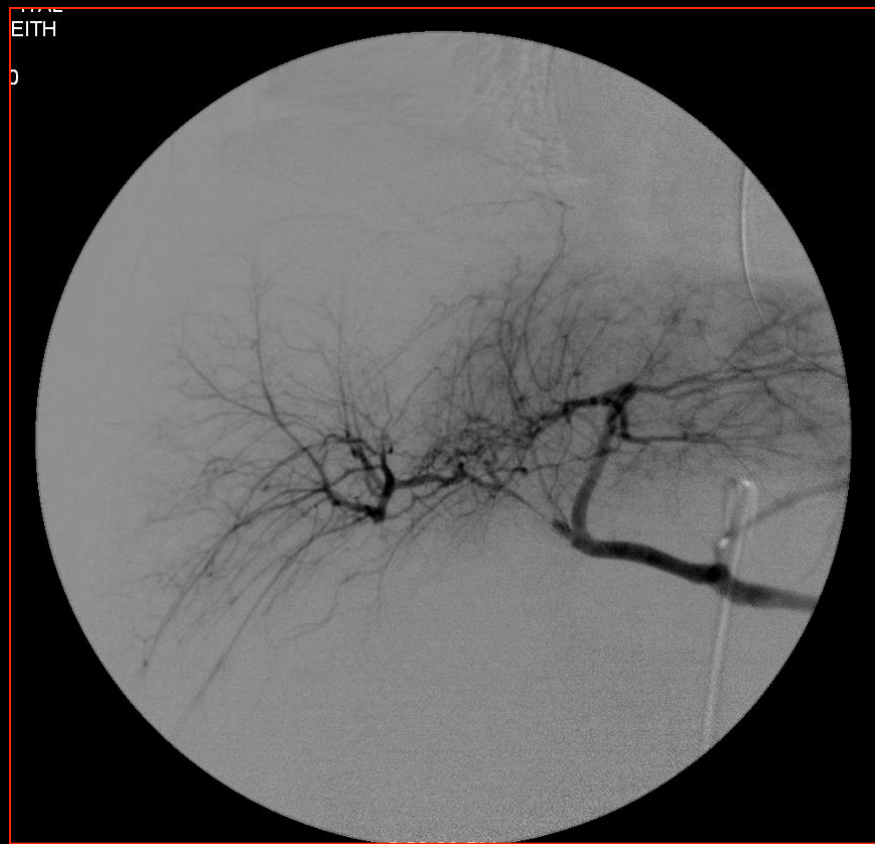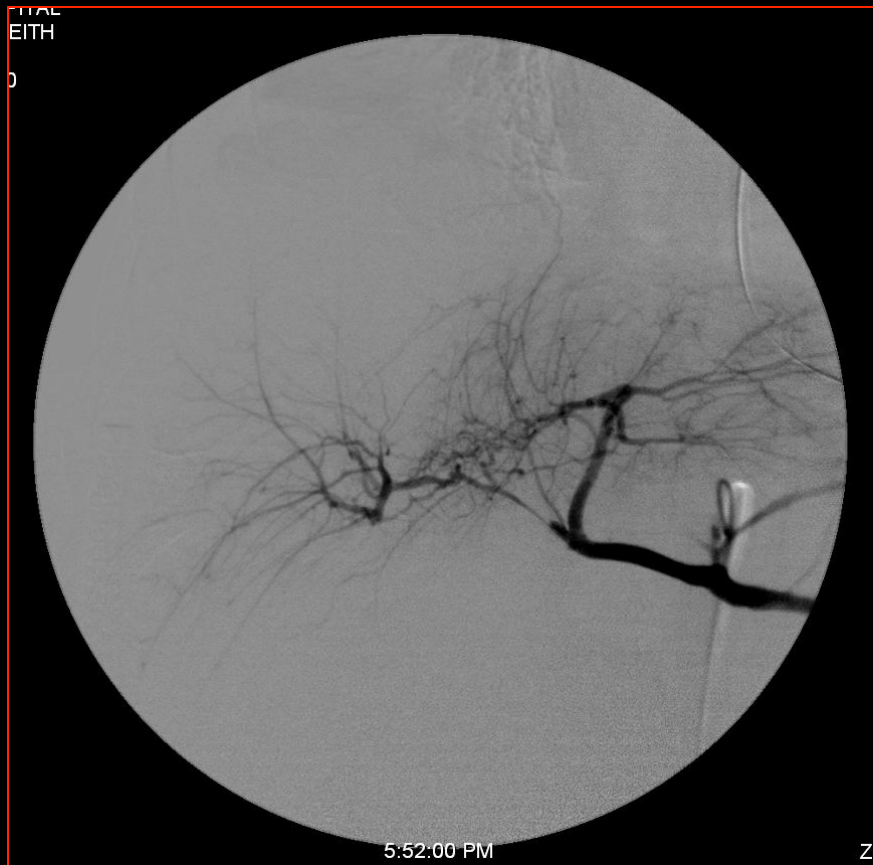**CO<sub>2</sub>**

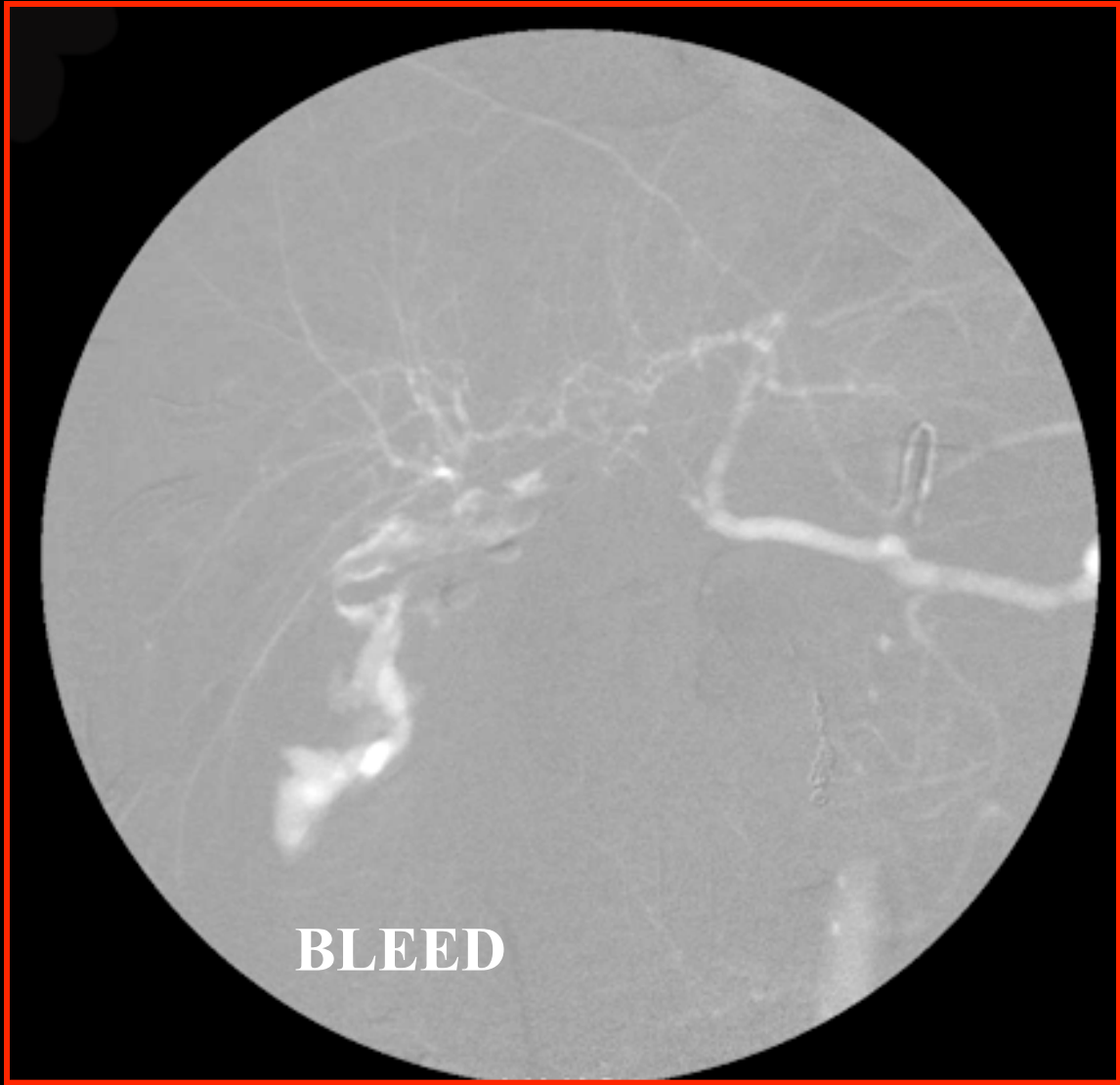




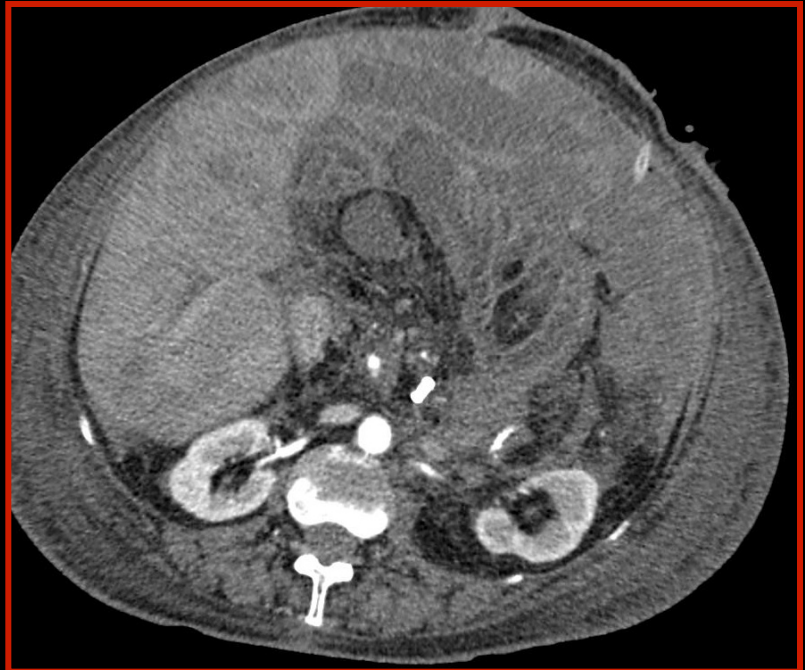
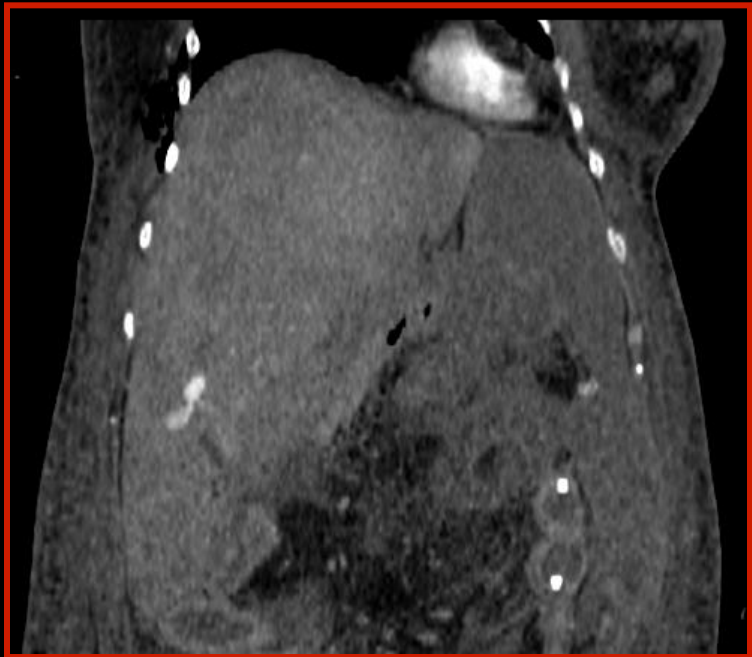
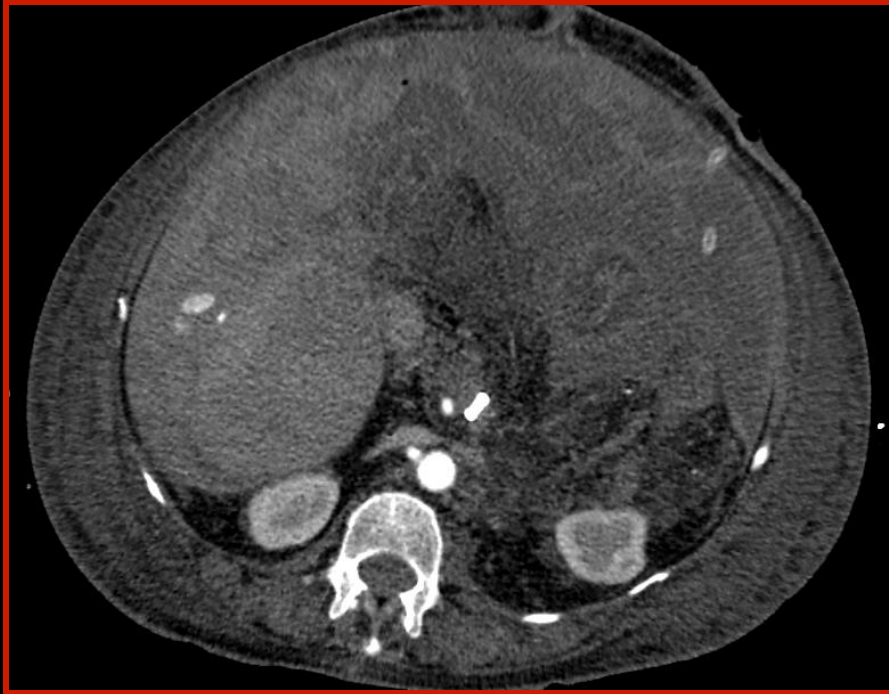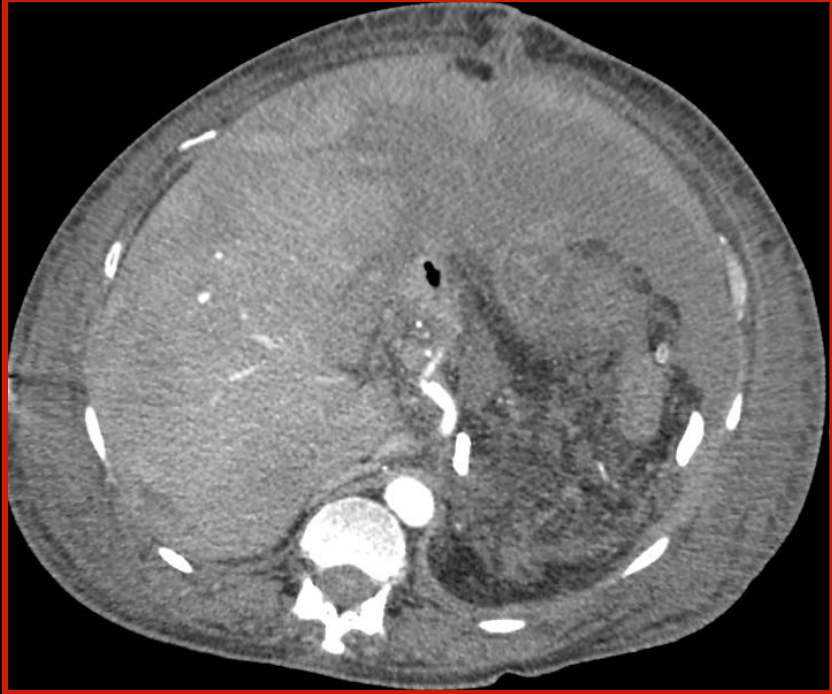
**BLEED**

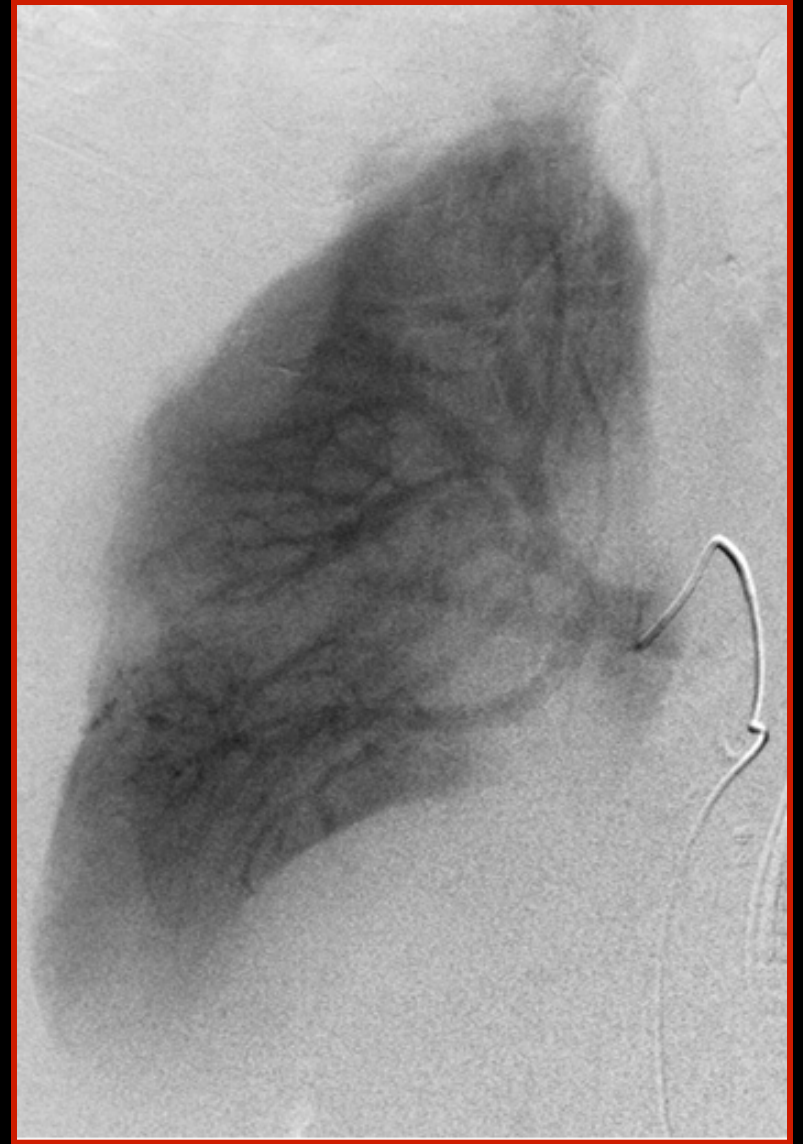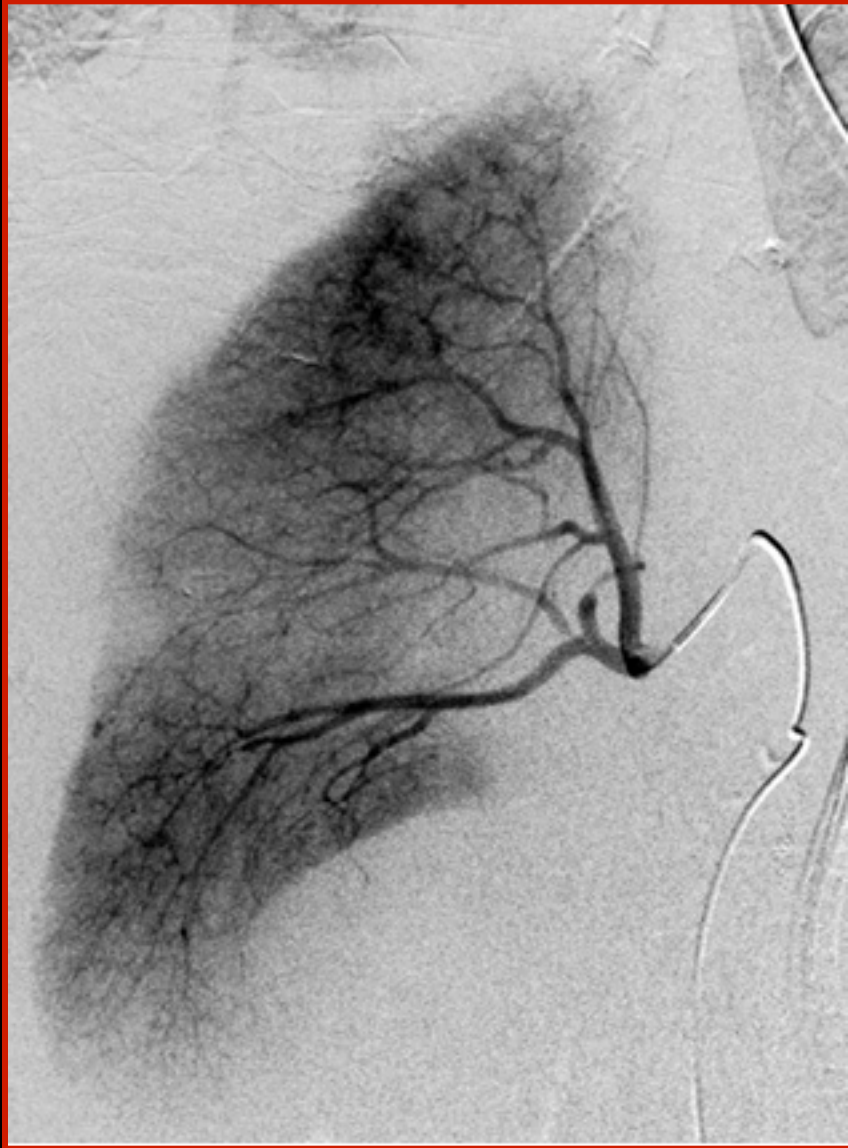HYPOGASTRIC  
CO2

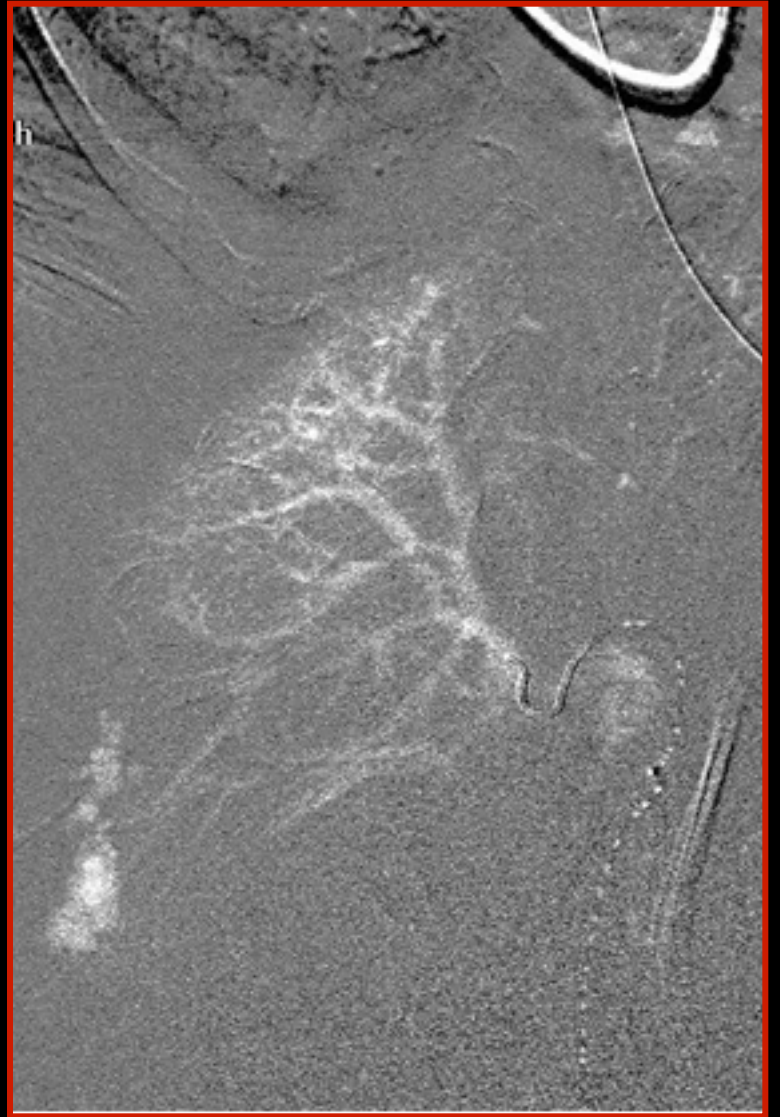
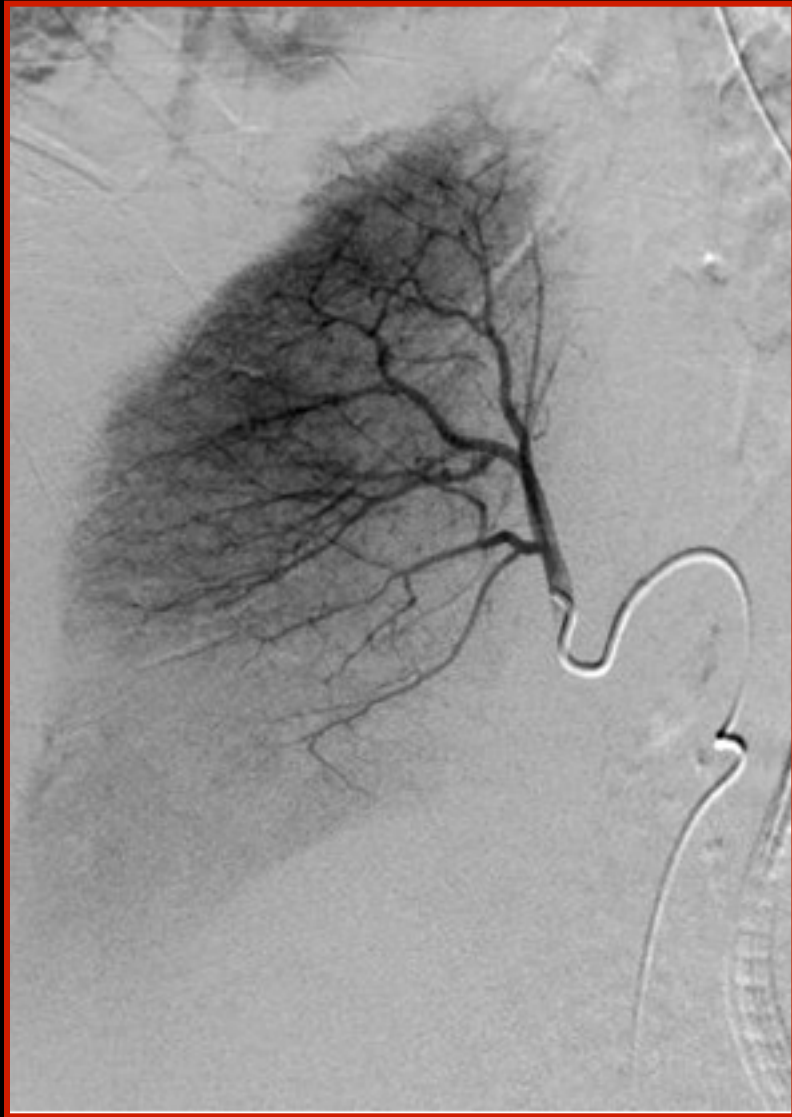
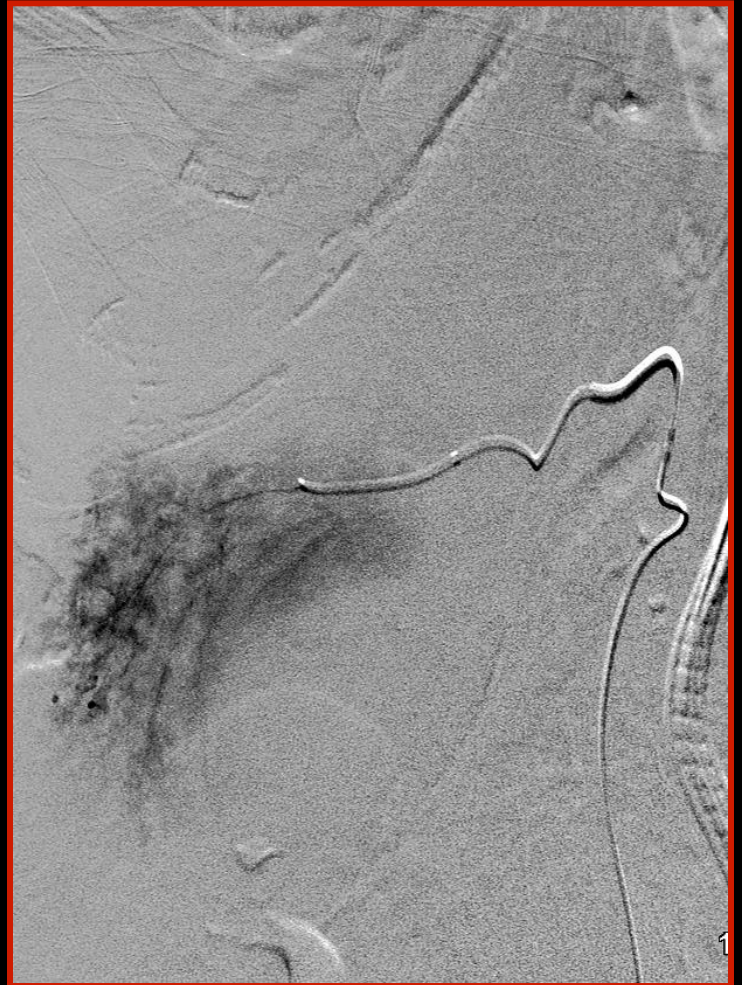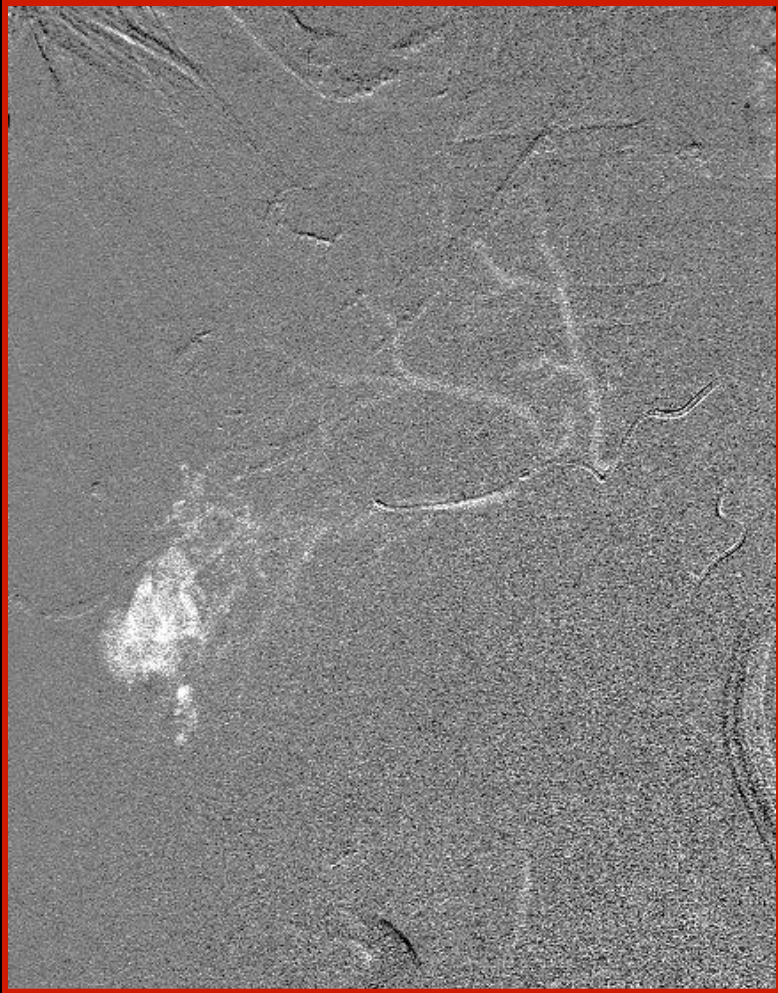


**BLEED**

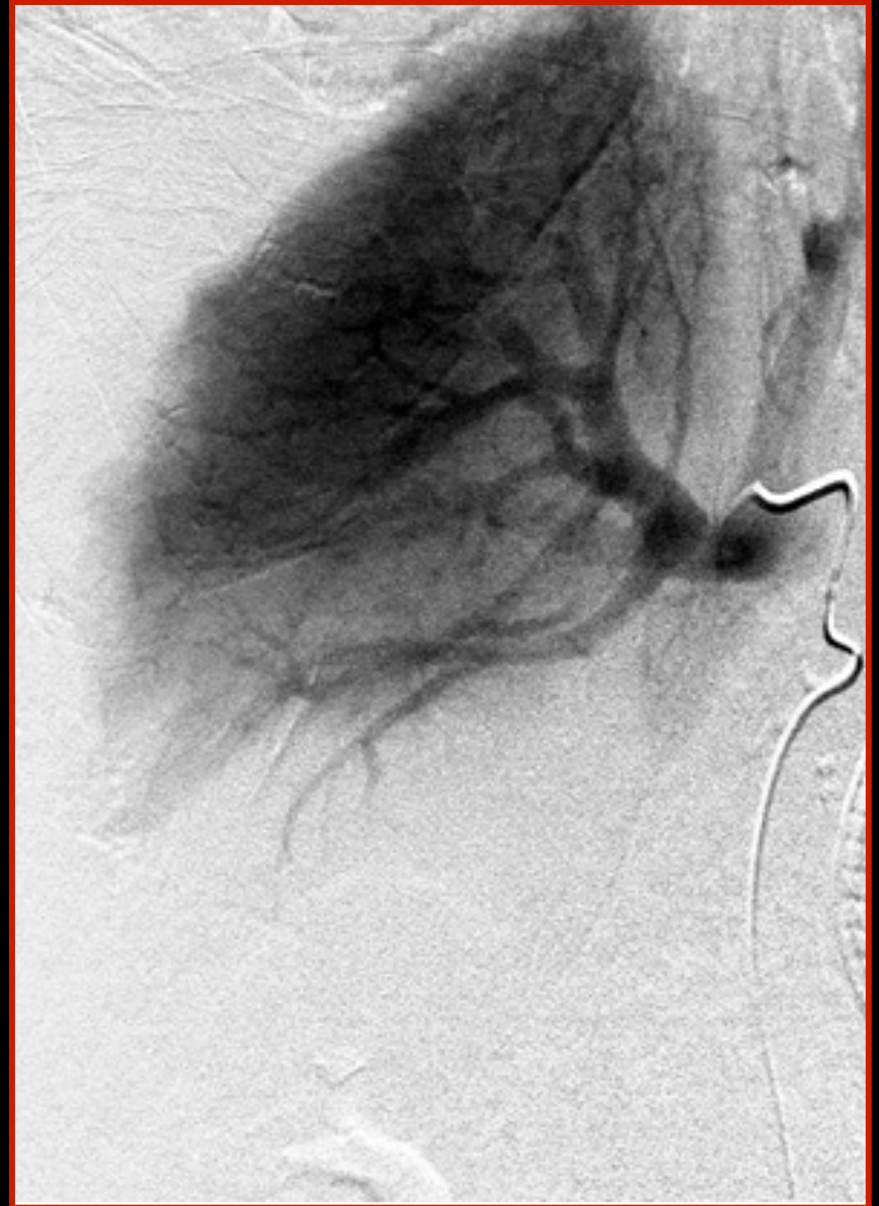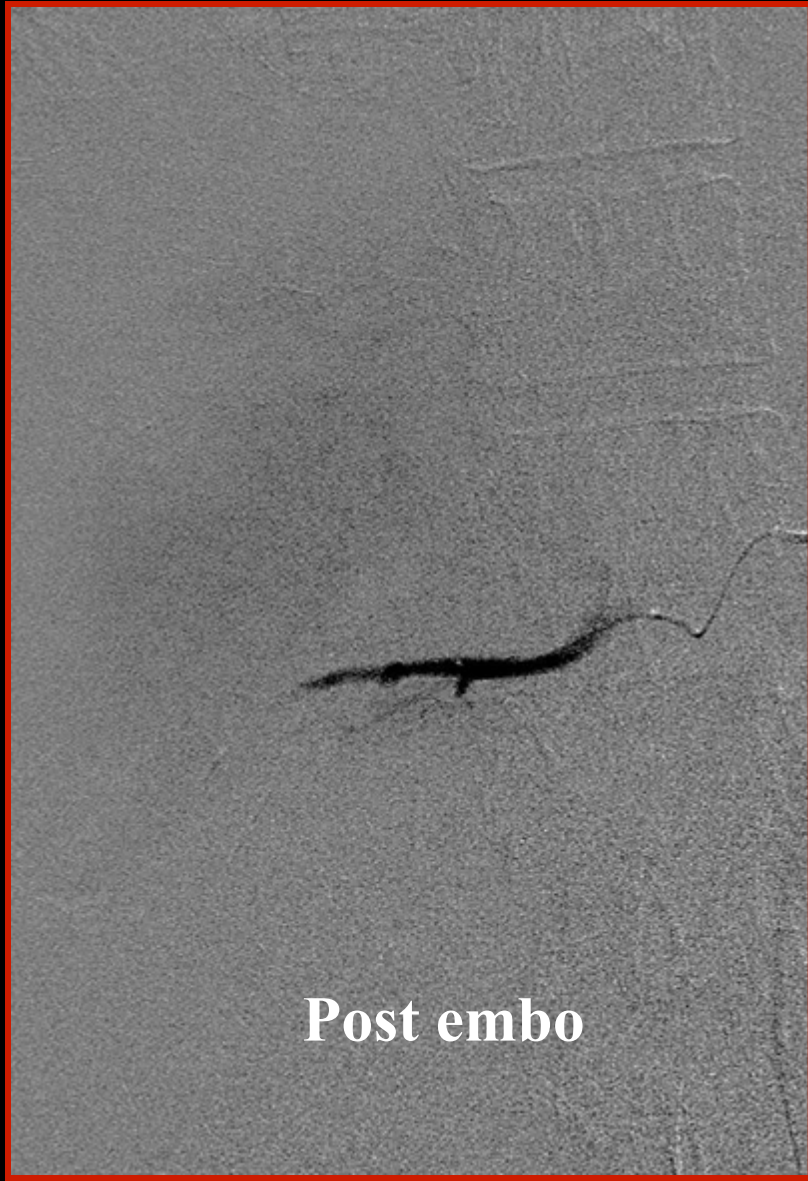



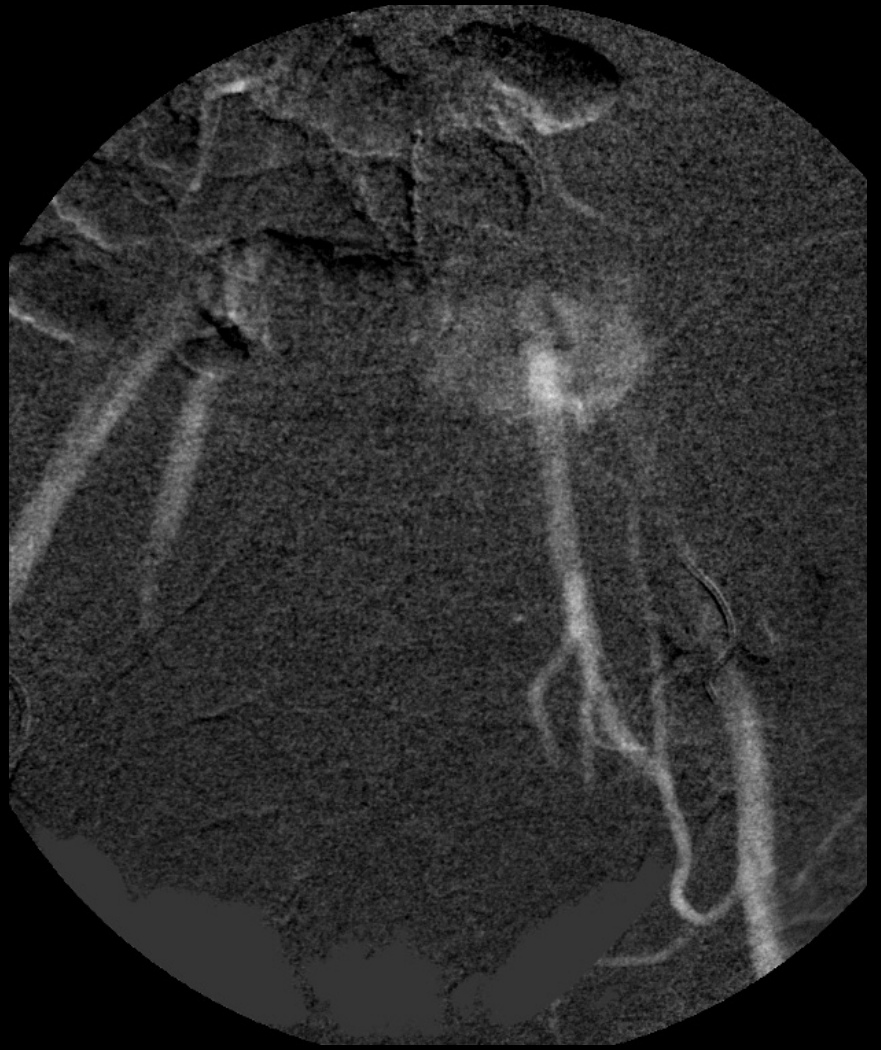
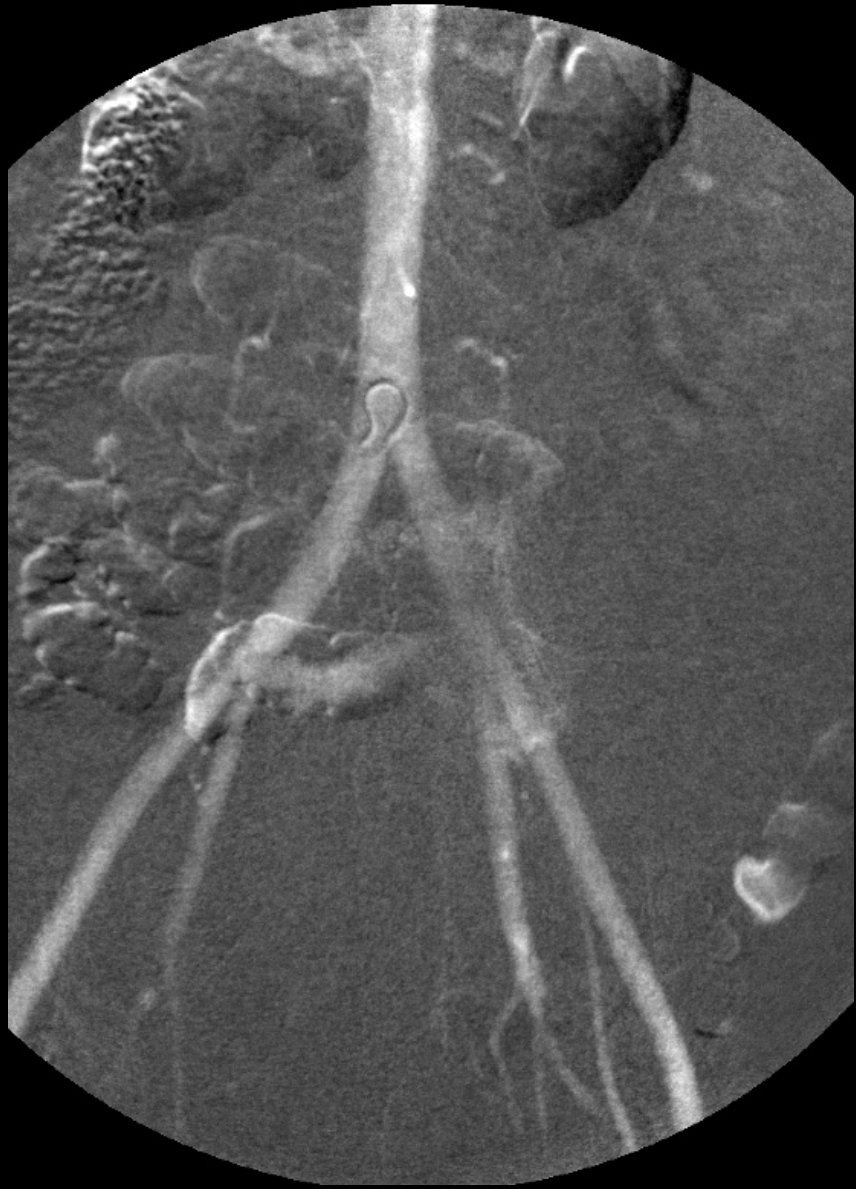


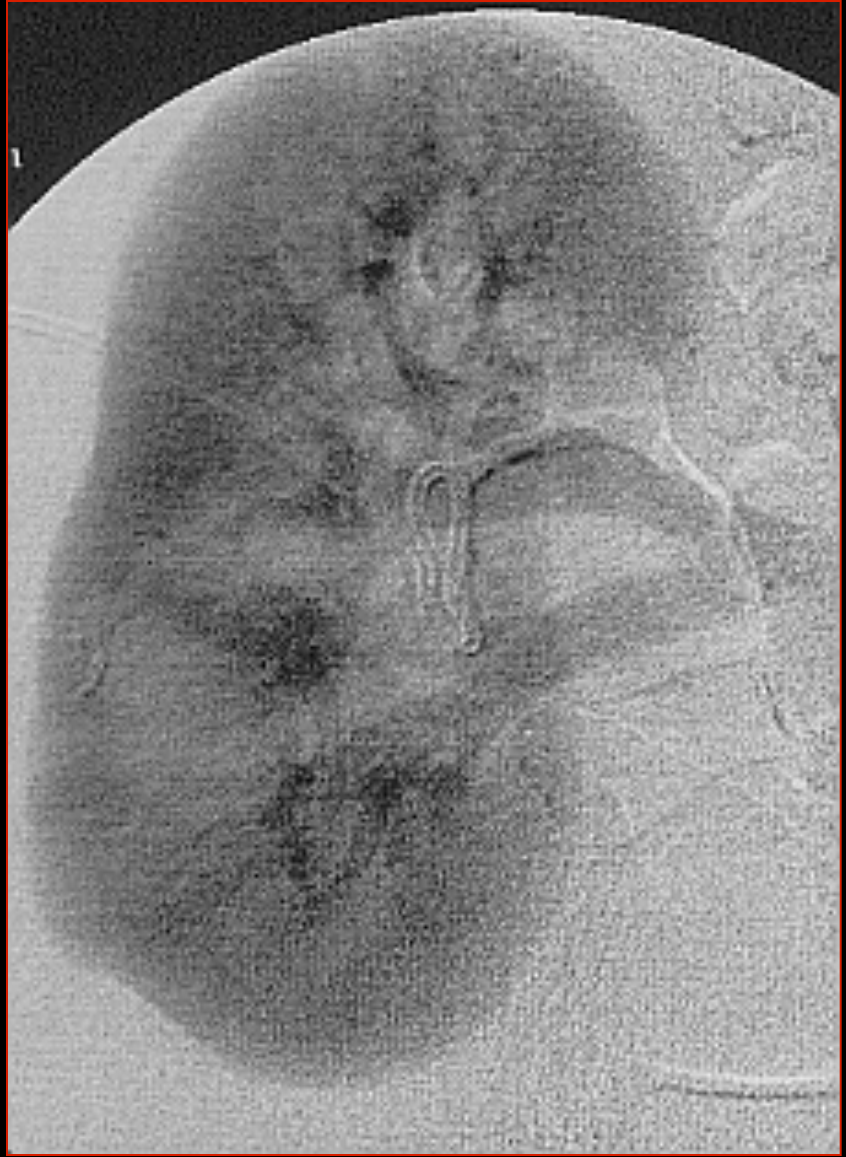
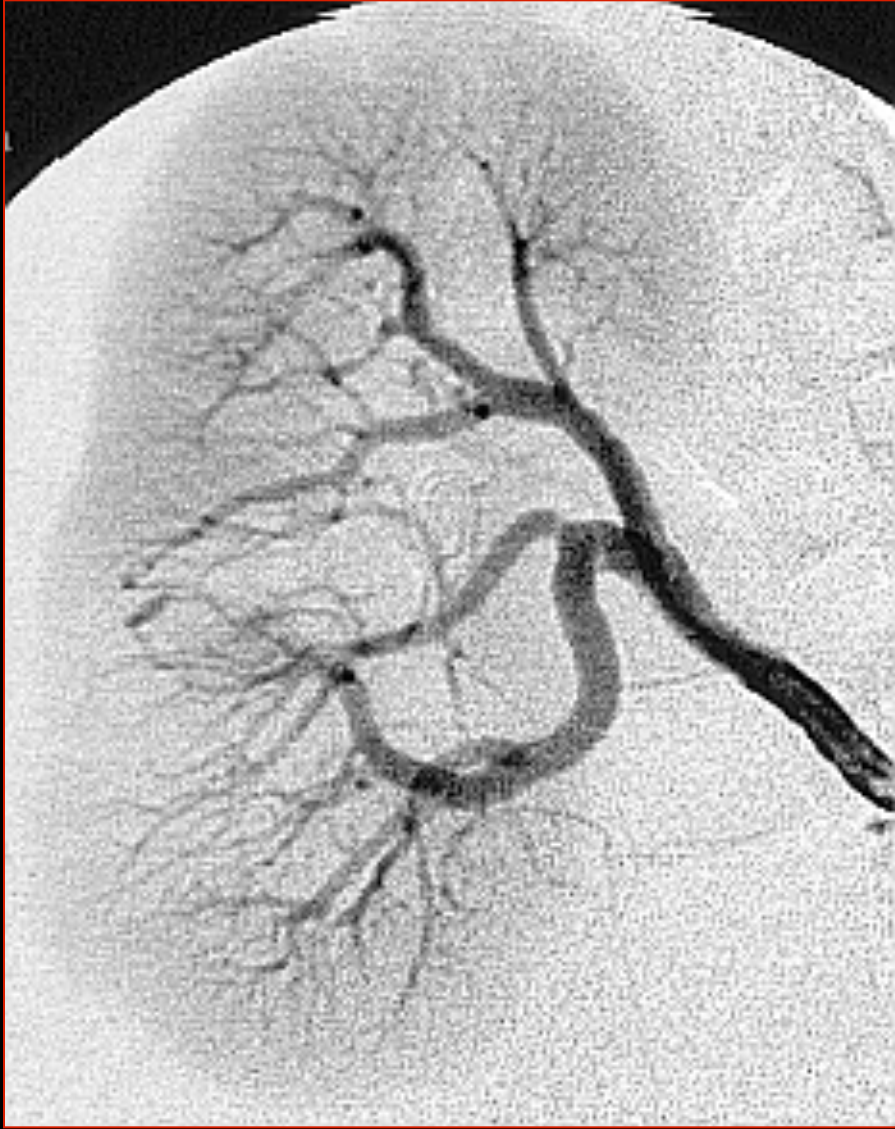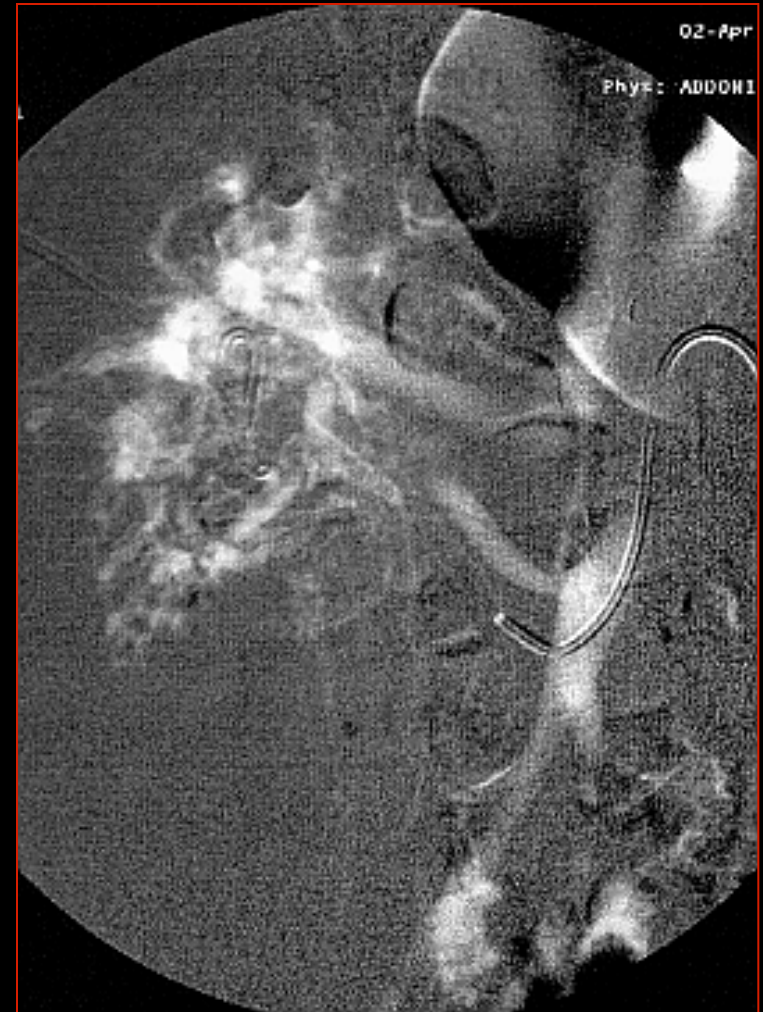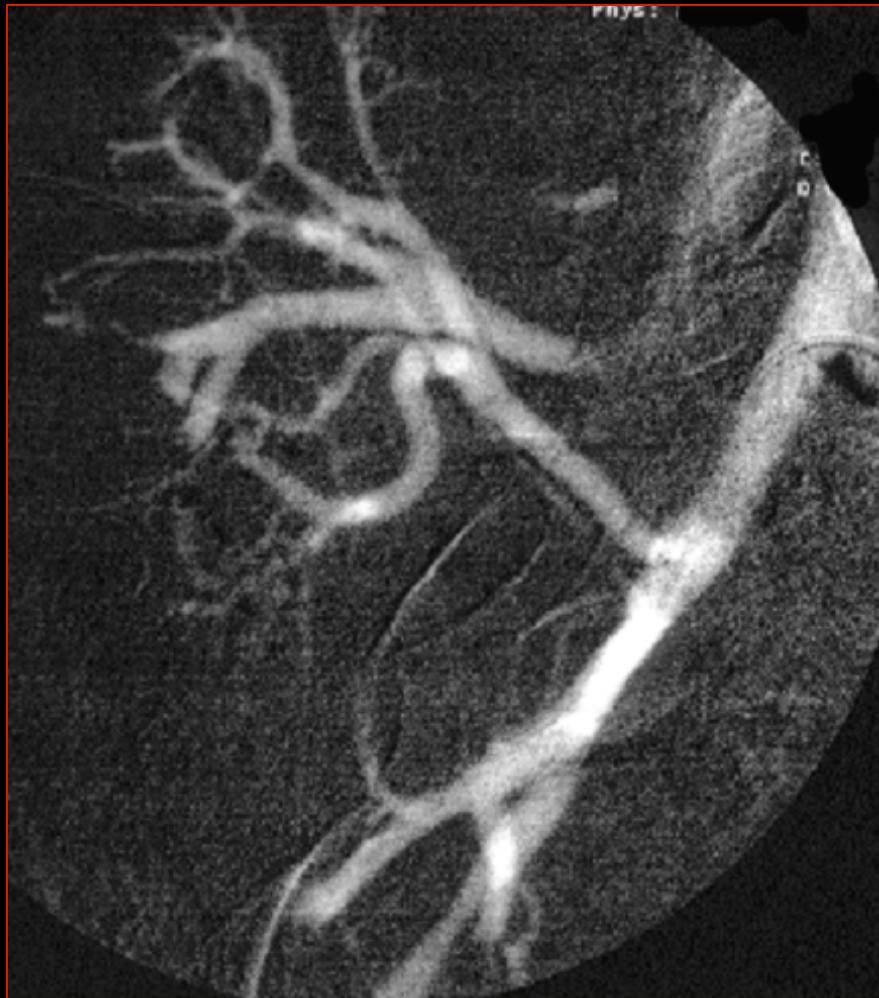**POST**



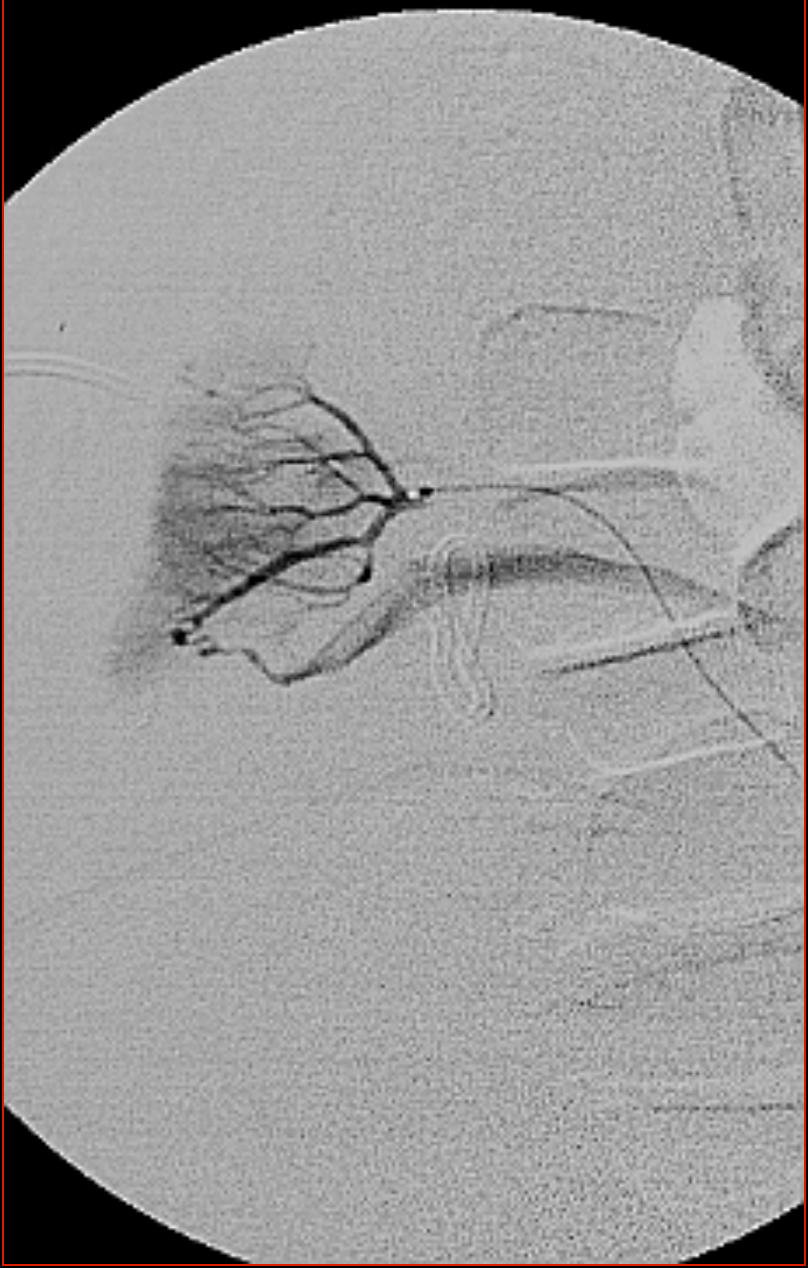
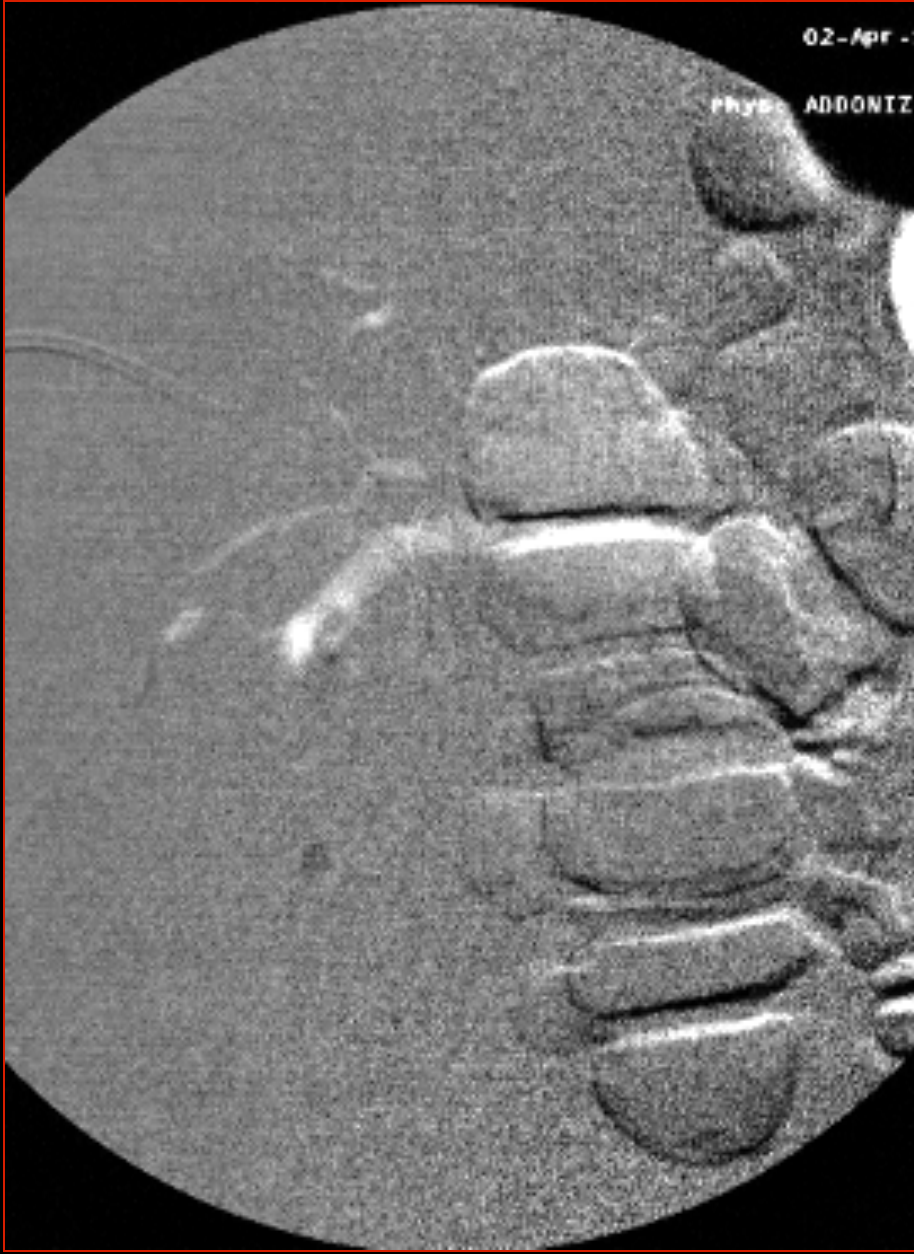


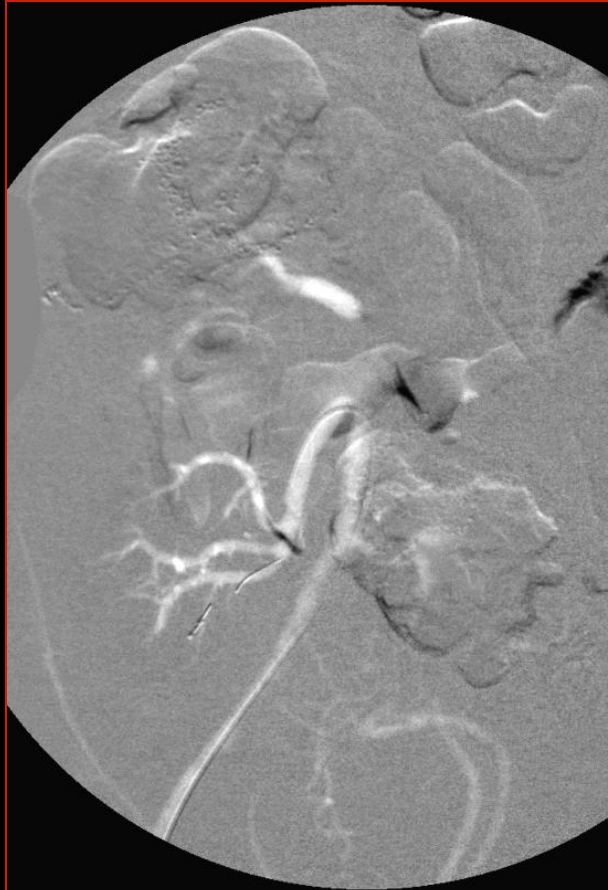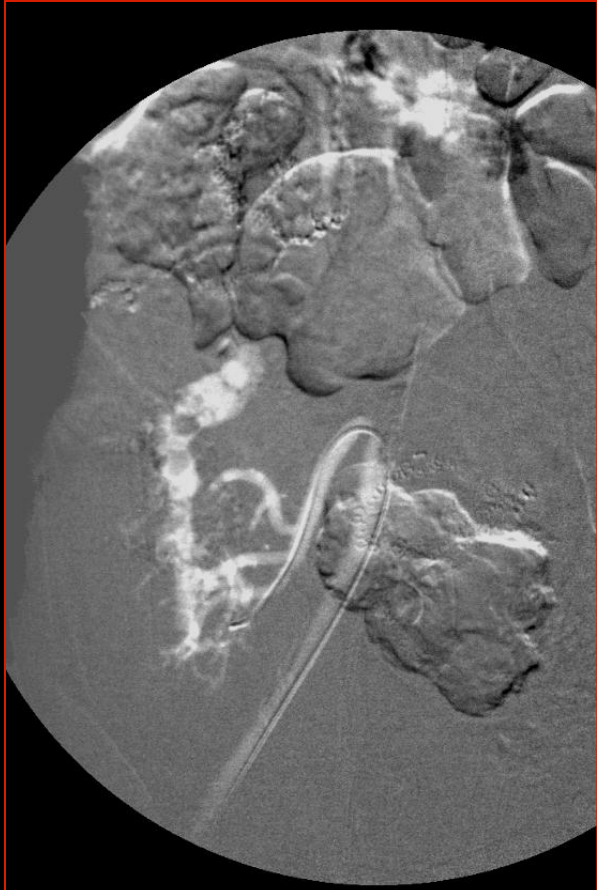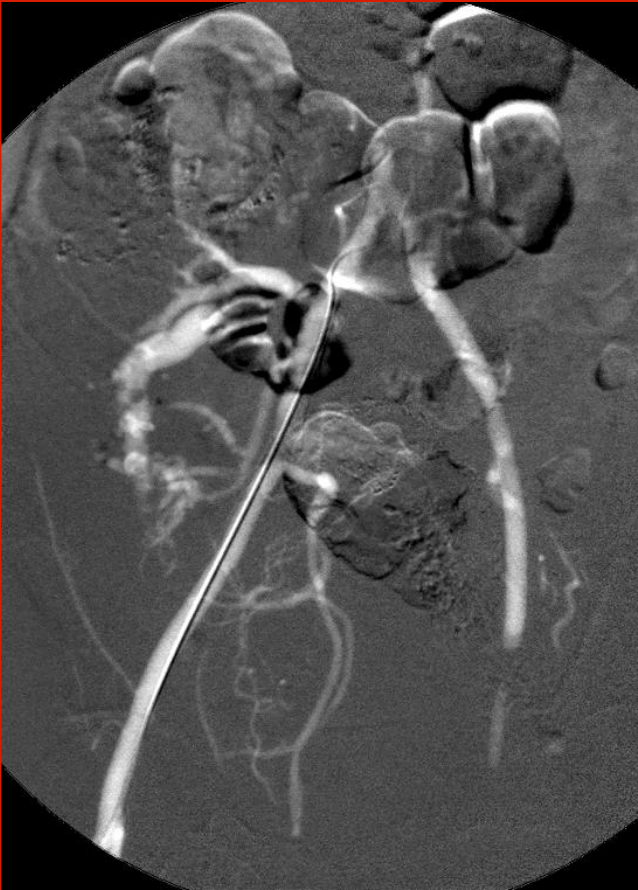**No AVF**

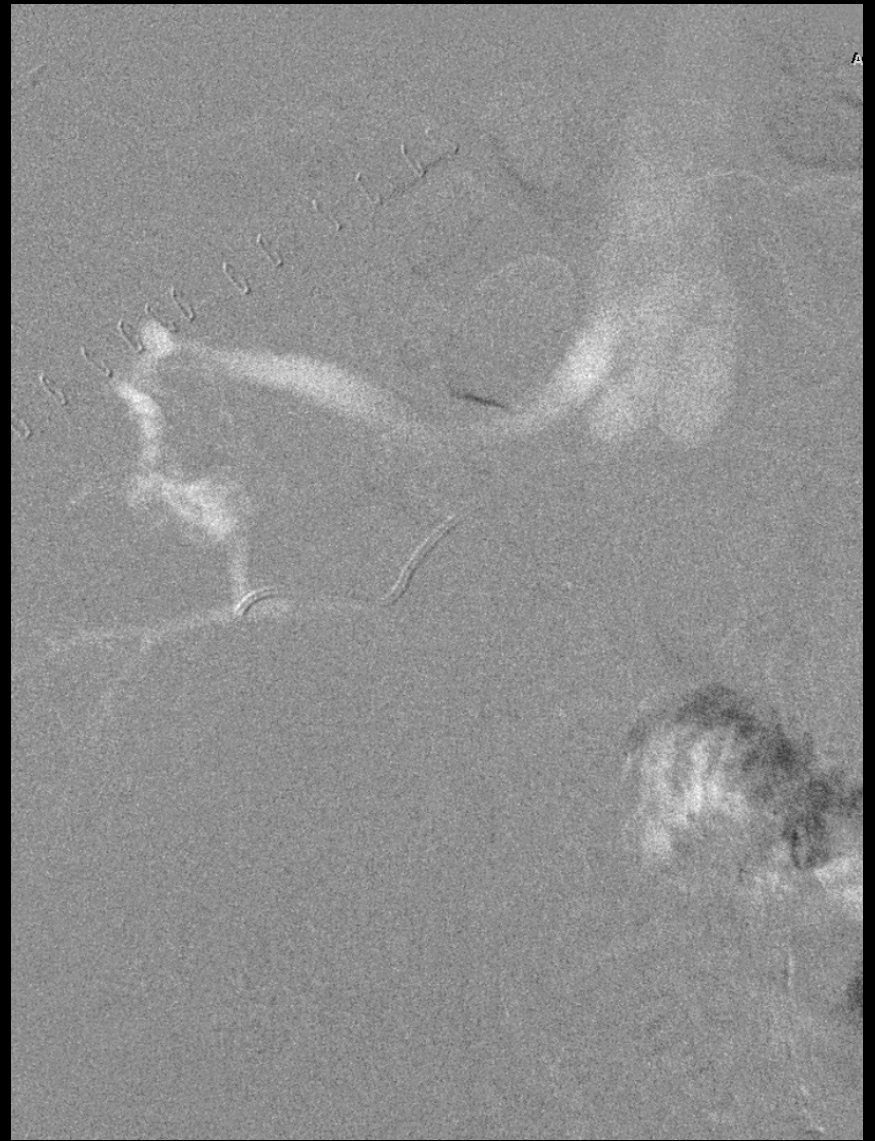
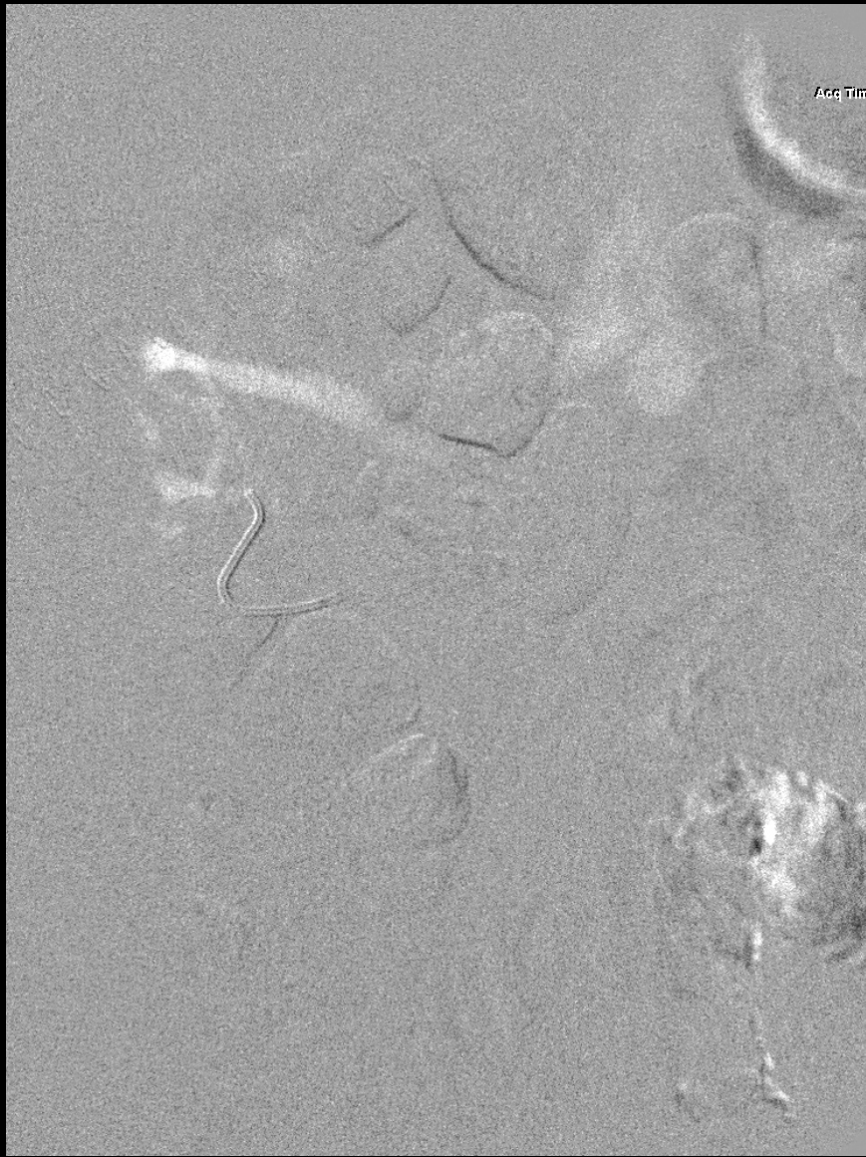

**Non selective AVF not seen with select liquid contrast**

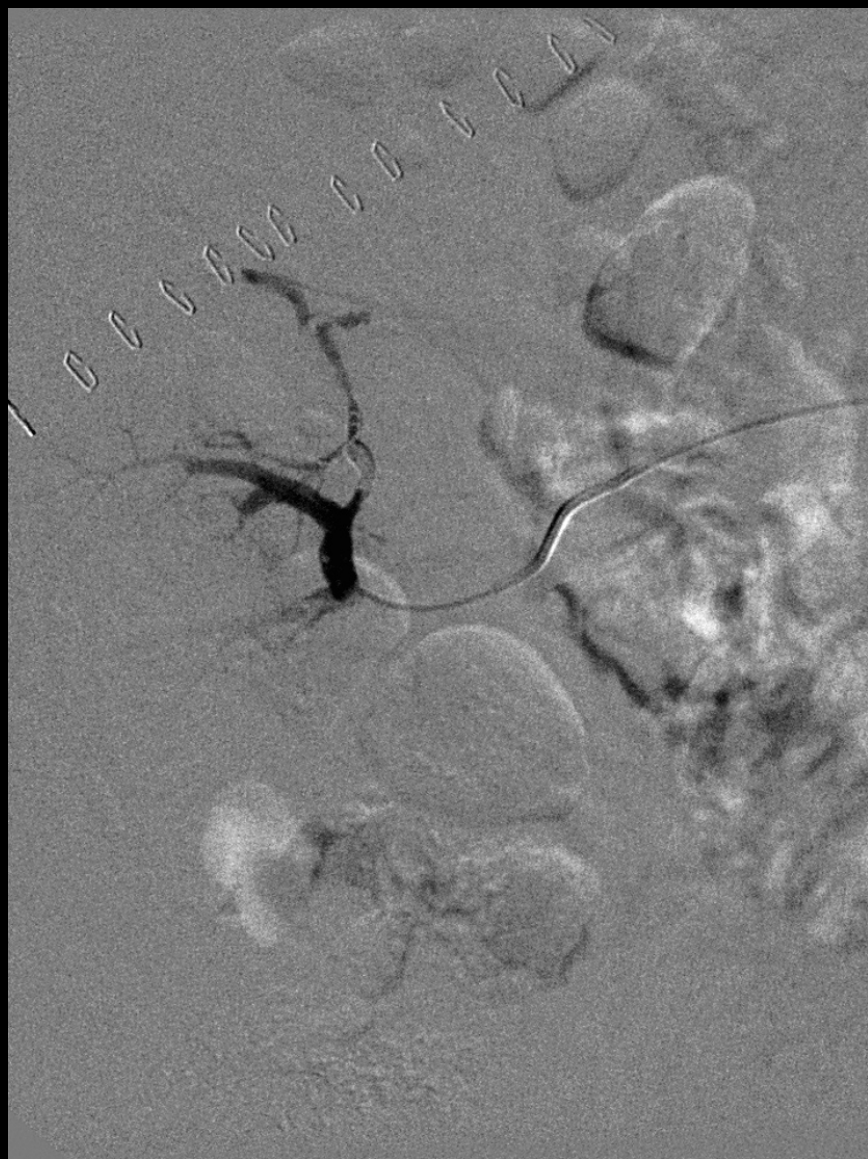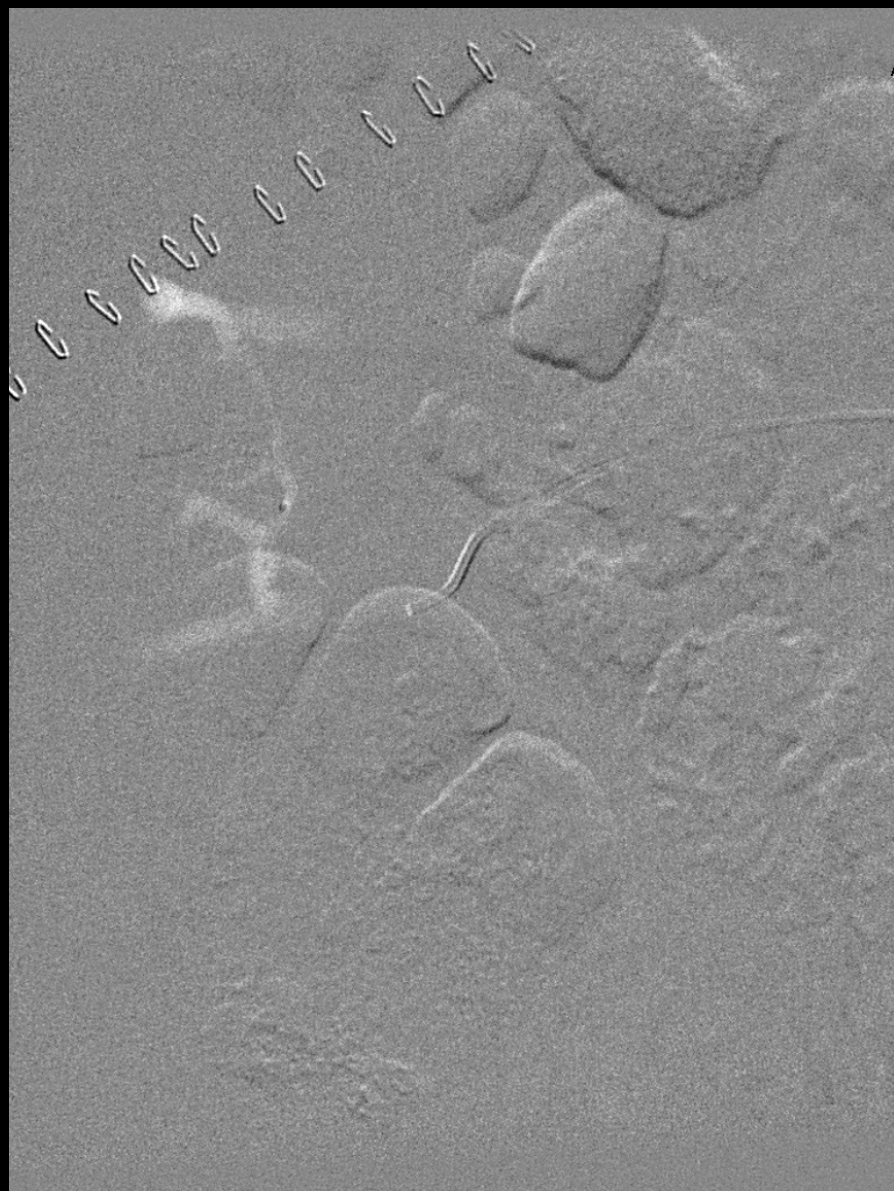




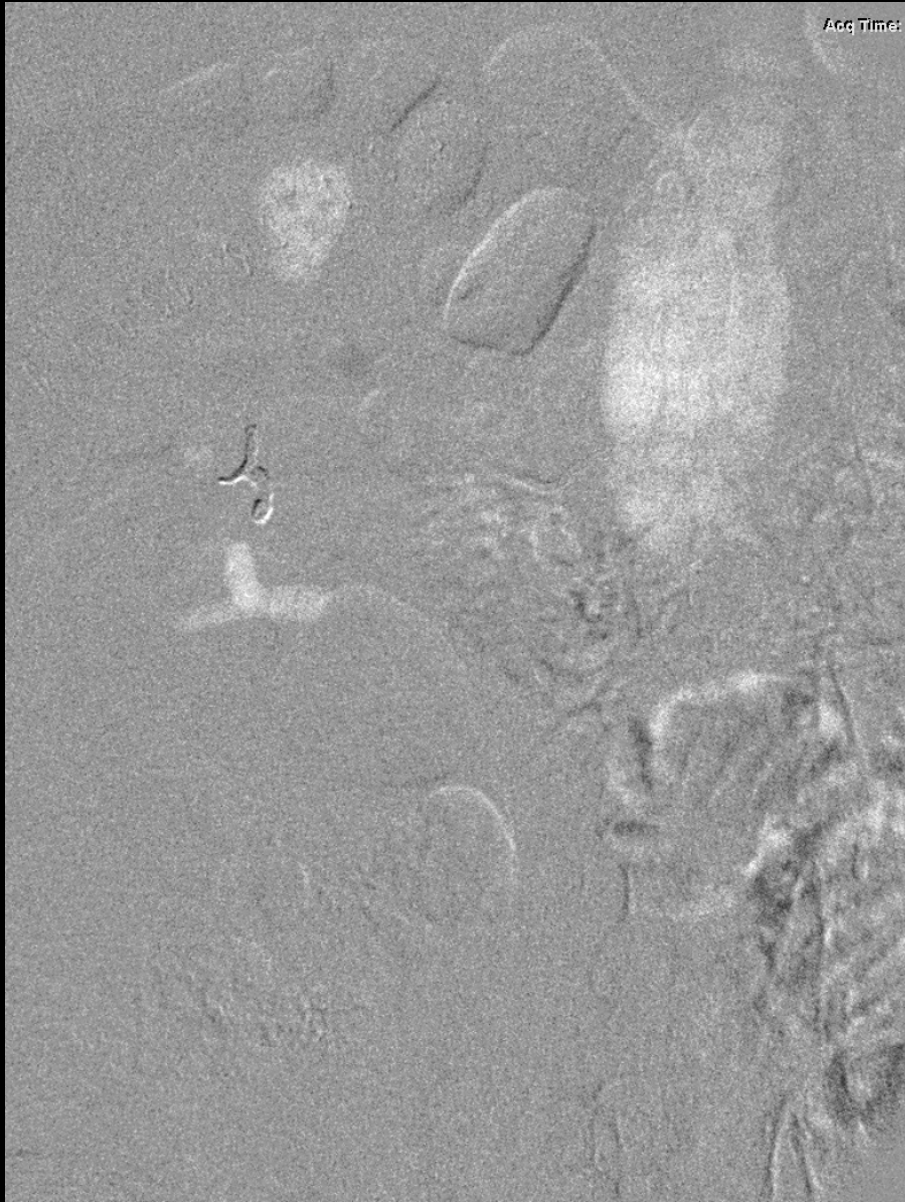
**Renal transplant AVF**



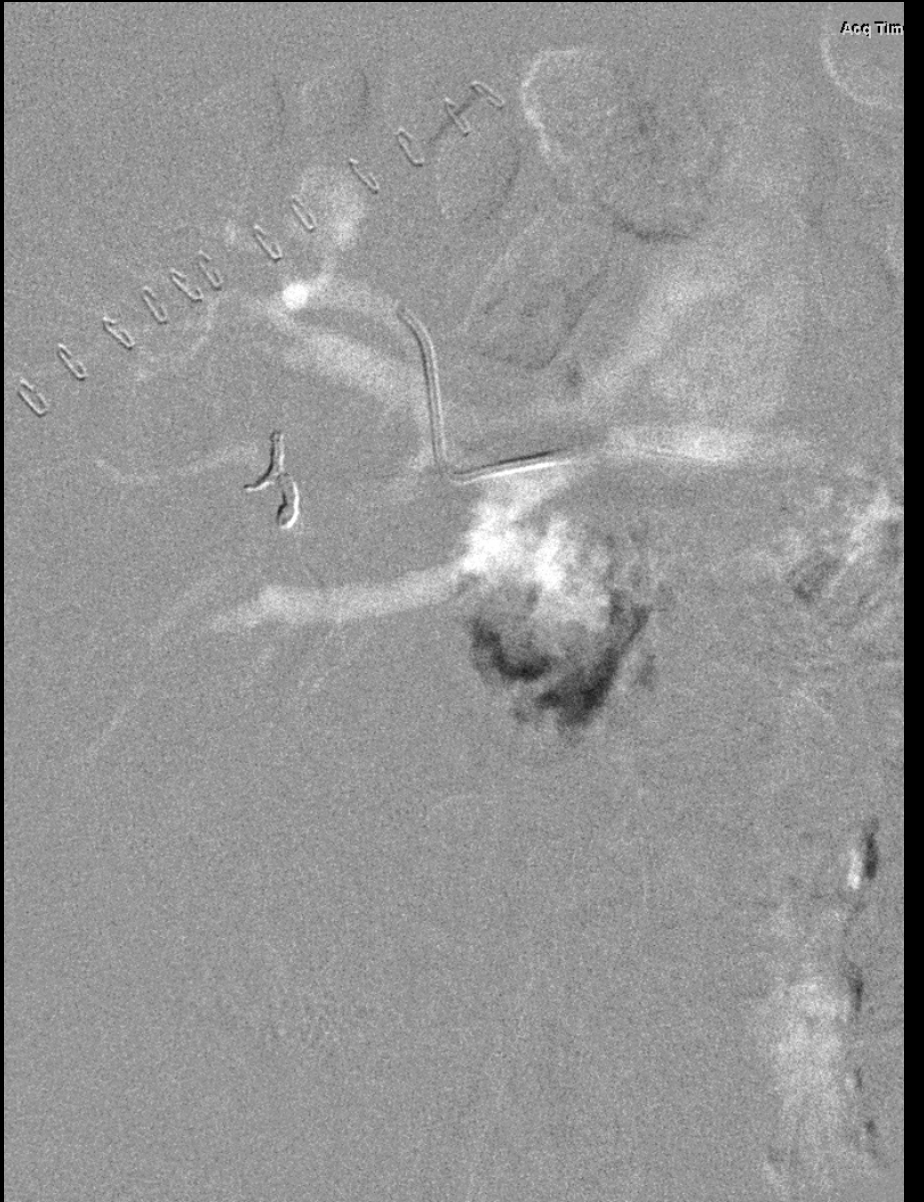
**Renal AVF and bleed post robotic partial nephrectomy not seen with liquid contrast**

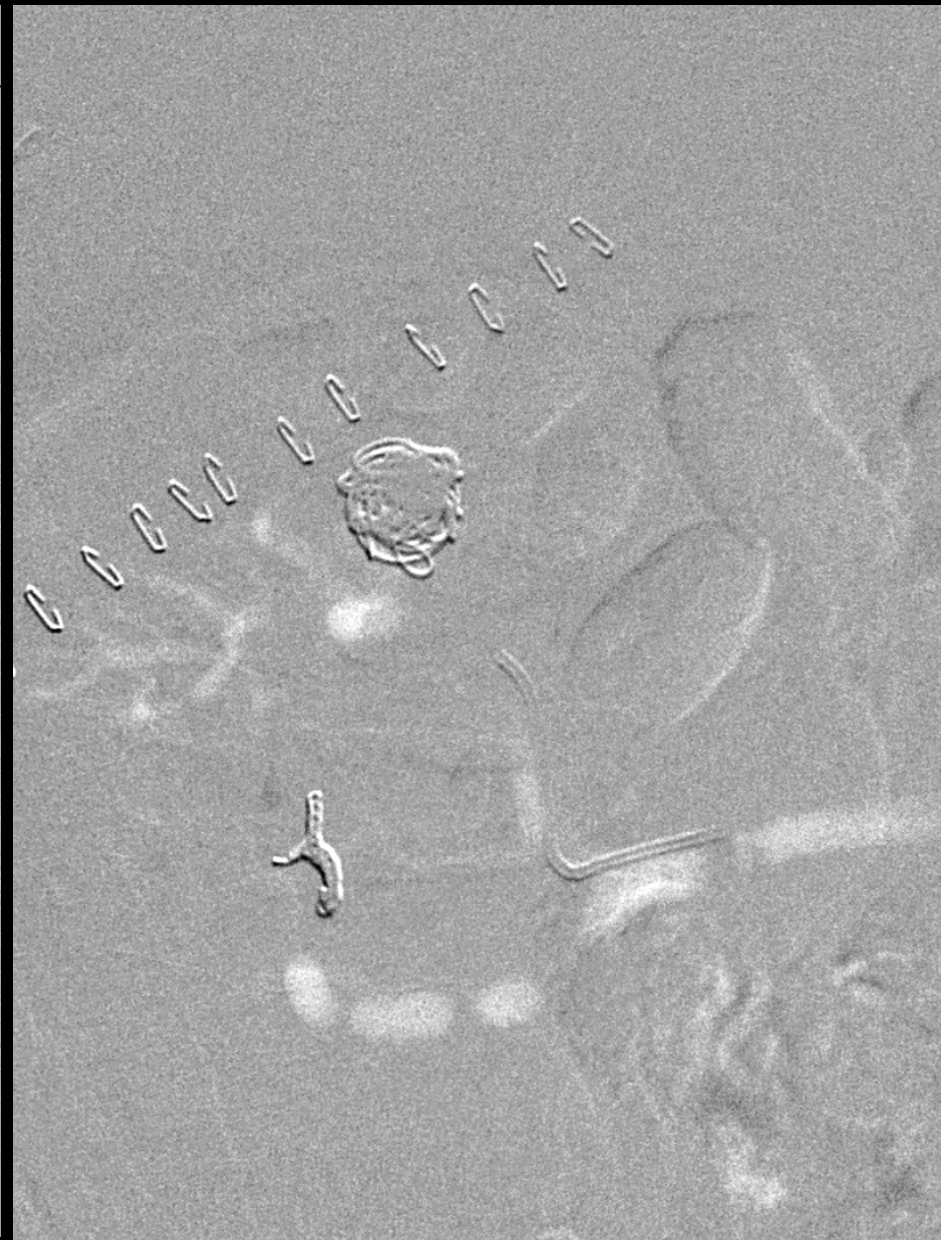
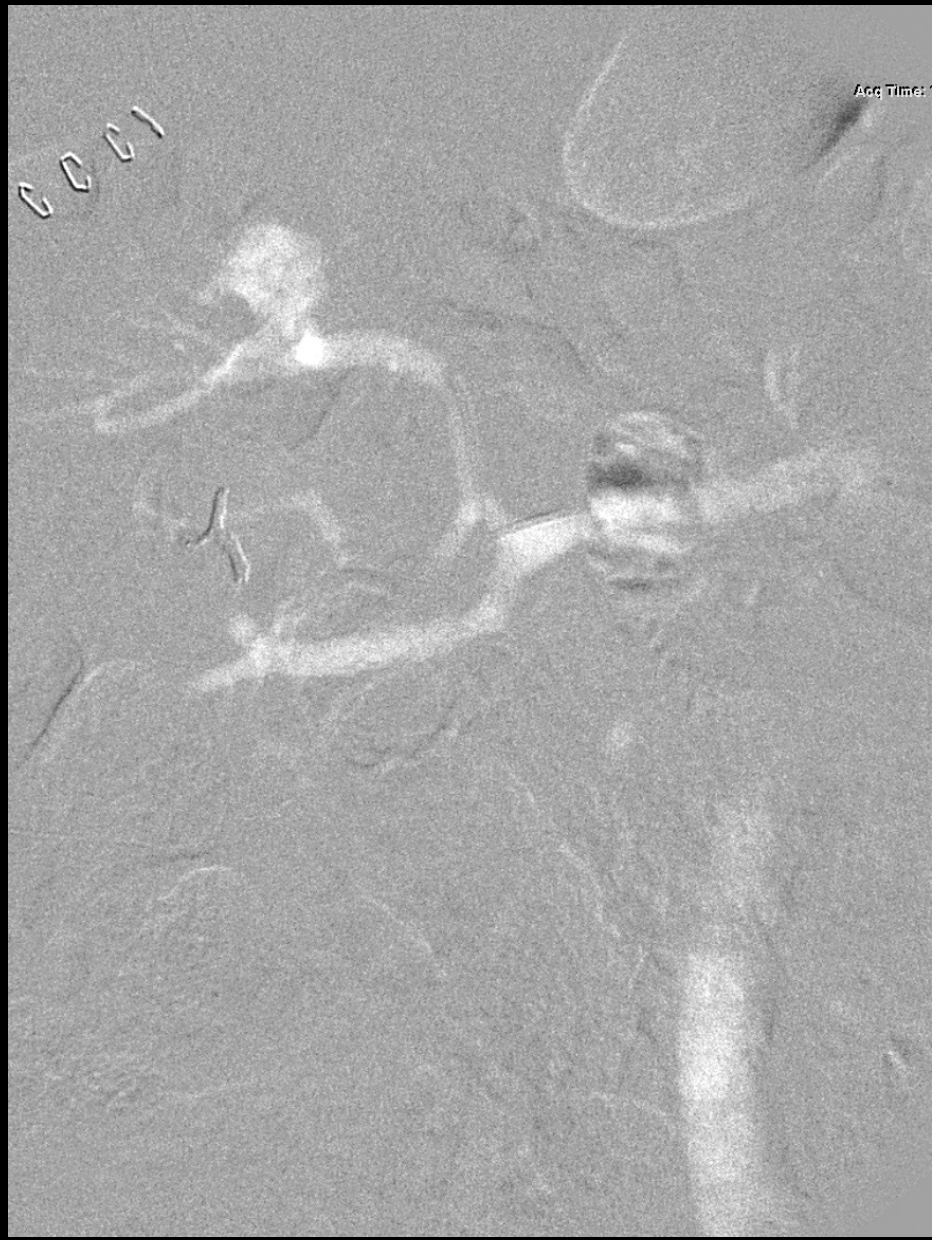


Acq Time

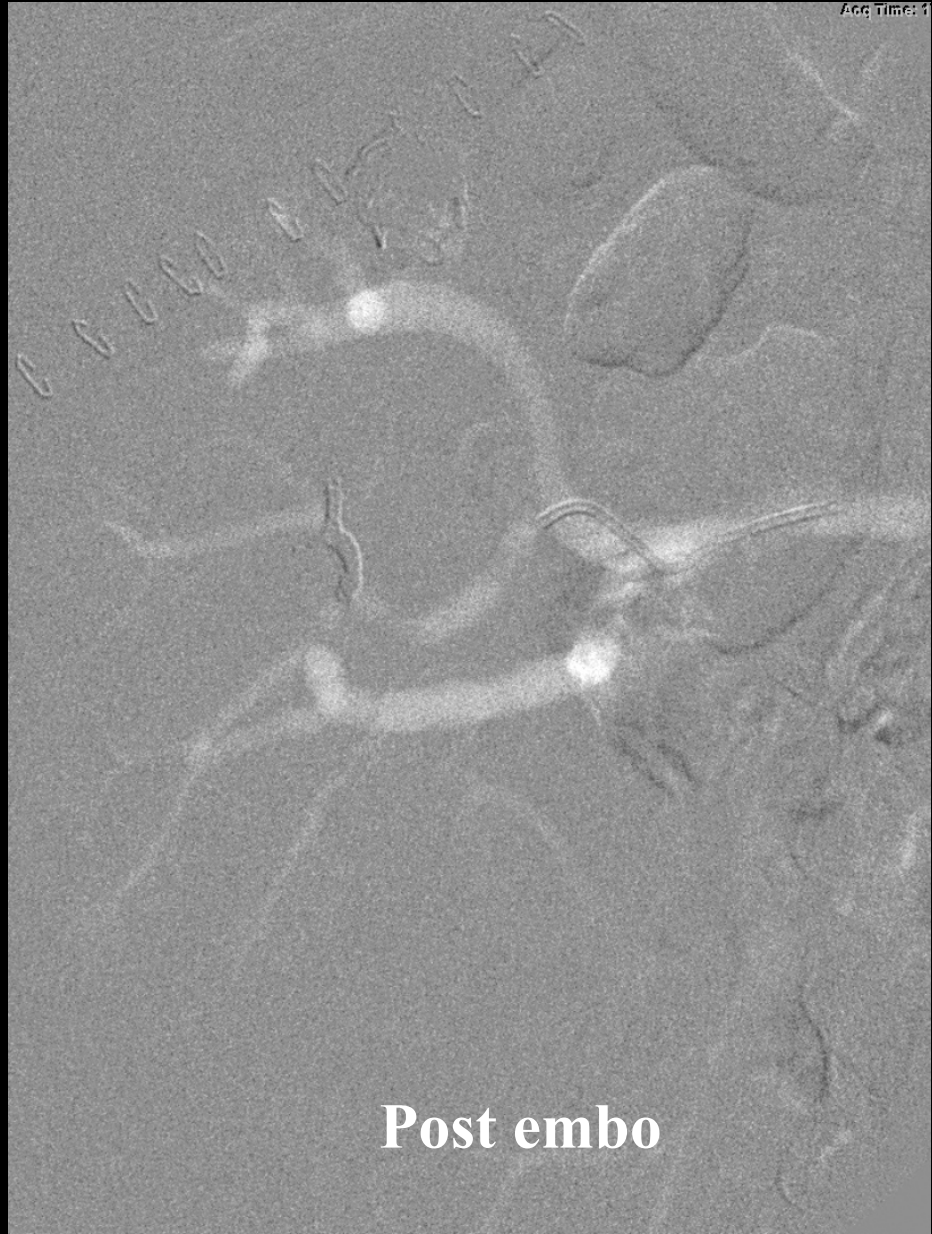

Acq Time

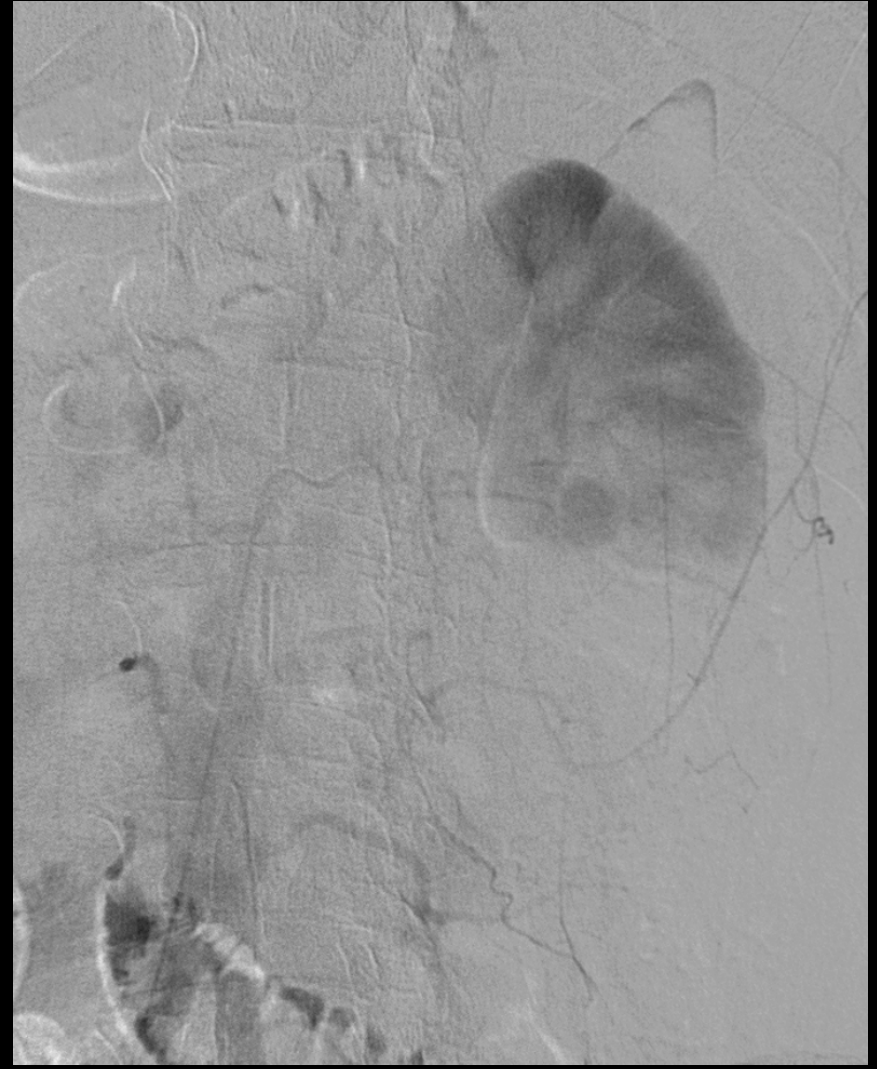
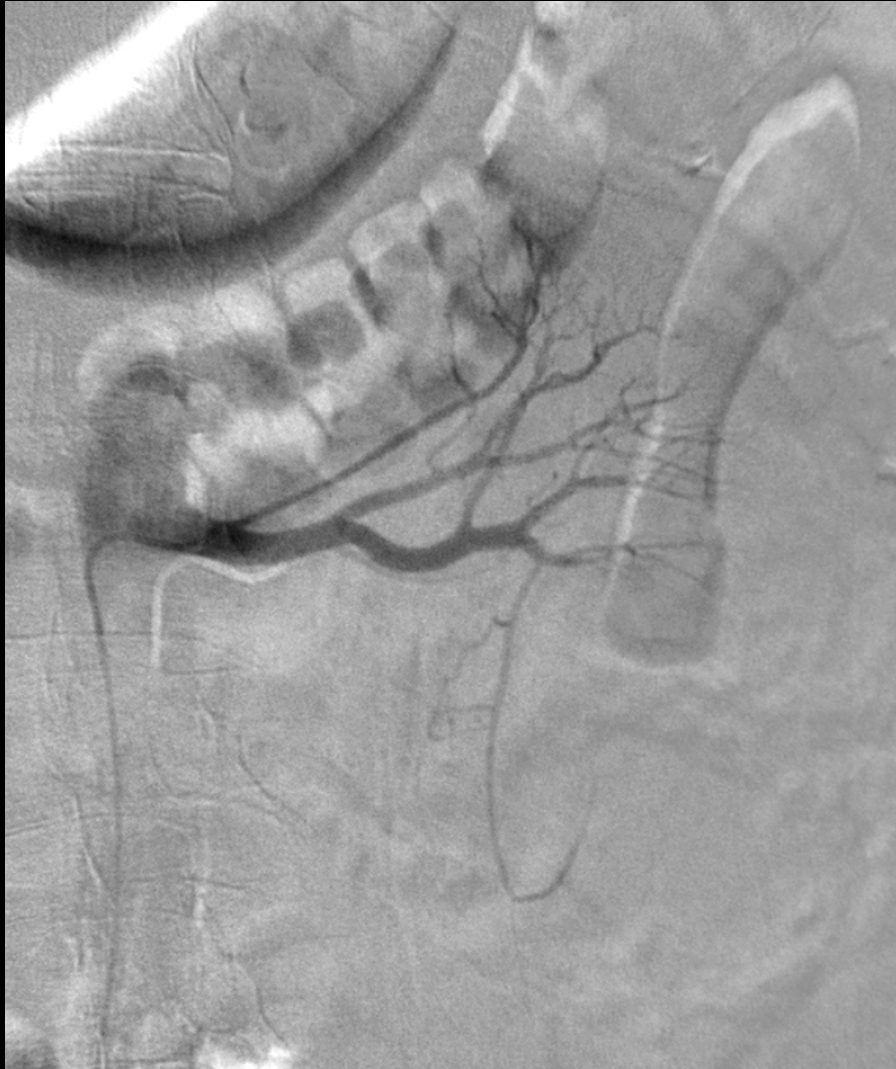


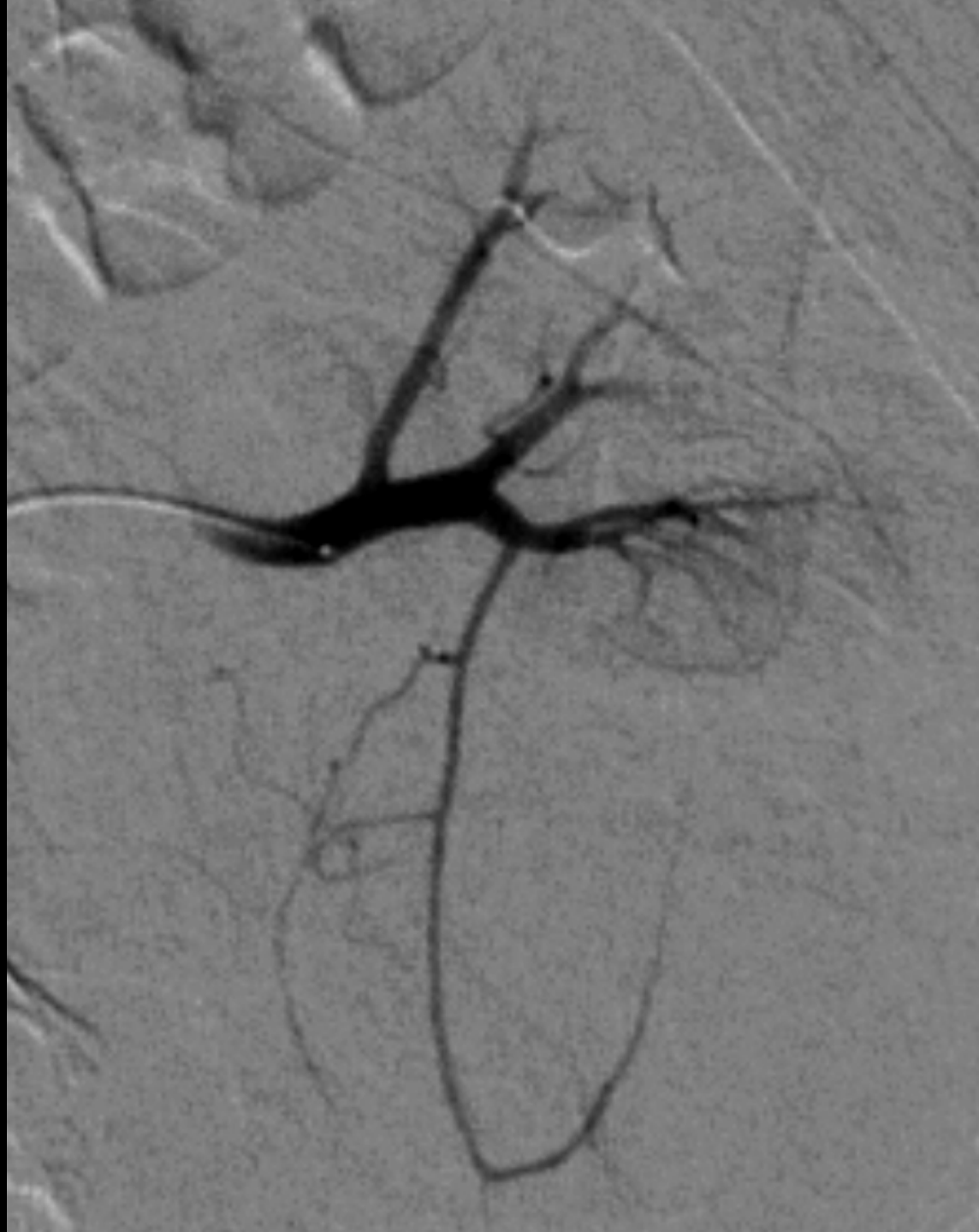Acq Time: 1

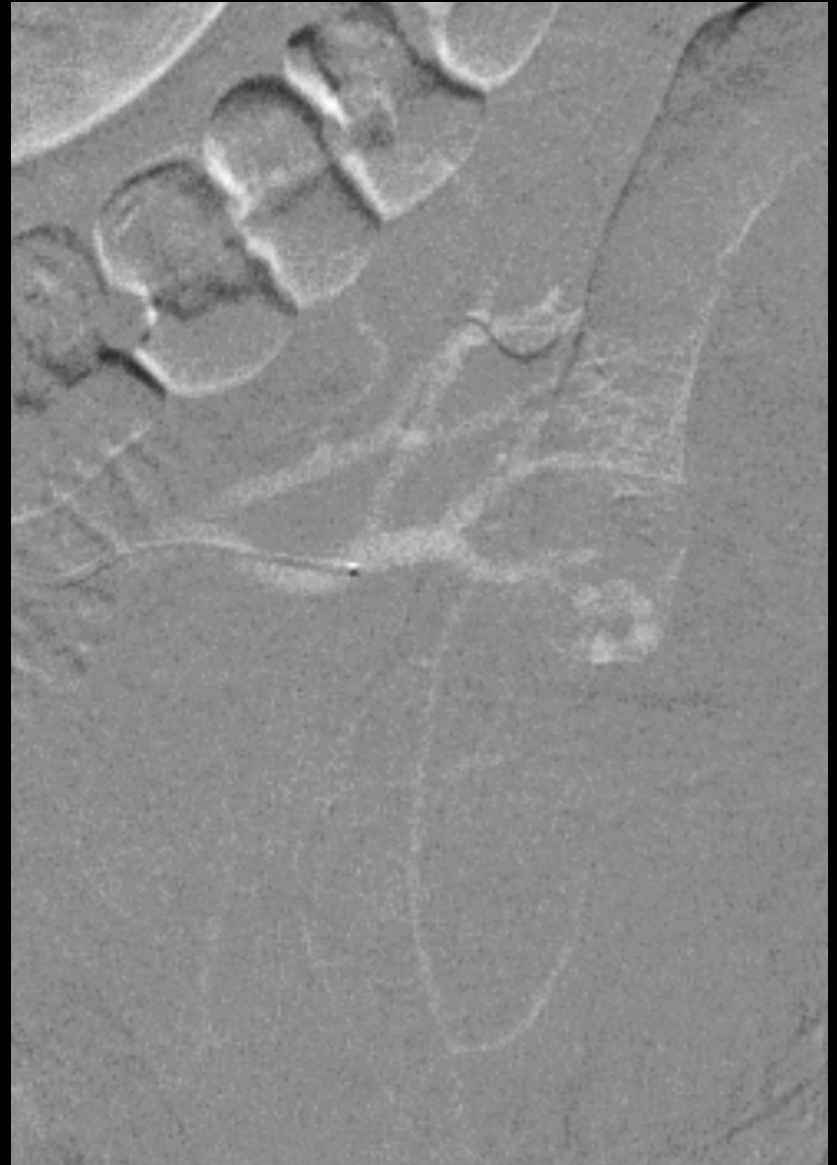
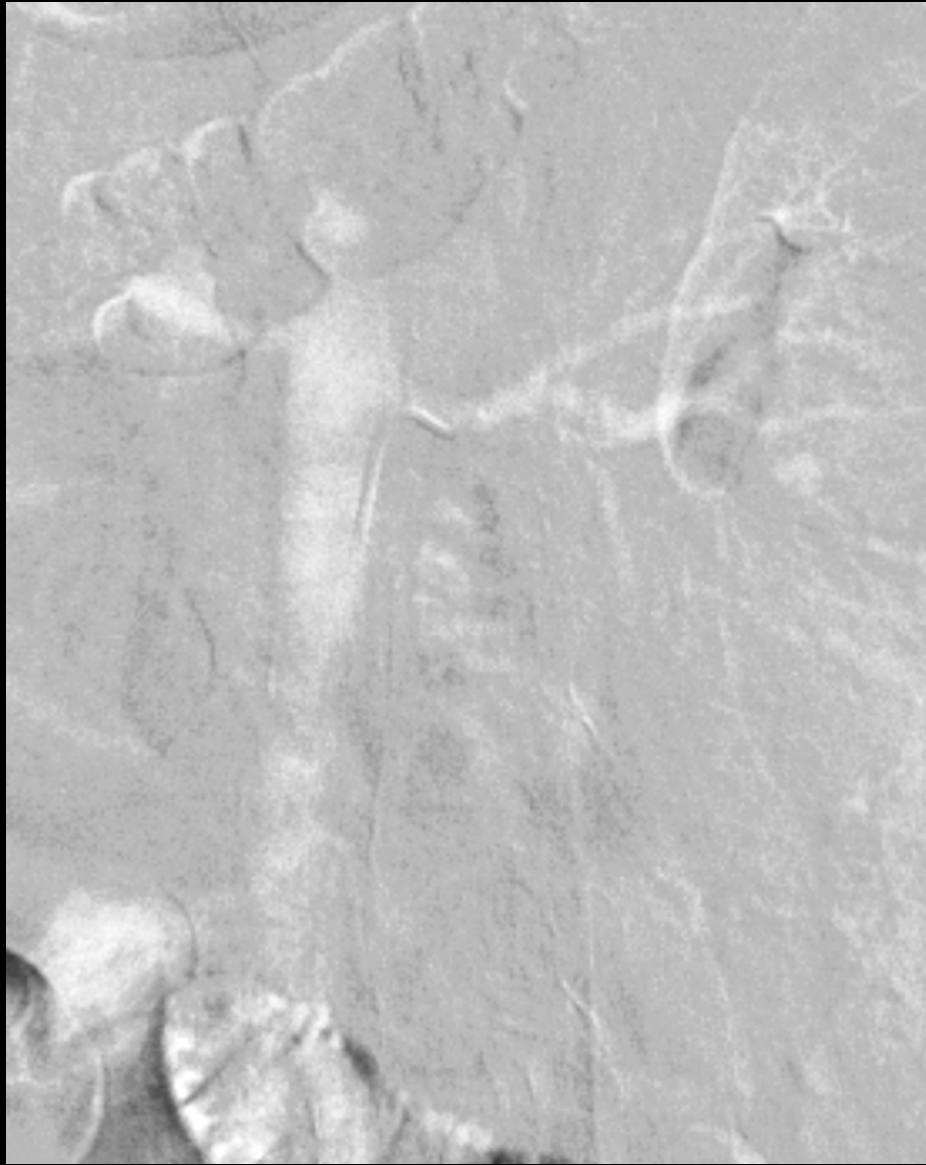
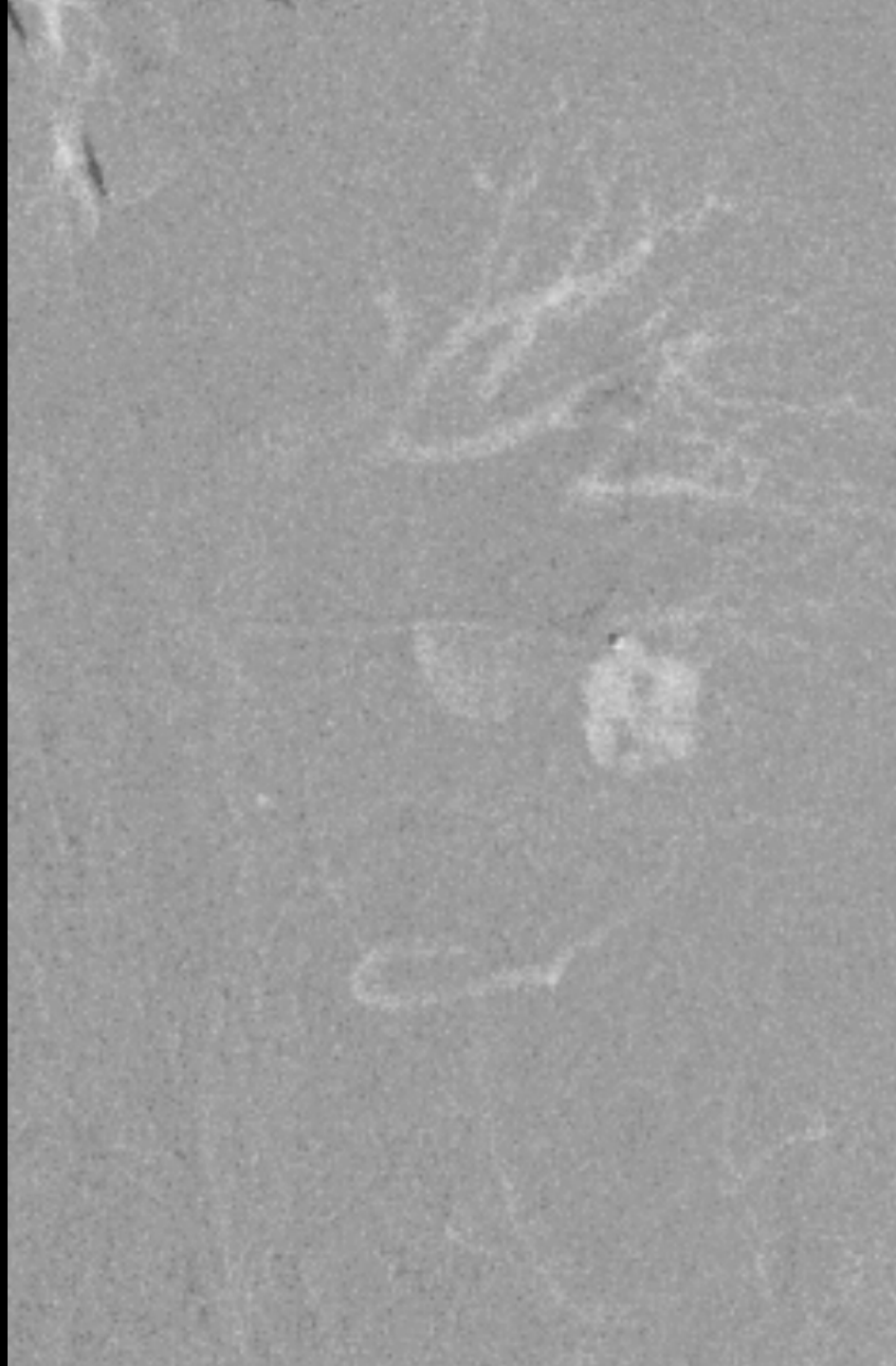**Post embo**

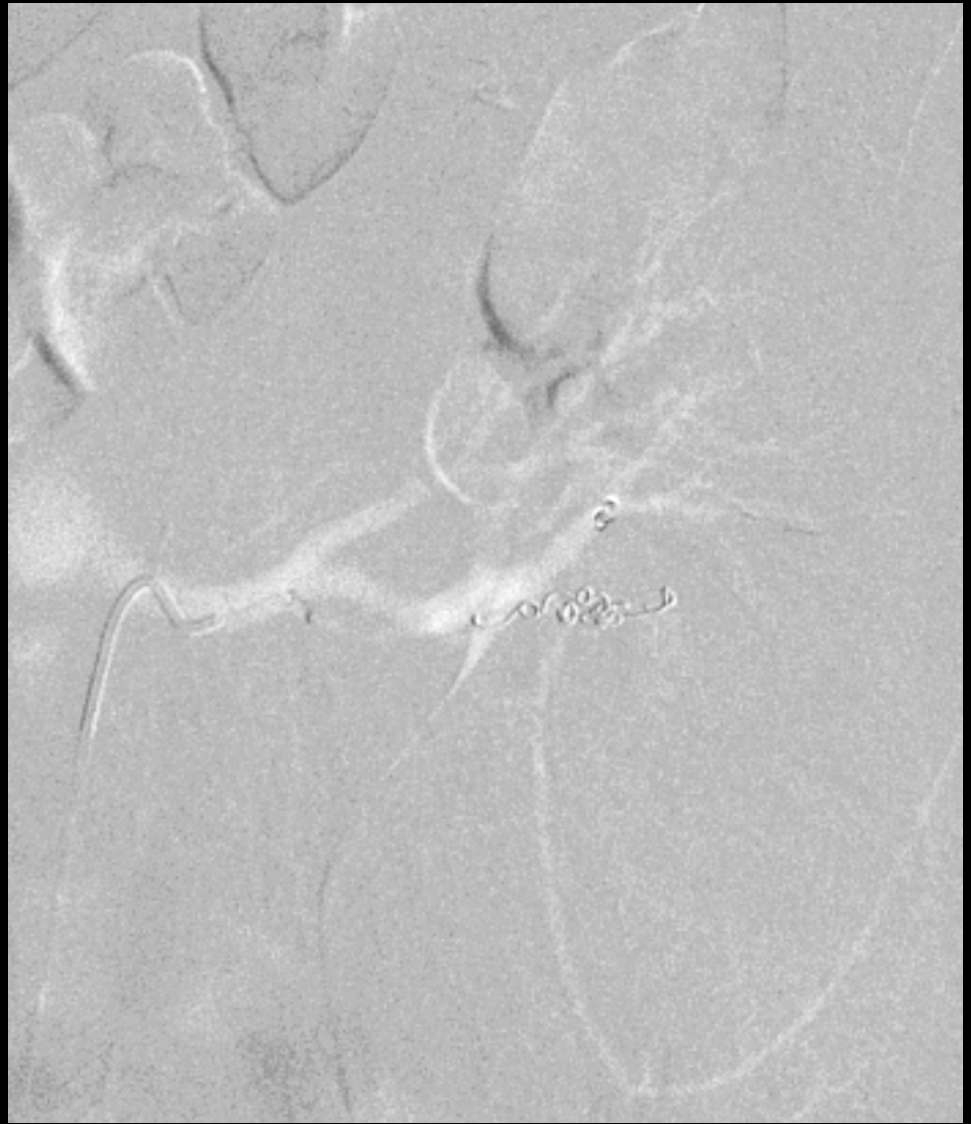
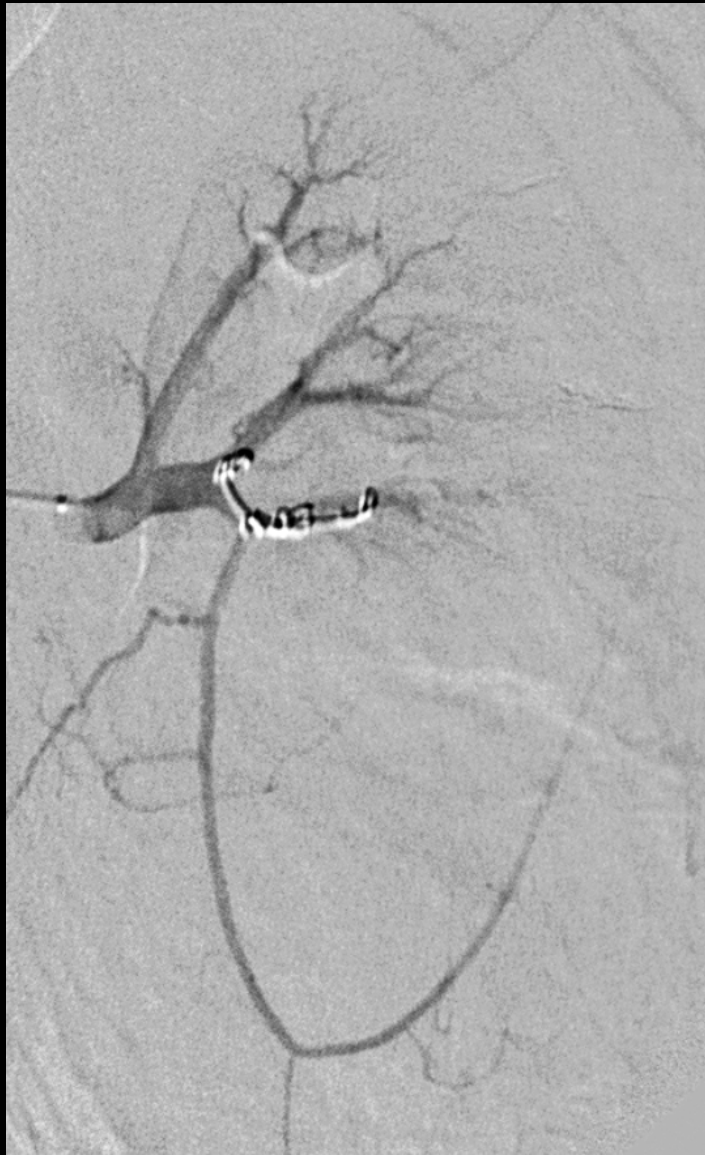

**Bleed post robotic partial nephrectomy not seen with liquid contrast**

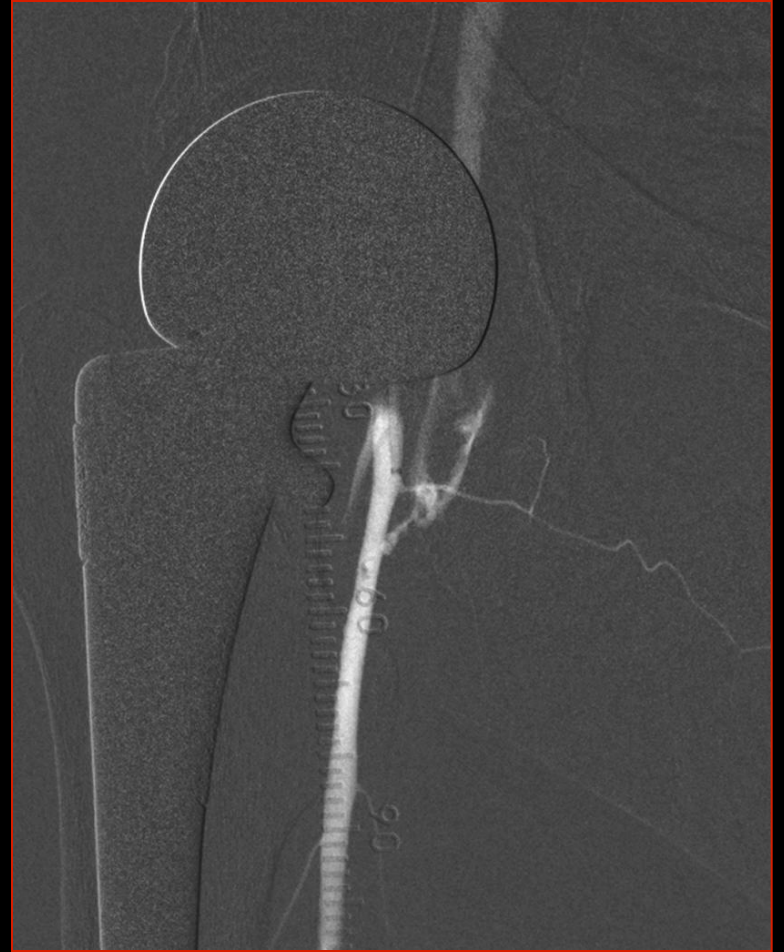
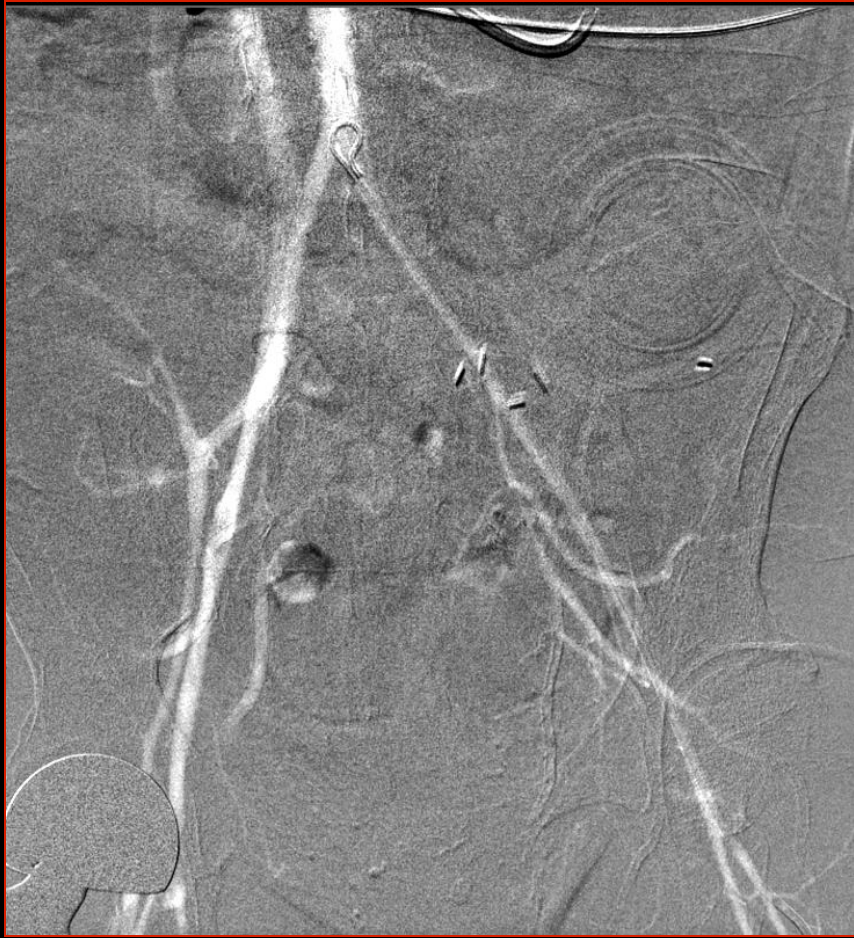



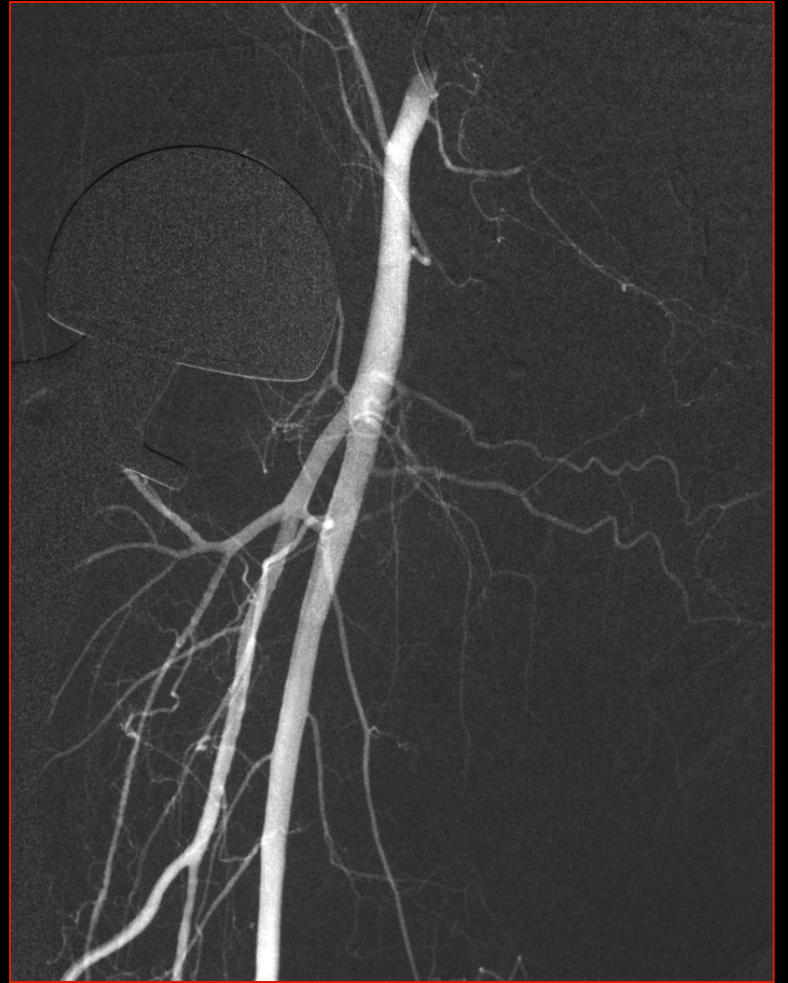
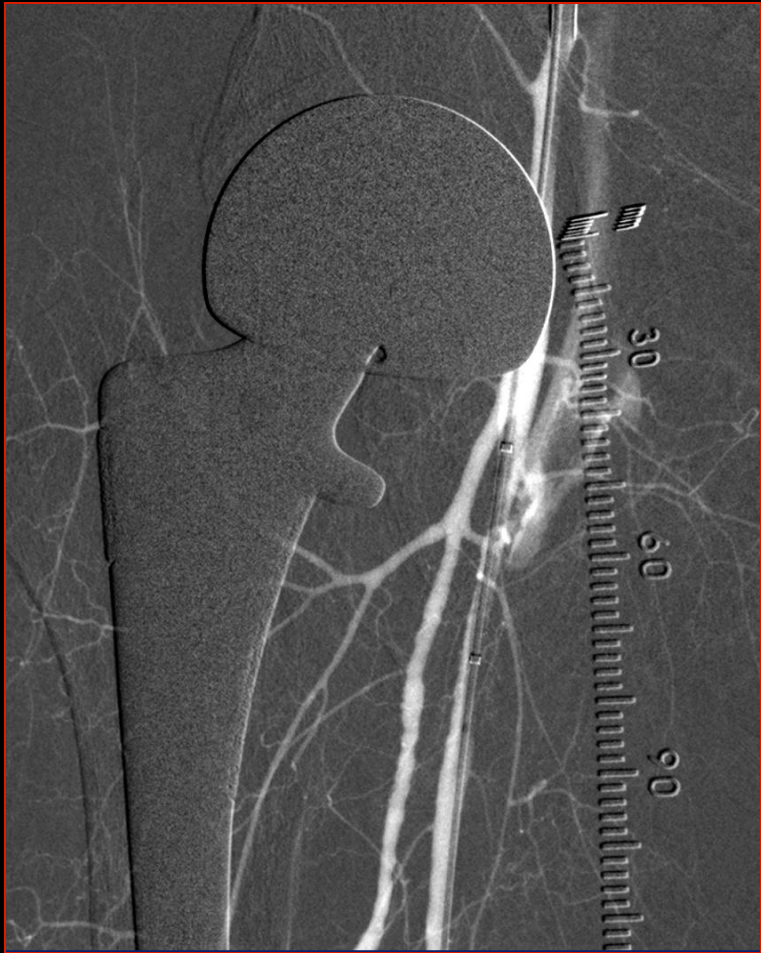



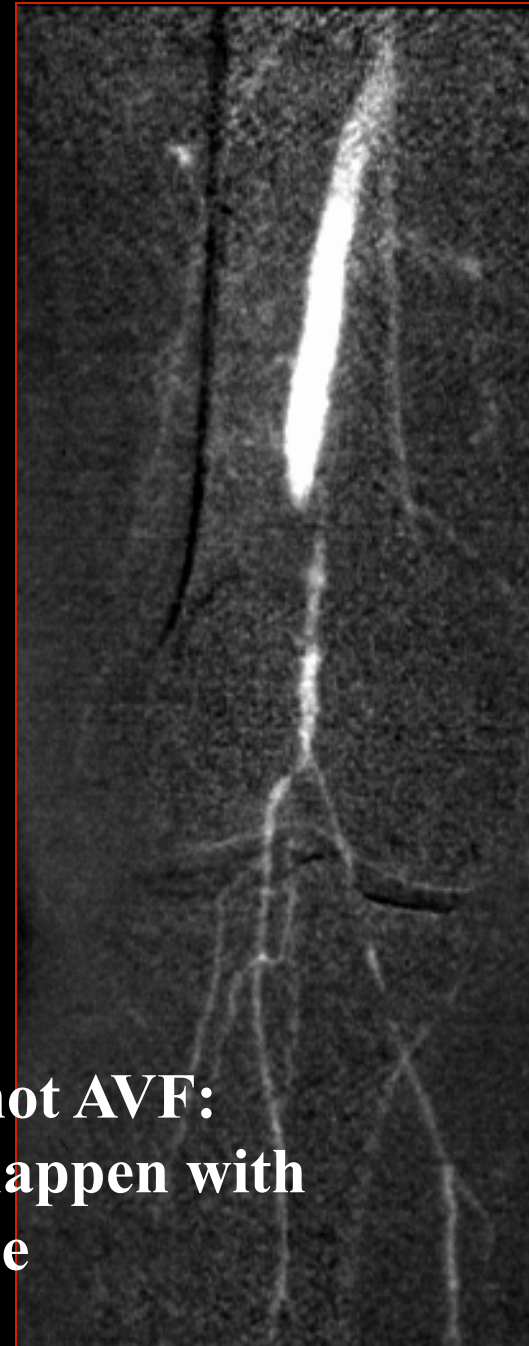
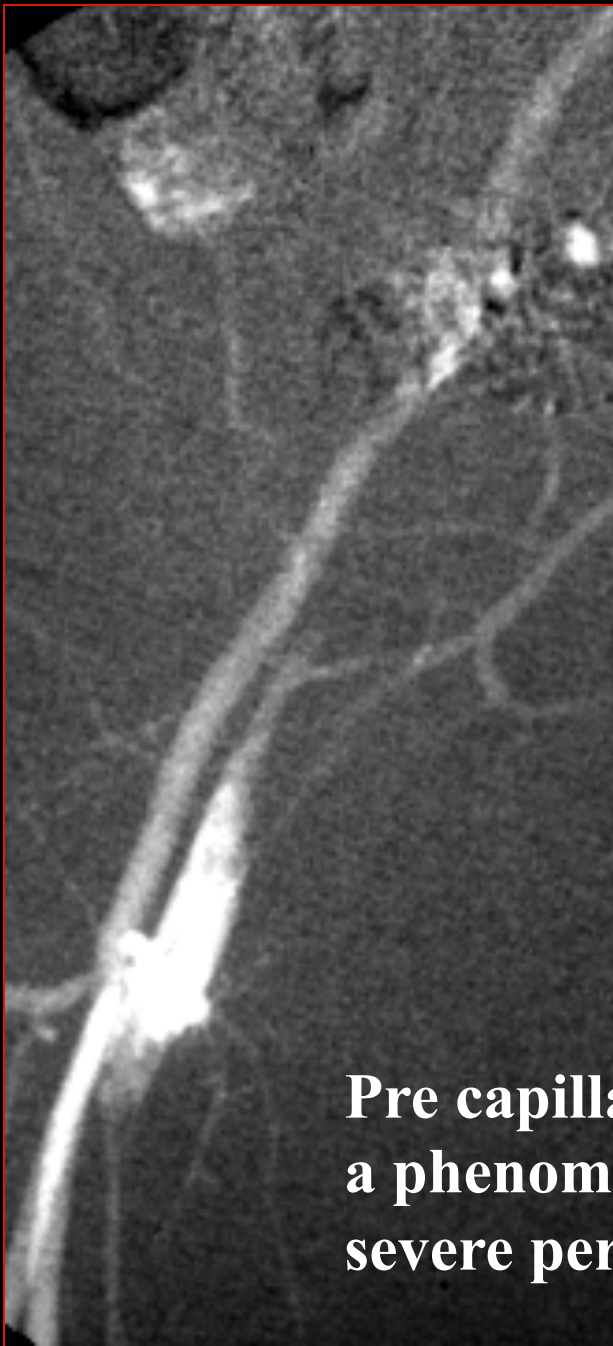**Post embo**



**Post access AVF treated with stent graft**



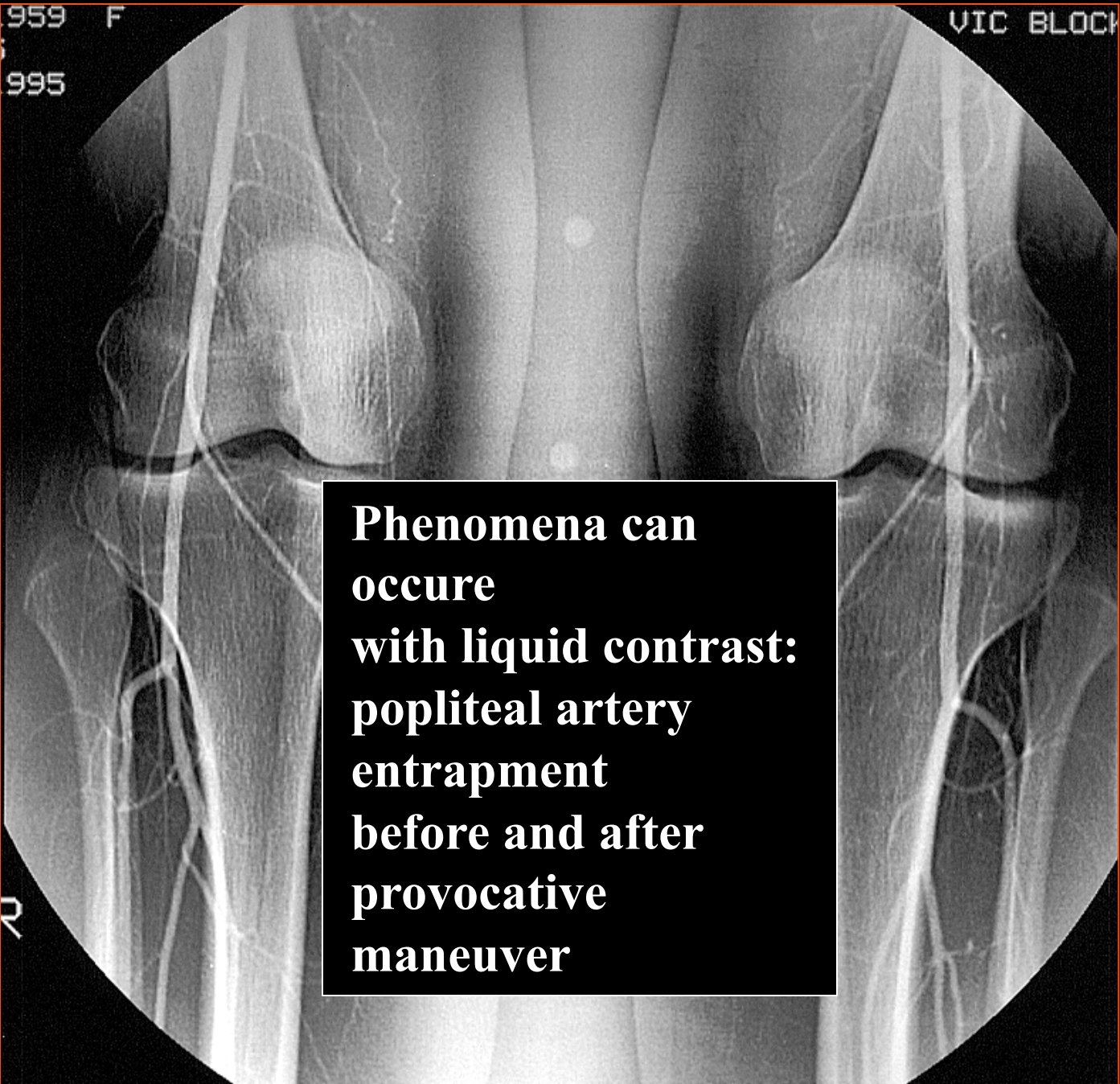


**Pre capillary shunting not AVF:  
a phenomena that can happen with  
severe peripheral disease**

959 F

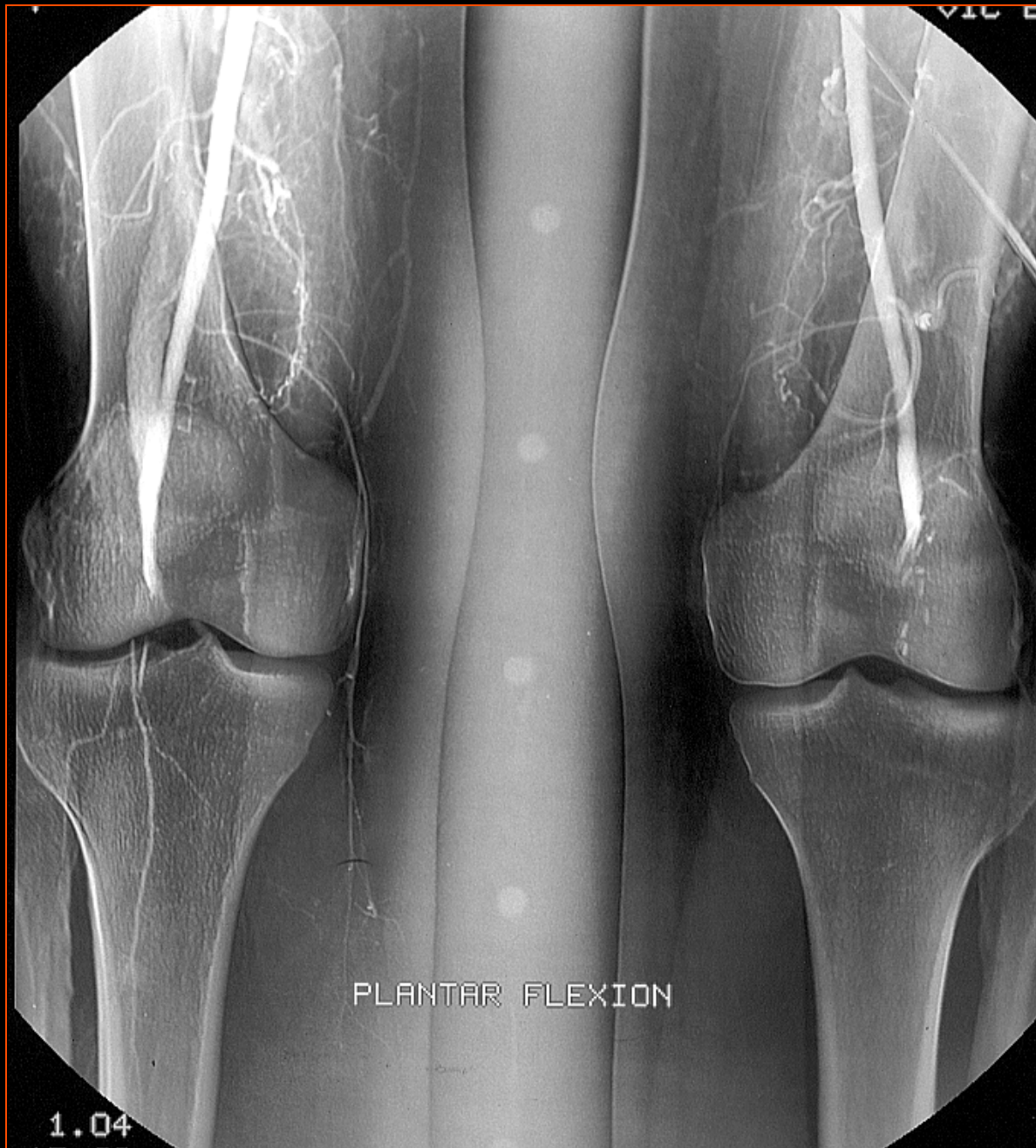VIC BLOC

995



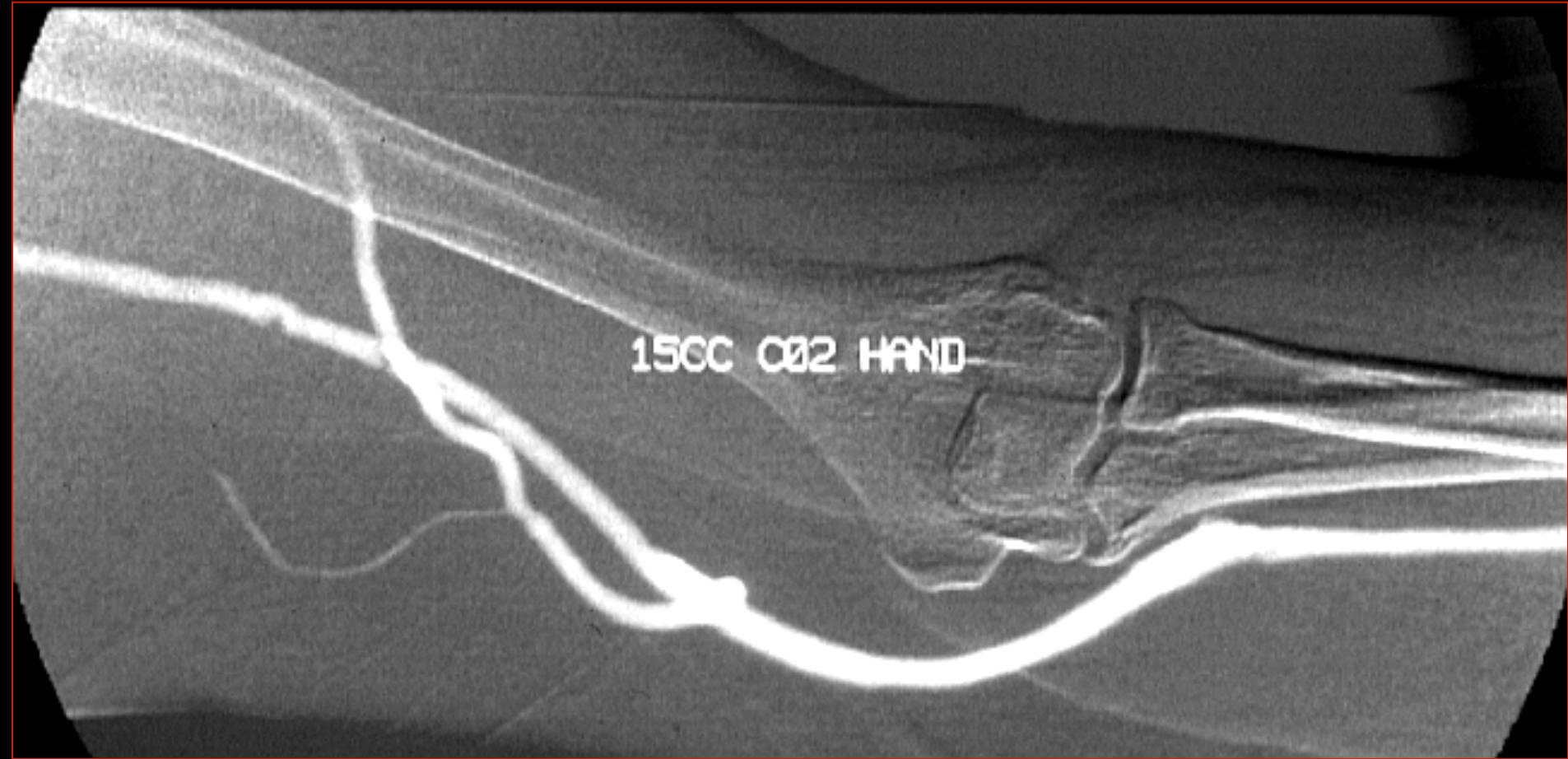**Phenomena can  
occur  
with liquid contrast:  
popliteal artery  
entrapment  
before and after  
provocative  
maneuver**

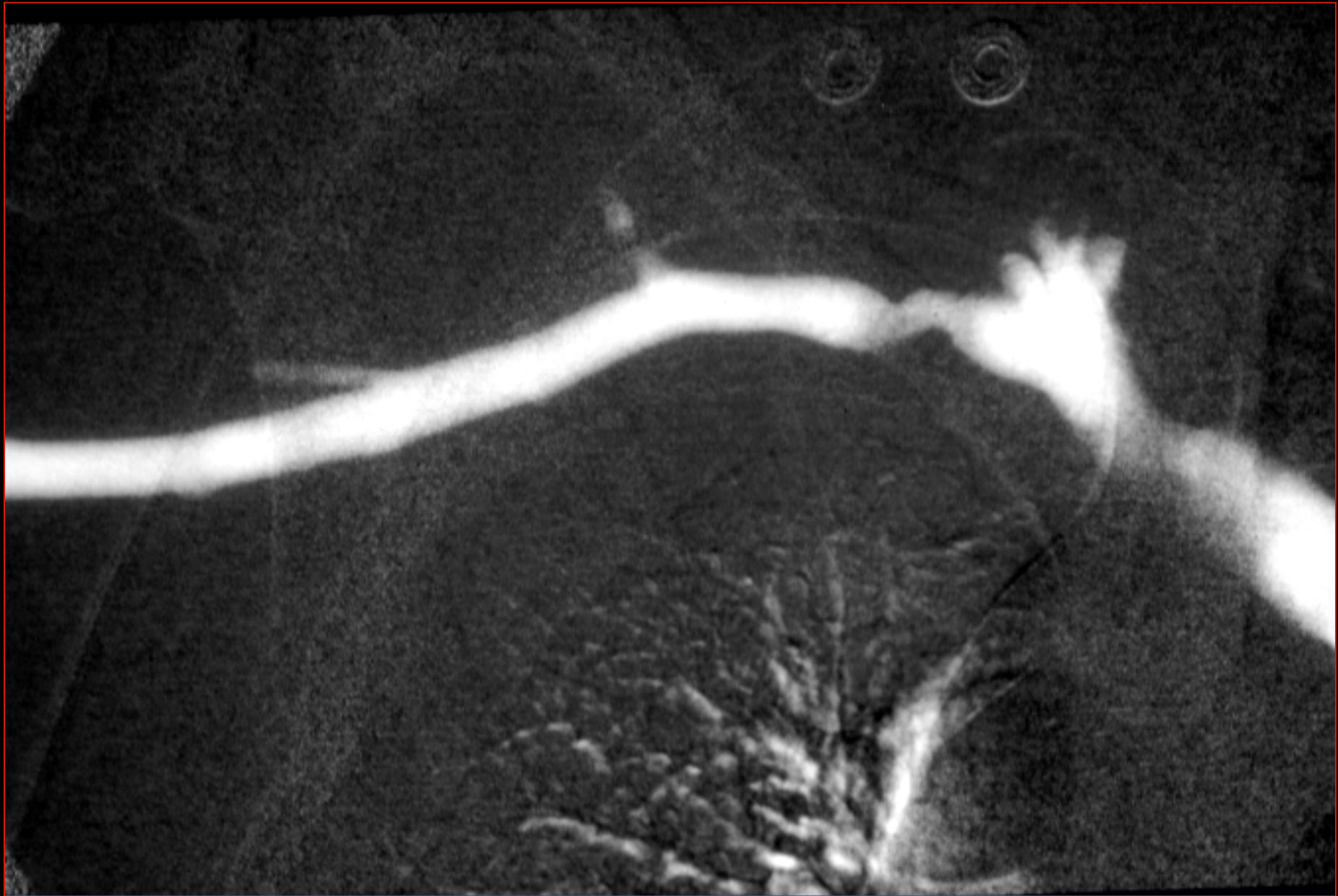R

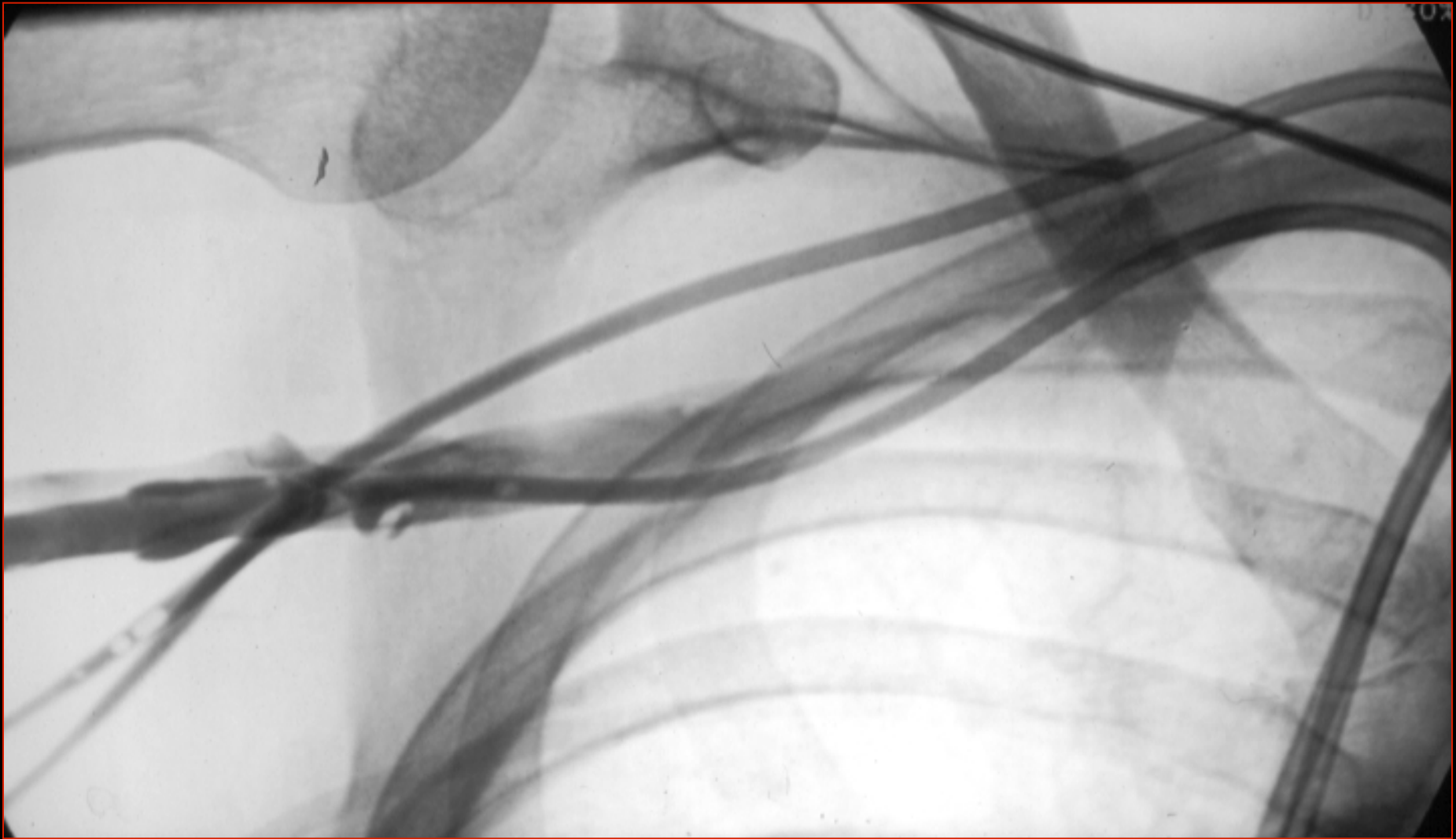


# **VENOUS DX & TREATMENT**

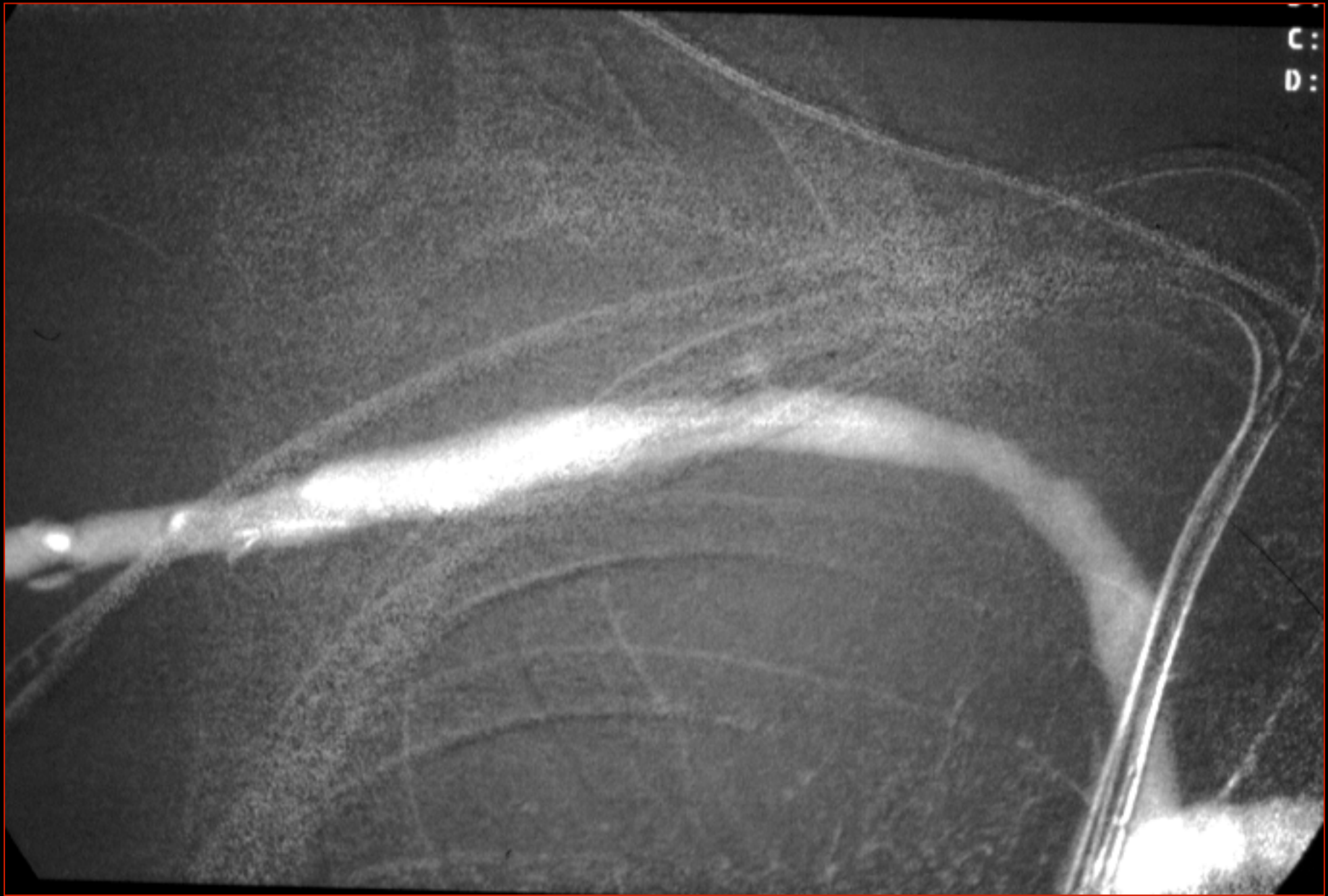- **Slow gentle injection of 15-30 cc to avoid pain**
- **Stretch receptors more sensitive to dilation than artery**
- **CO<sub>2</sub> is not diluted by blood and can opacify central veins more readily from a peripheral approach**
- **Venous PTA and stent placement**
- **IVC filter placement**
- **Ultra fine needle splenoportography**
- **Portal vein access**



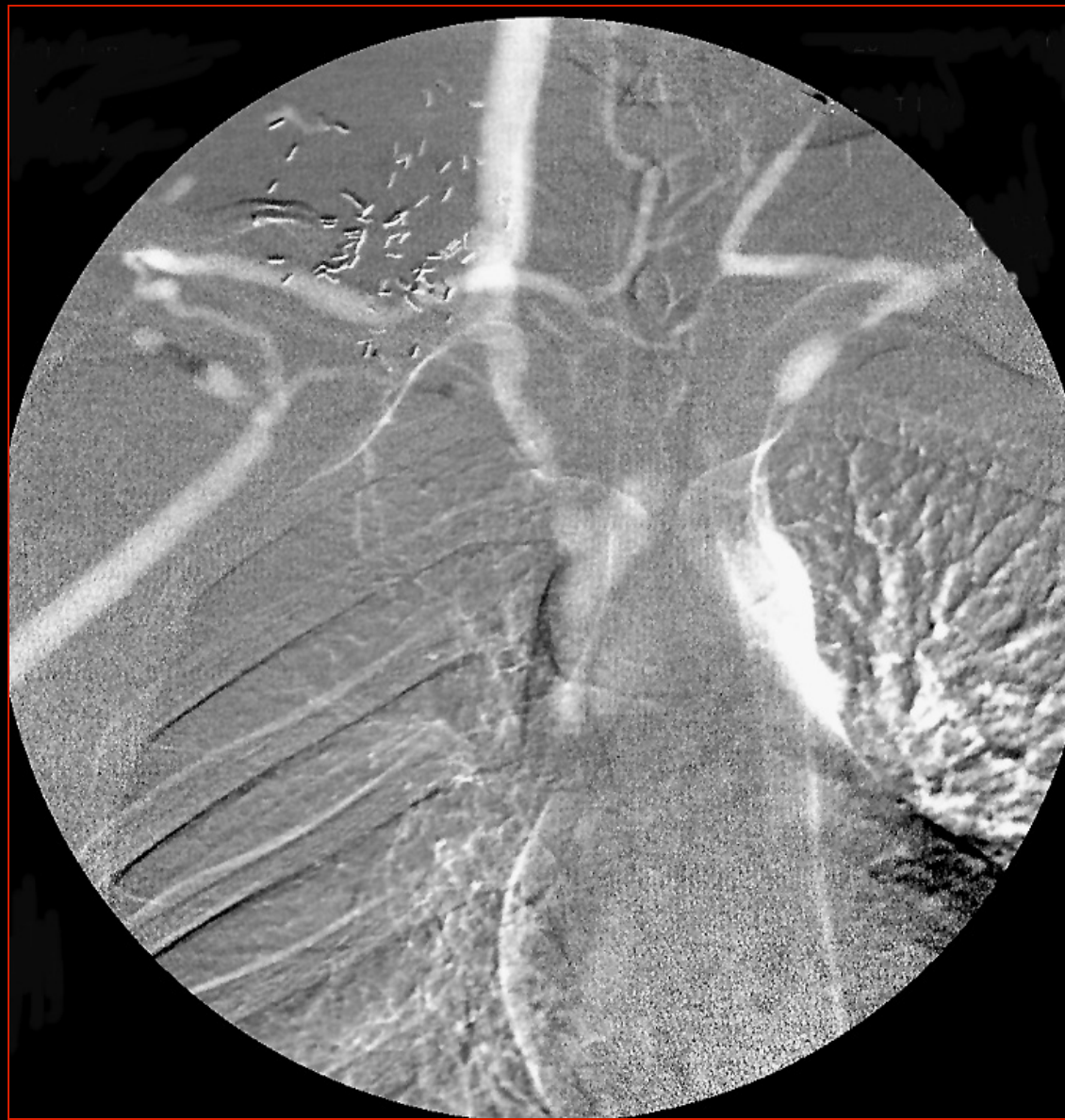



**Comparison of diluted liquid contrast from antecubital access  
vs CO<sub>2</sub> using small IV**



C:  
D:



**Low viscosity of CO<sub>2</sub> crosses midline to identify collateral again  
using small peripheral (hand vein) access**

# **SIMON'S UNBREAKABLE RULES OF DIALYSIS**

**#1 – Every catheter will occlude or become infected**

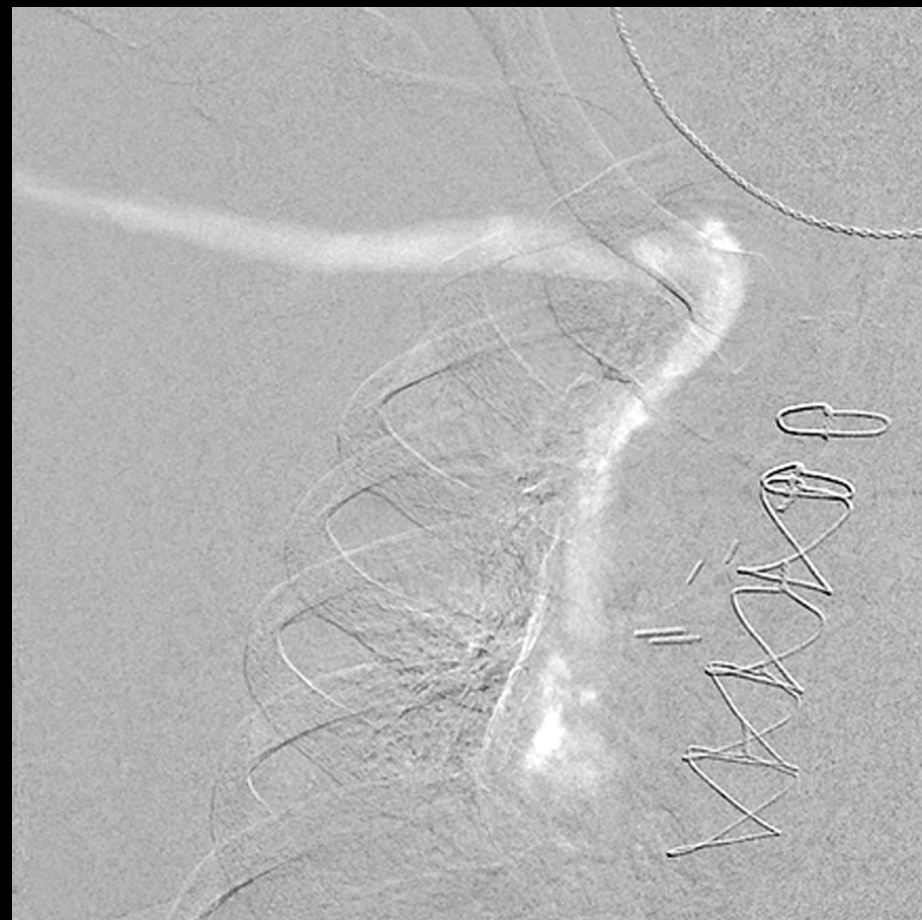
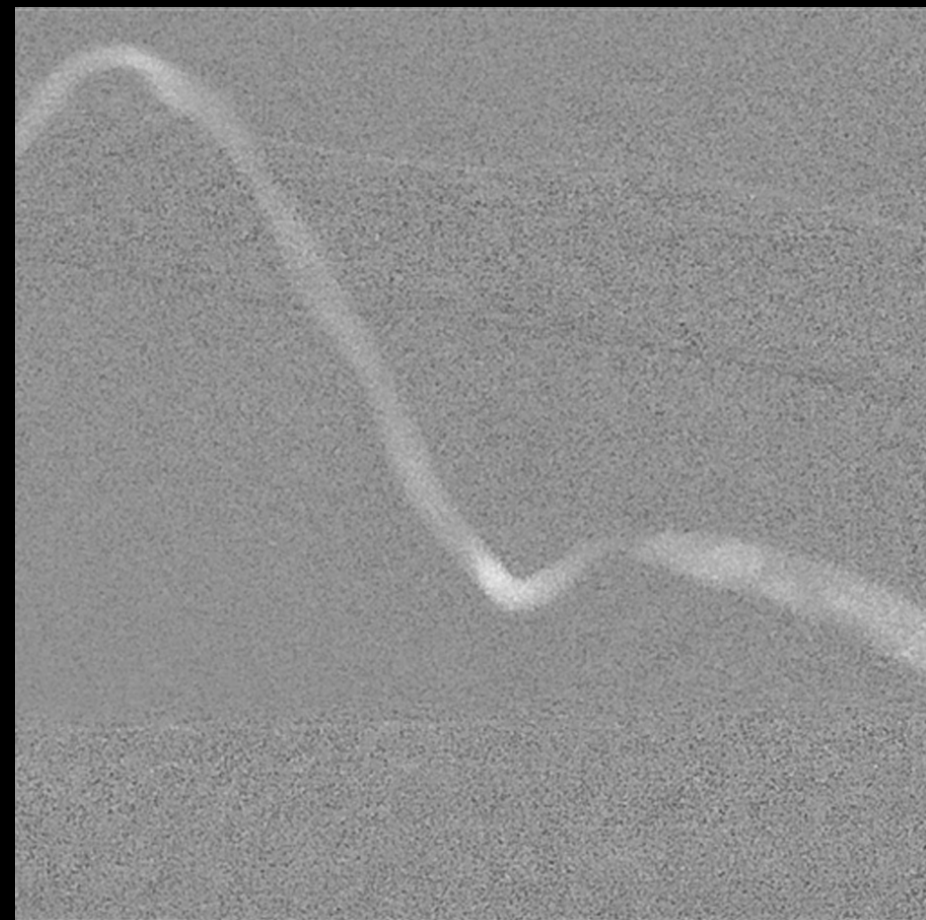
**# 2- Every Graft will stenose, occlude, fail, or  
become infected**

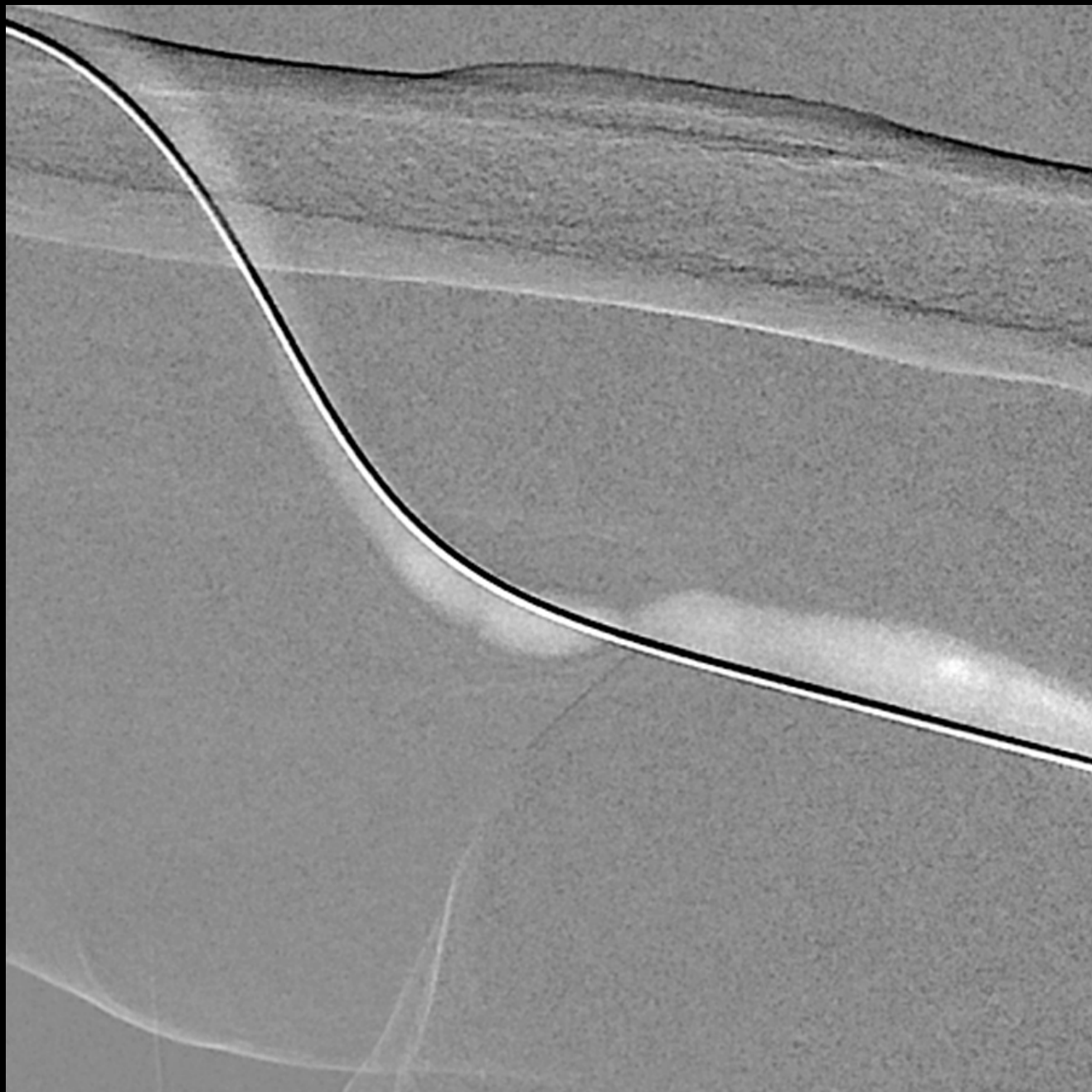**# 3- Every Fistula will stenose, occlude, or fail**

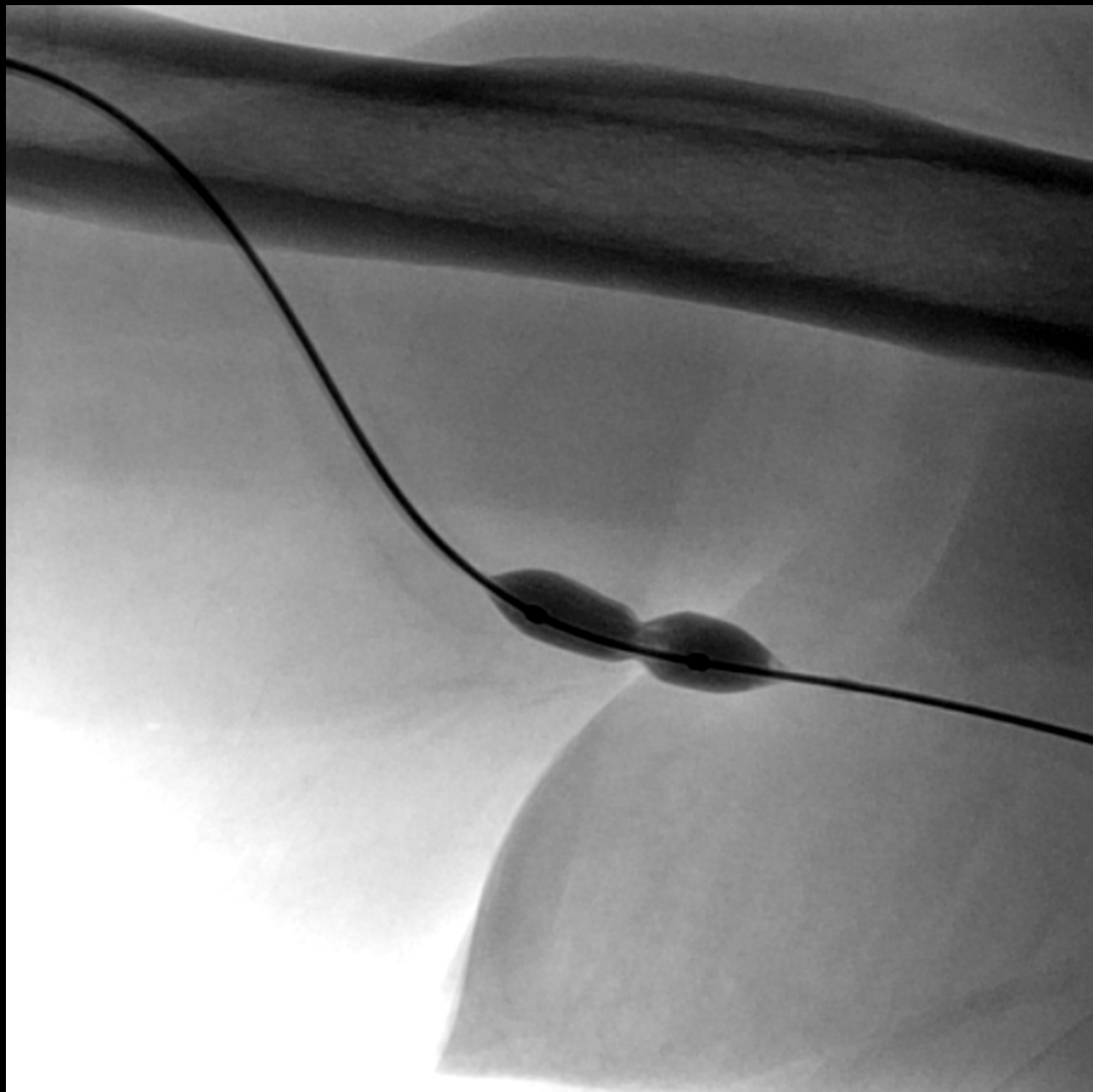
**#4 – Transplants don't last forever**

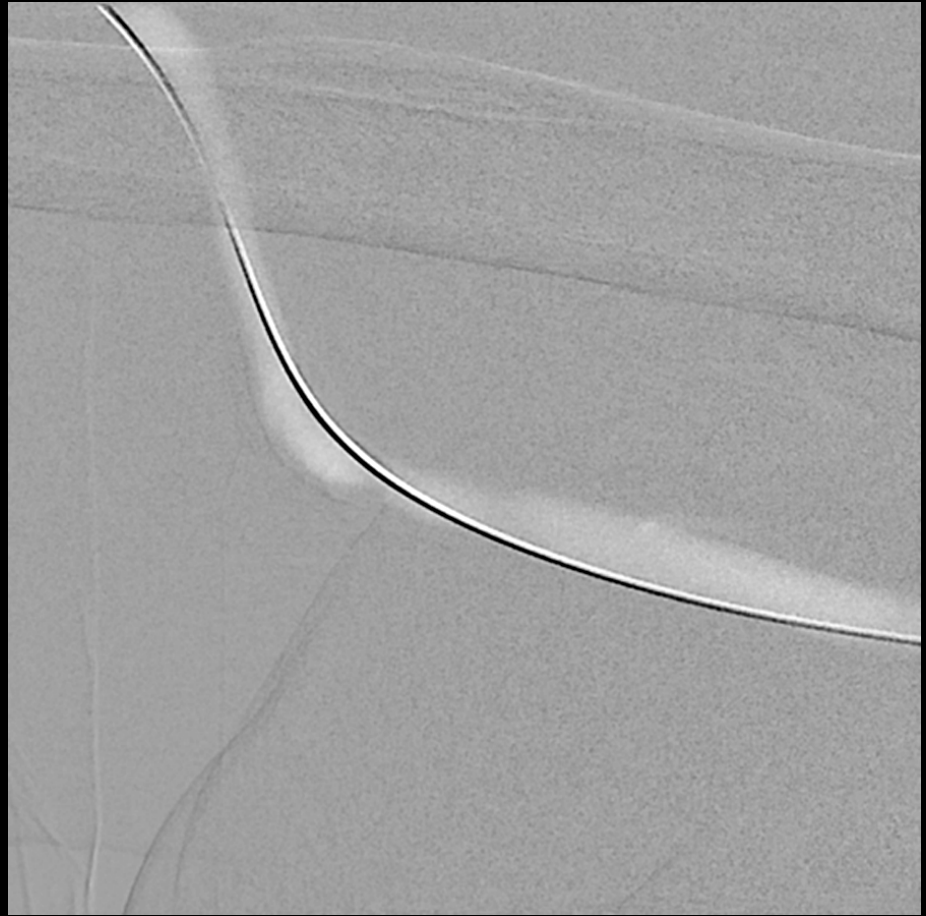# **RENAL FAILURE PATIENT ON DIALYSIS**

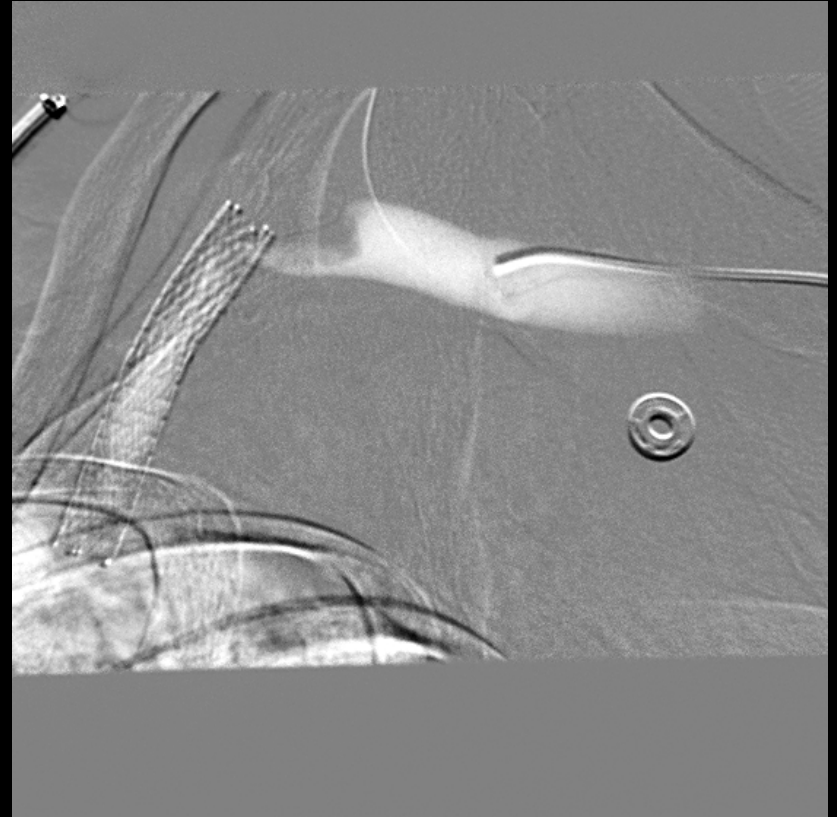
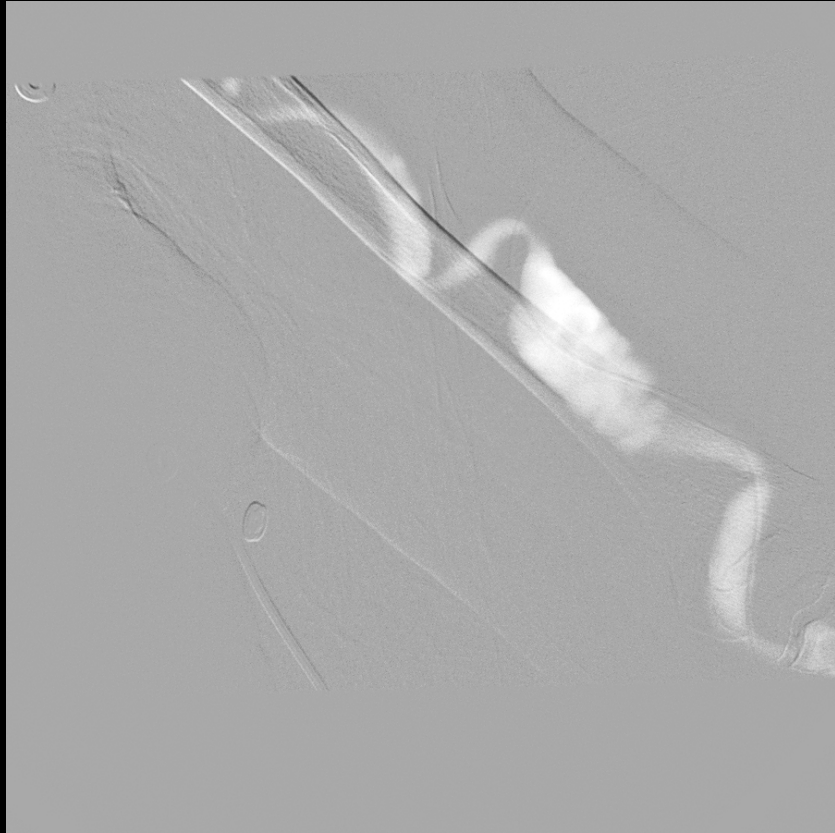
- **+ Advantage of maintaining of some renal function**
- **Patients are much easier to manage from their renal failure if they have any kidney function maintained**
- **If access is lost they tend to tolerate a missed dialysis much better**
- **Fluid and potassium management is much easier in this group of patients.**
- **A decrease in GFR of 1 increases mortality by 12%**

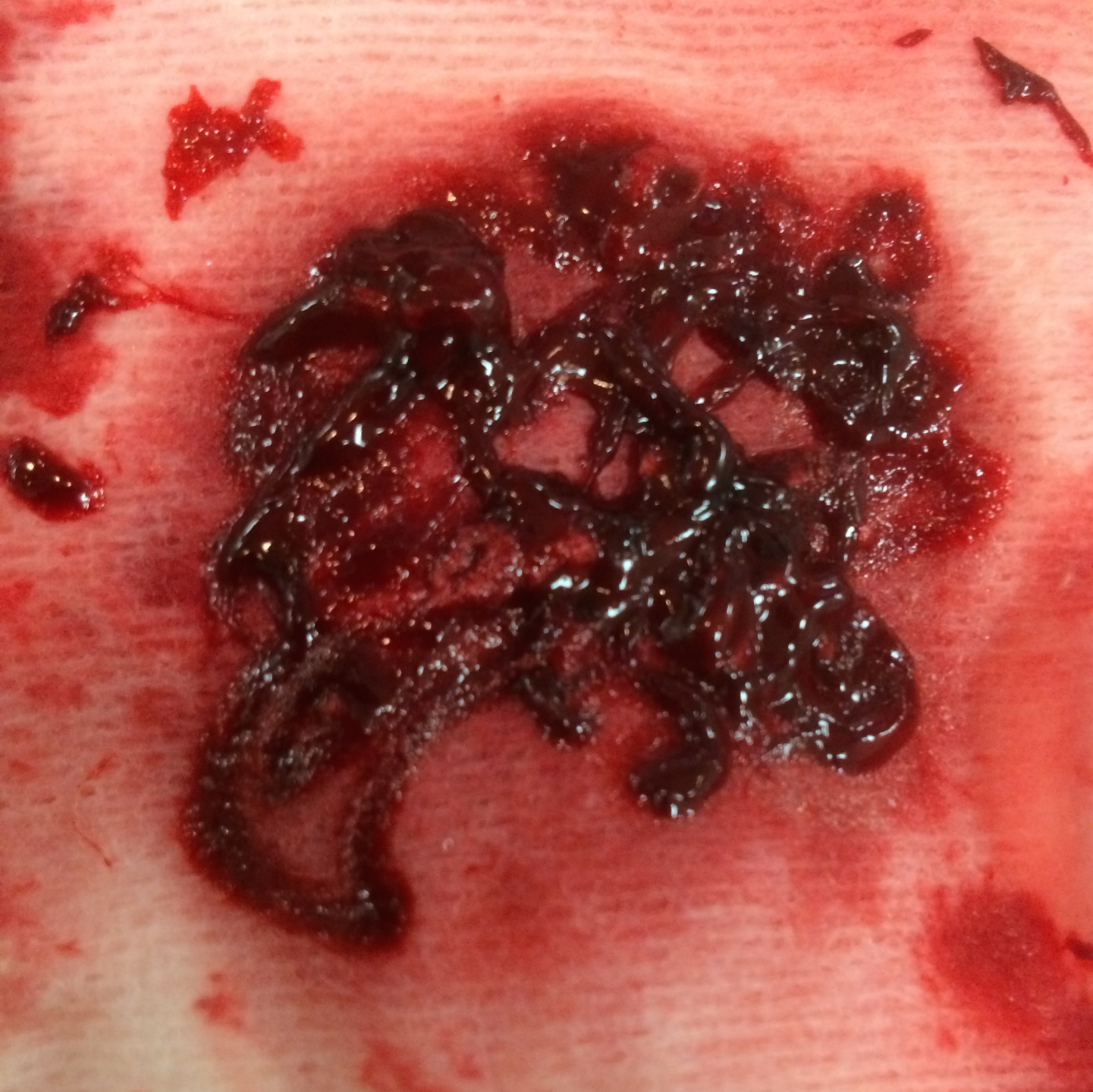

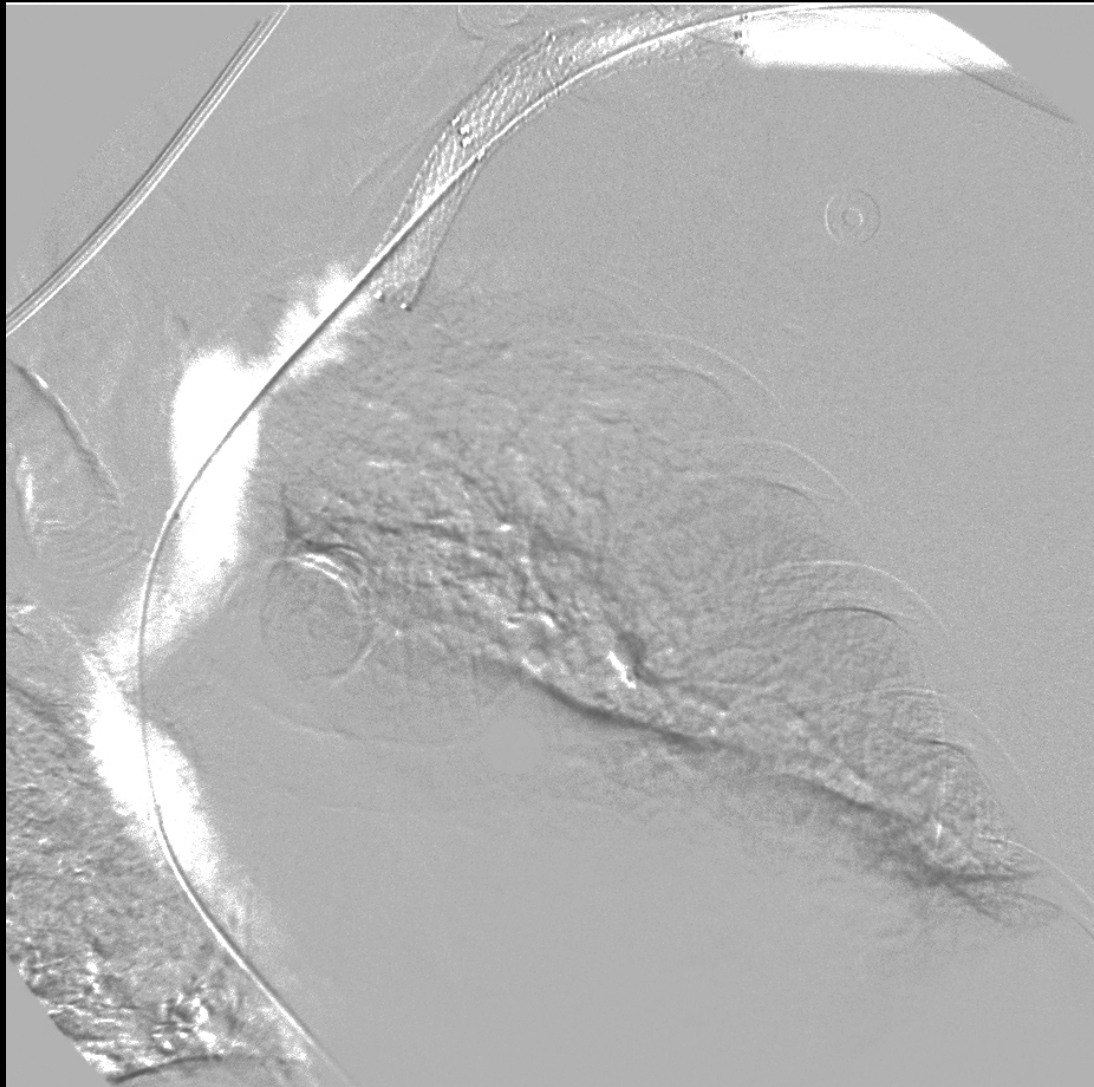


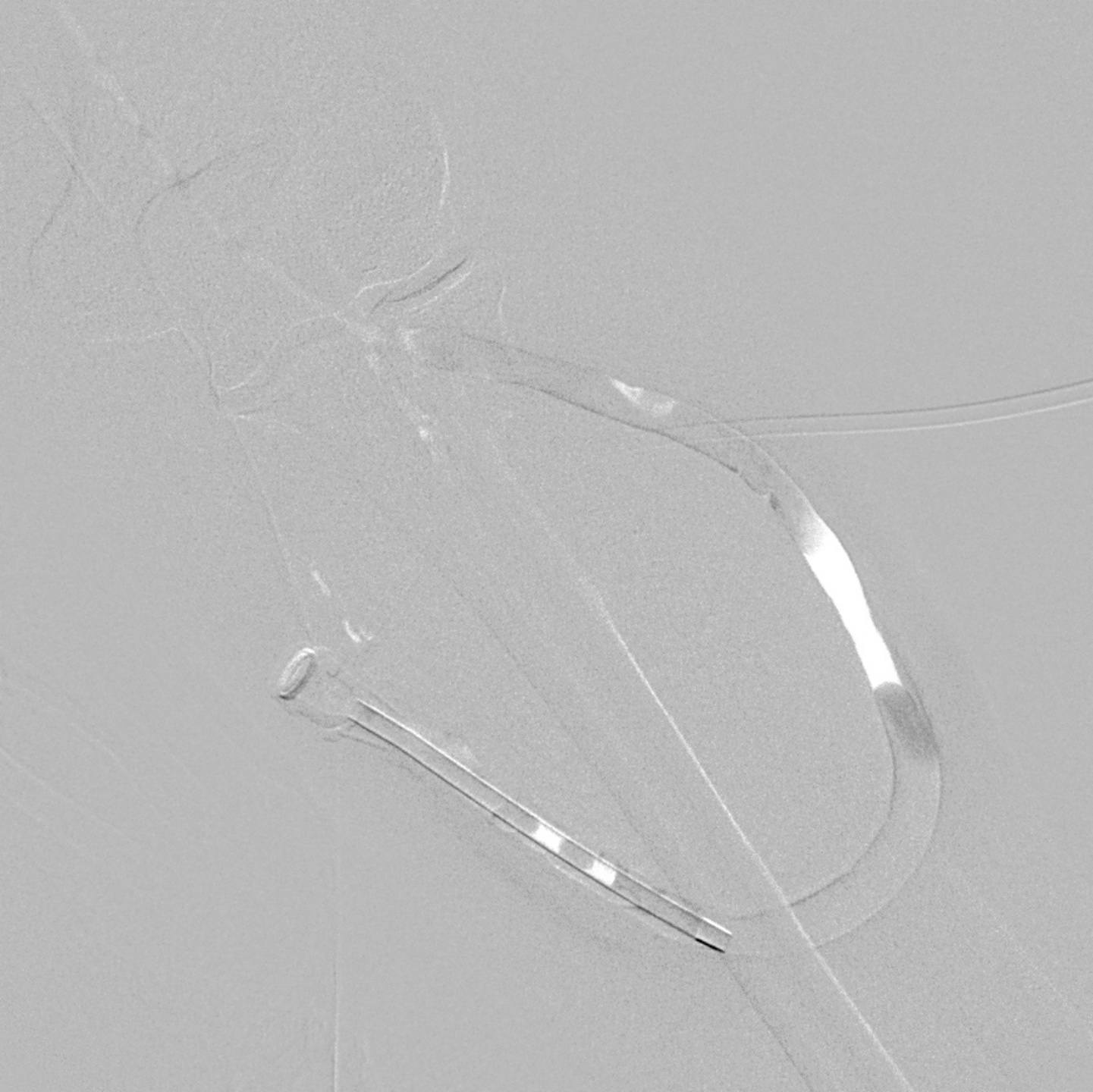


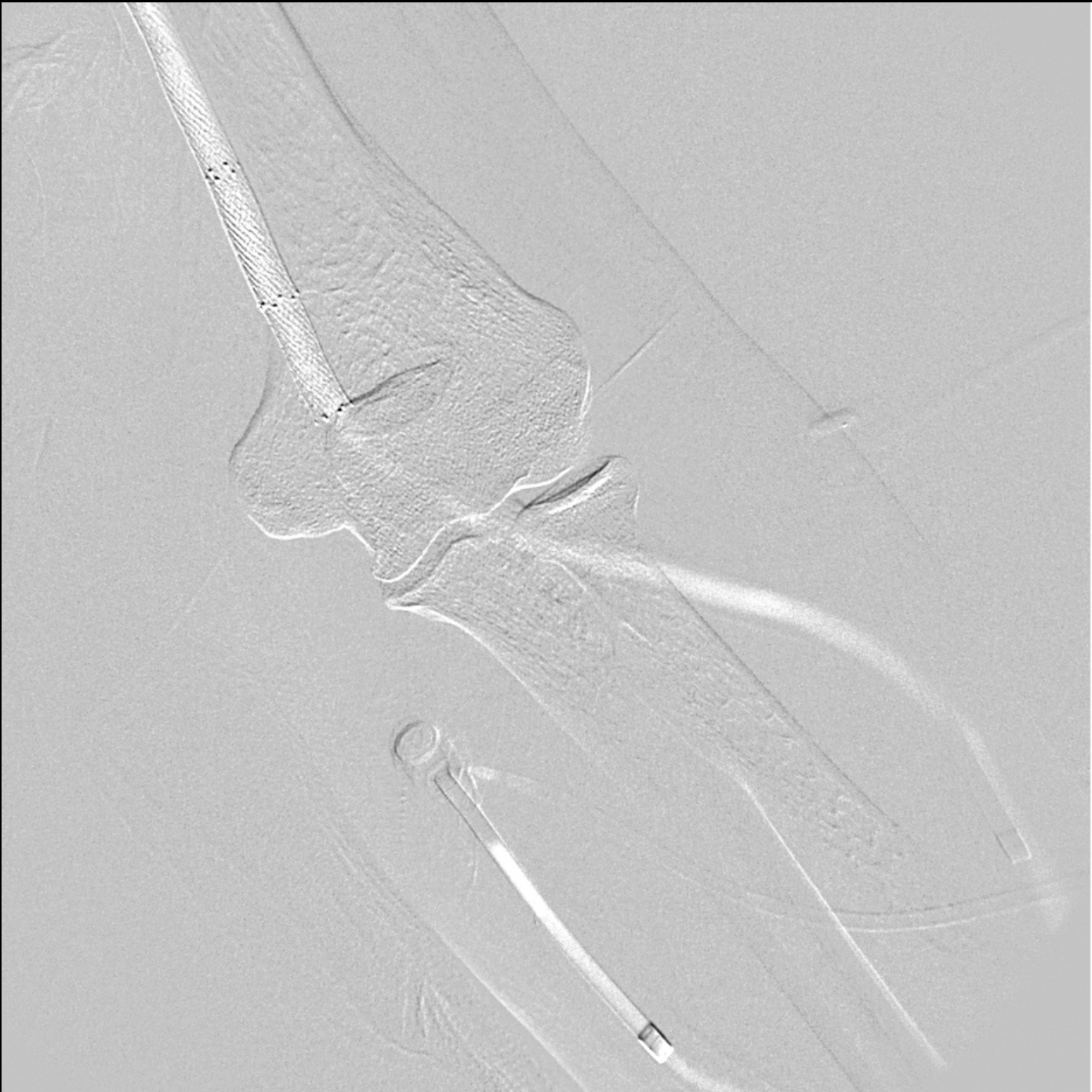



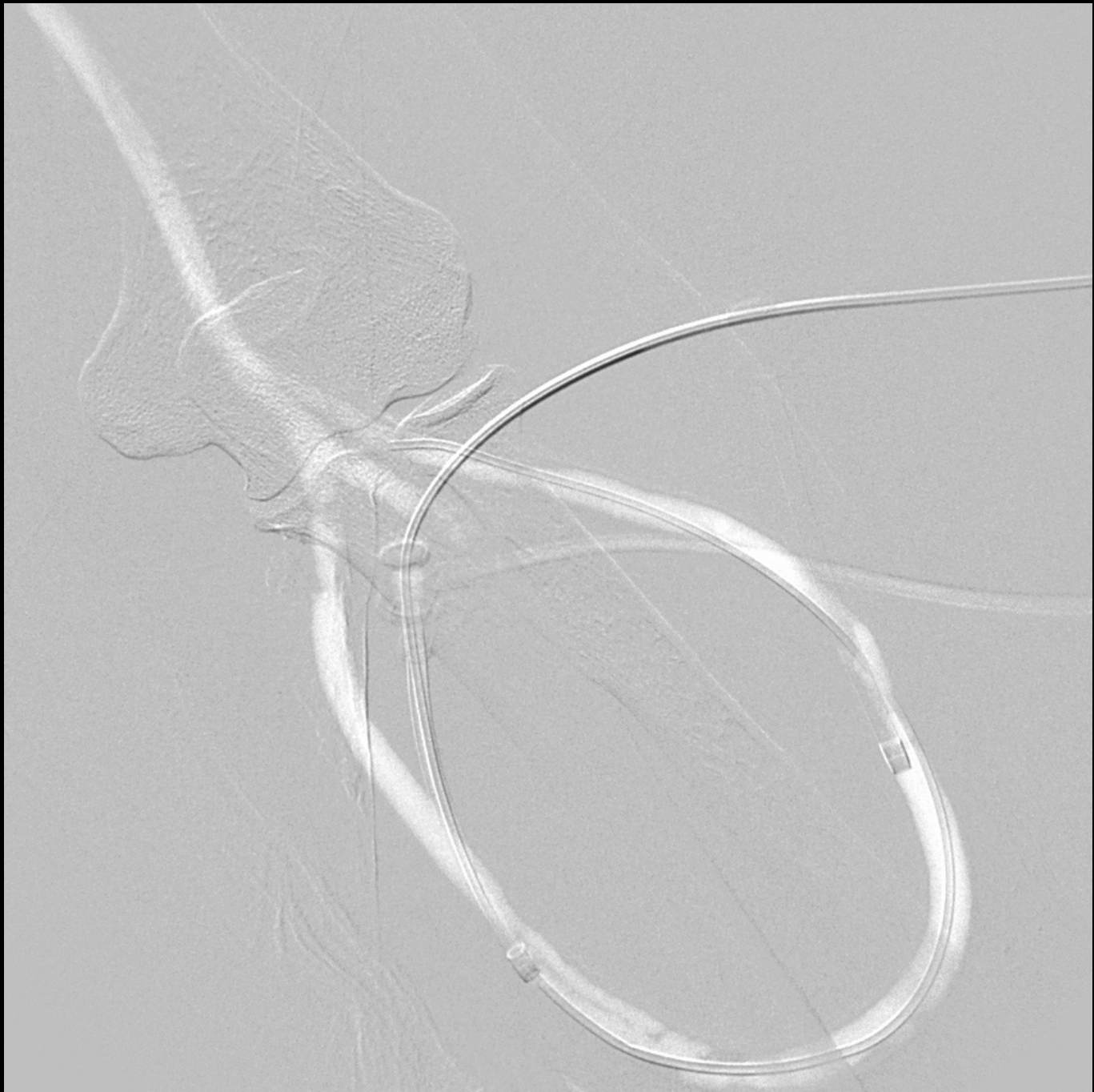










# **CO<sub>2</sub> DIALYSIS ACCESS**

**The mission is to visualize the access without refluxing CO<sub>2</sub> into the cerebral vessels!!!!**

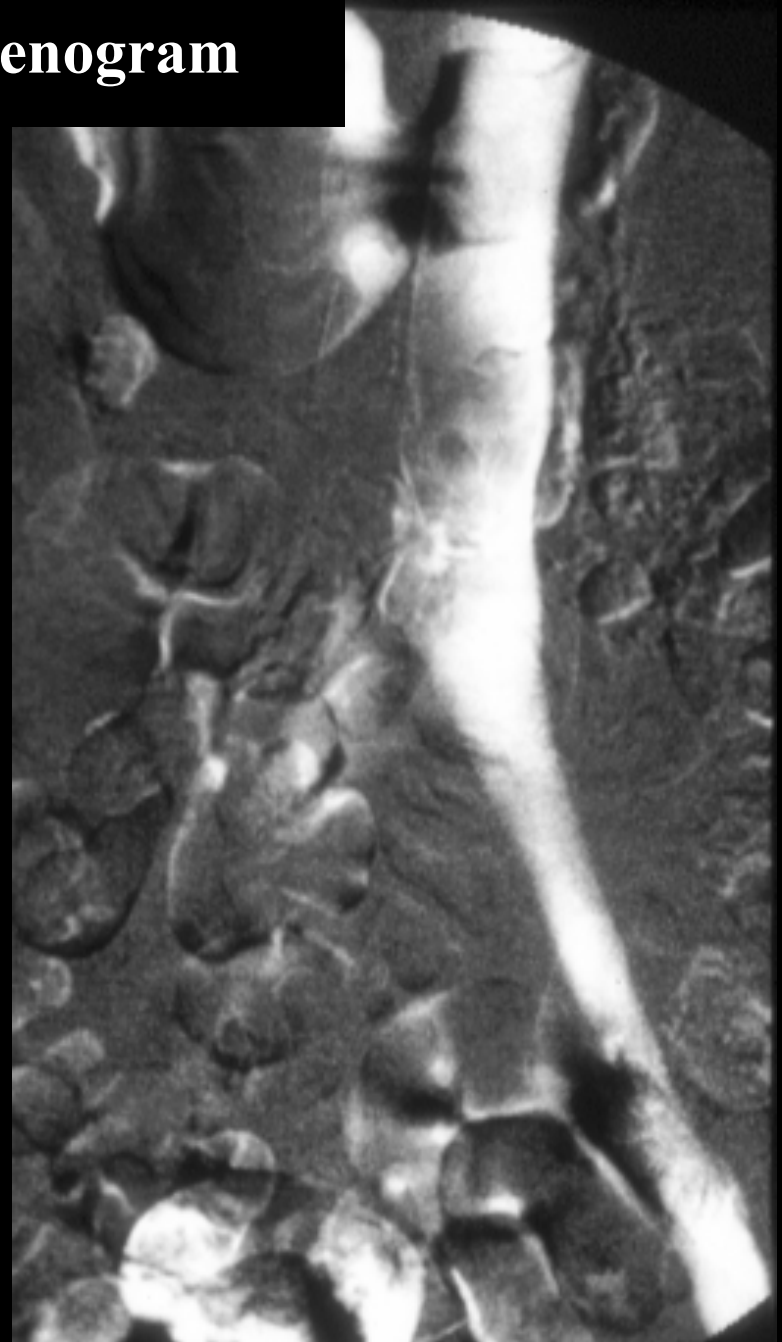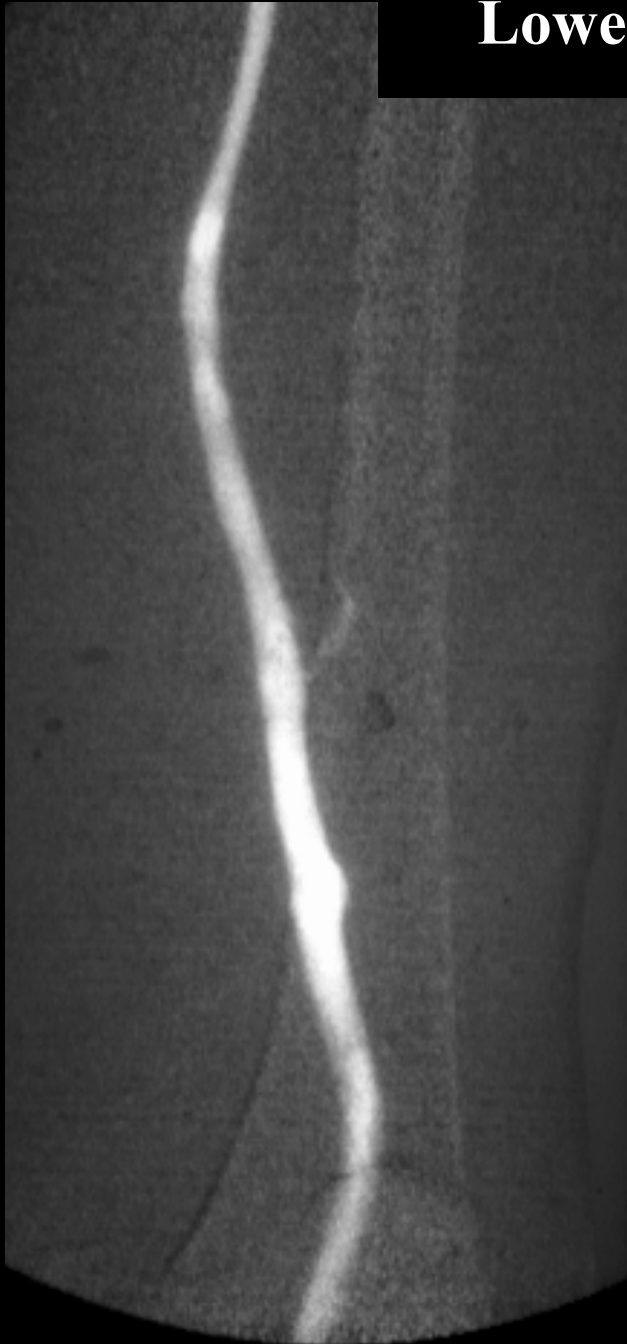**Visualize venous limb non-explosively**

**Alternatively place occlusion balloon toward venous limb inflate balloon and inject**

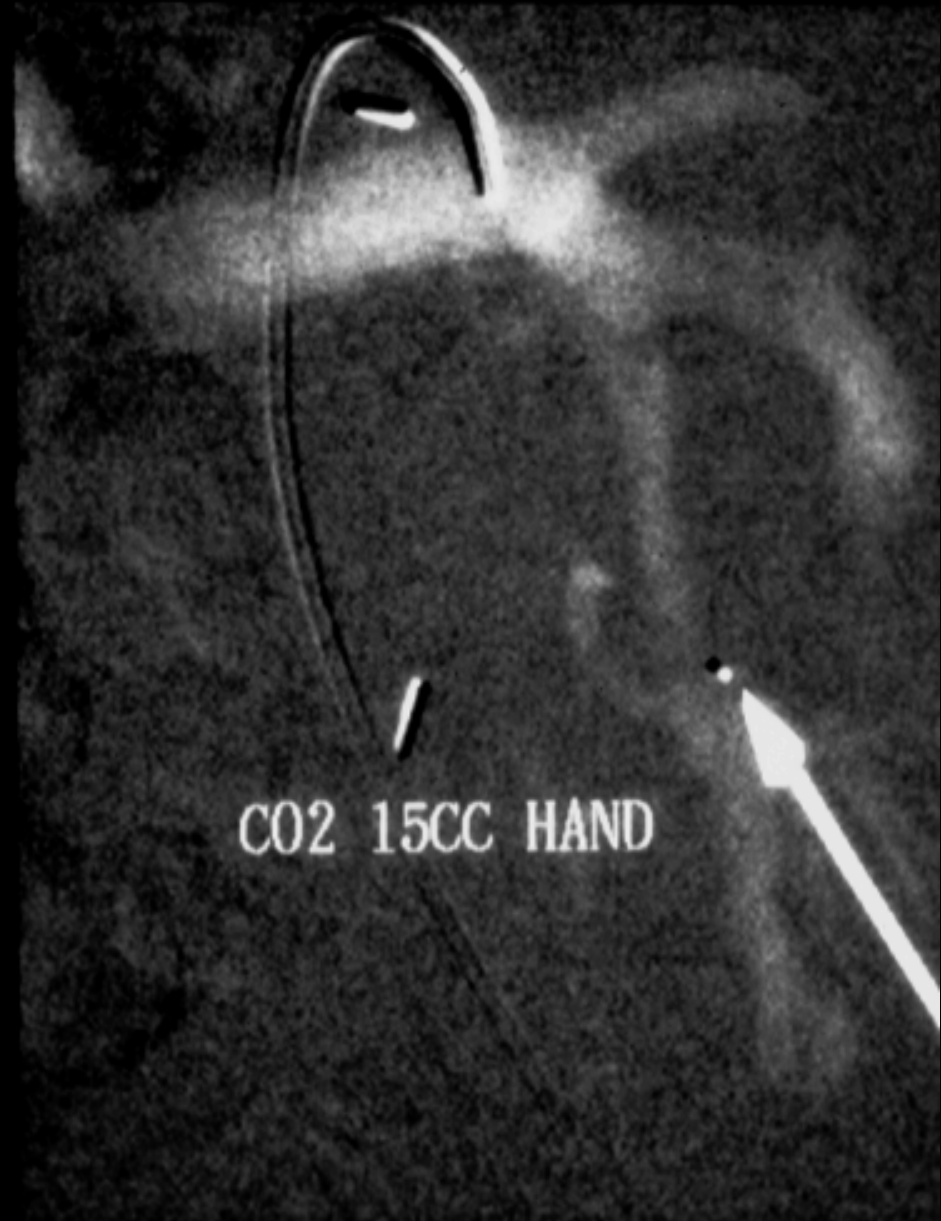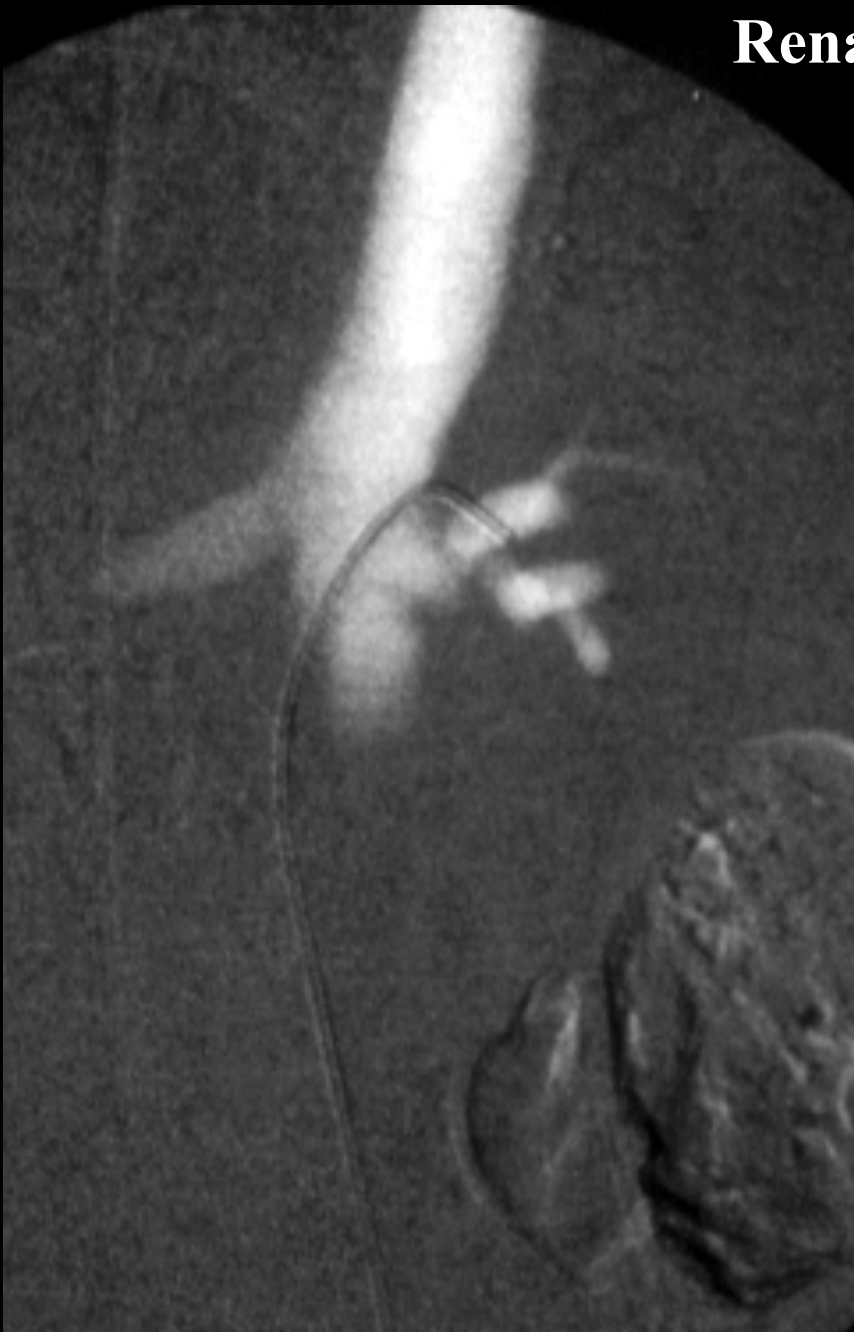**For arterial anastomosis DO NOT forcefully reflux  
Place micro catheter in artery and inject gently**

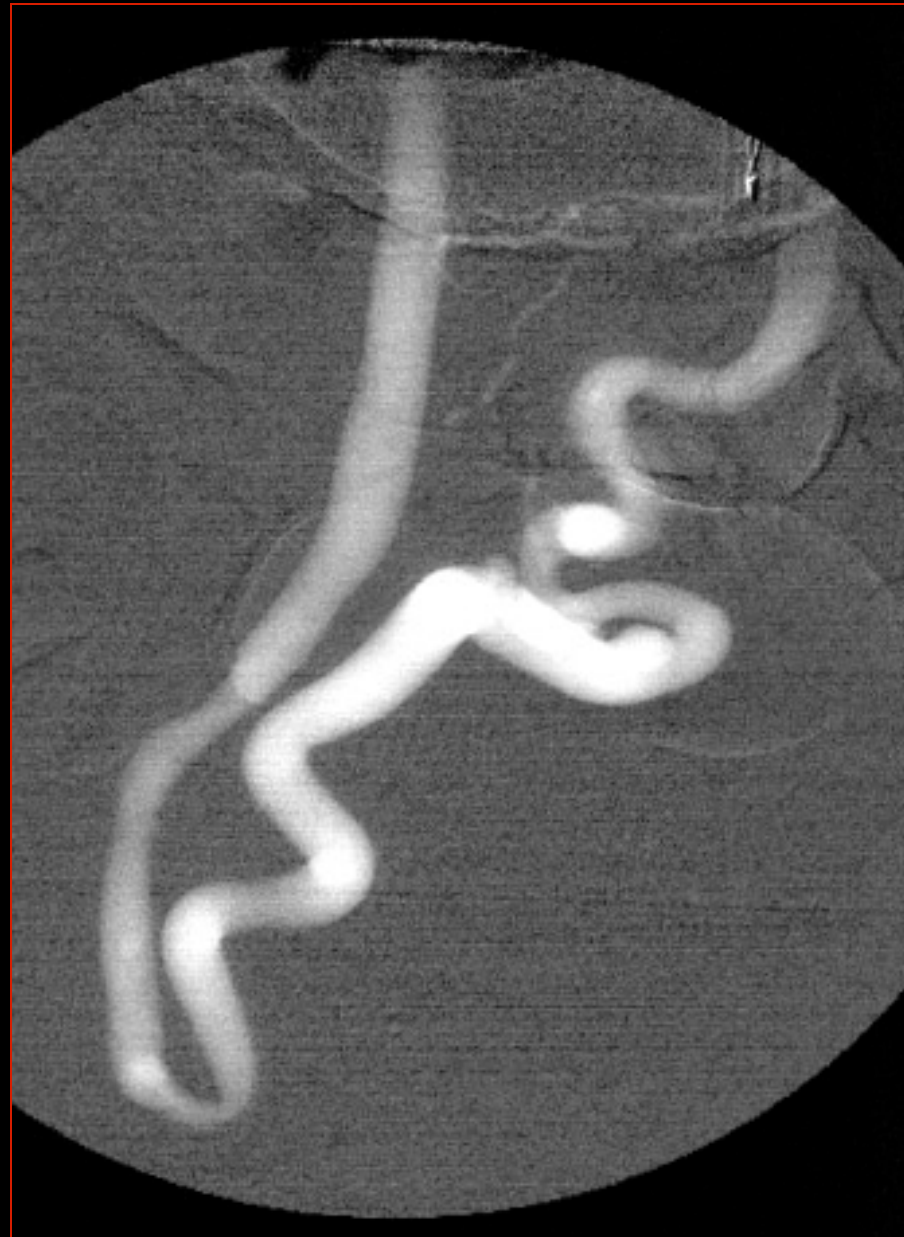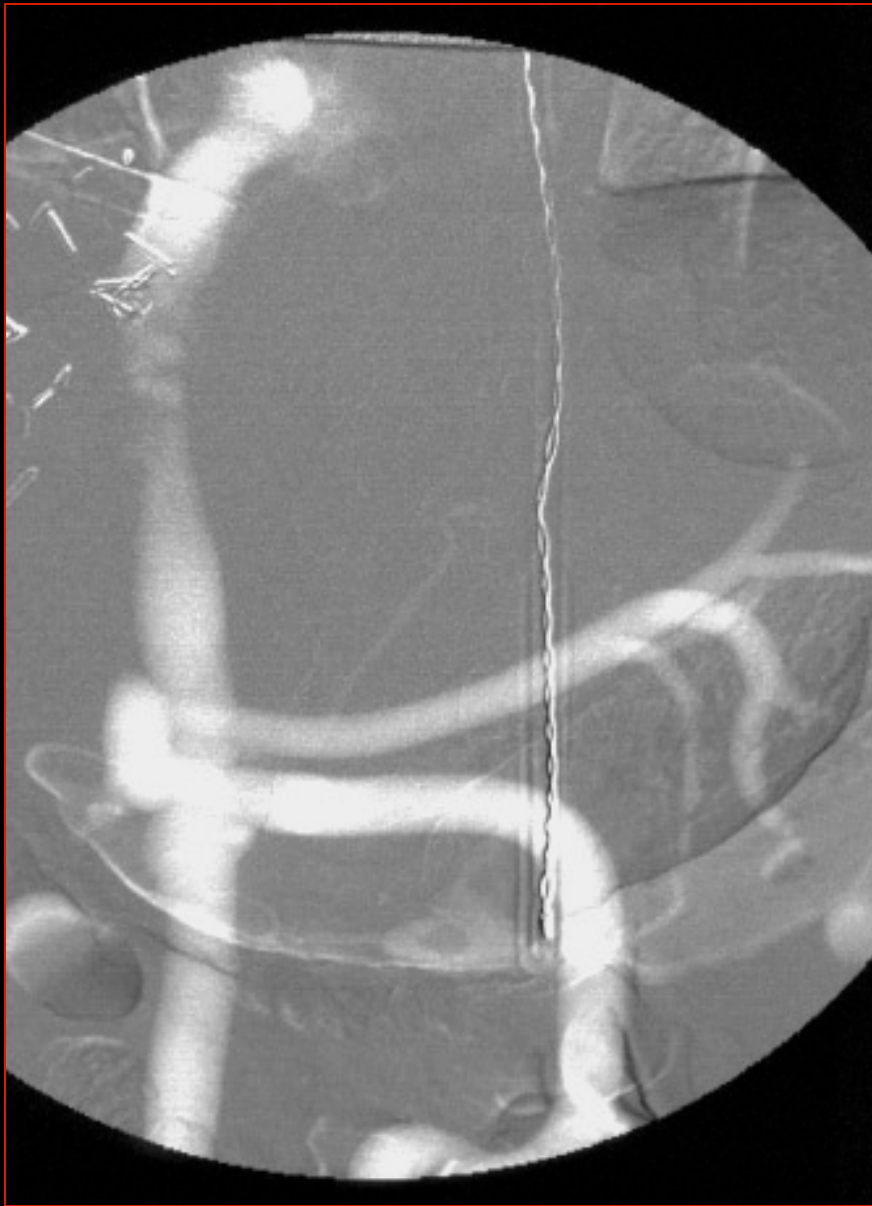**If a tilting table is available place in Trendeleburg**

# Lower ext venogram

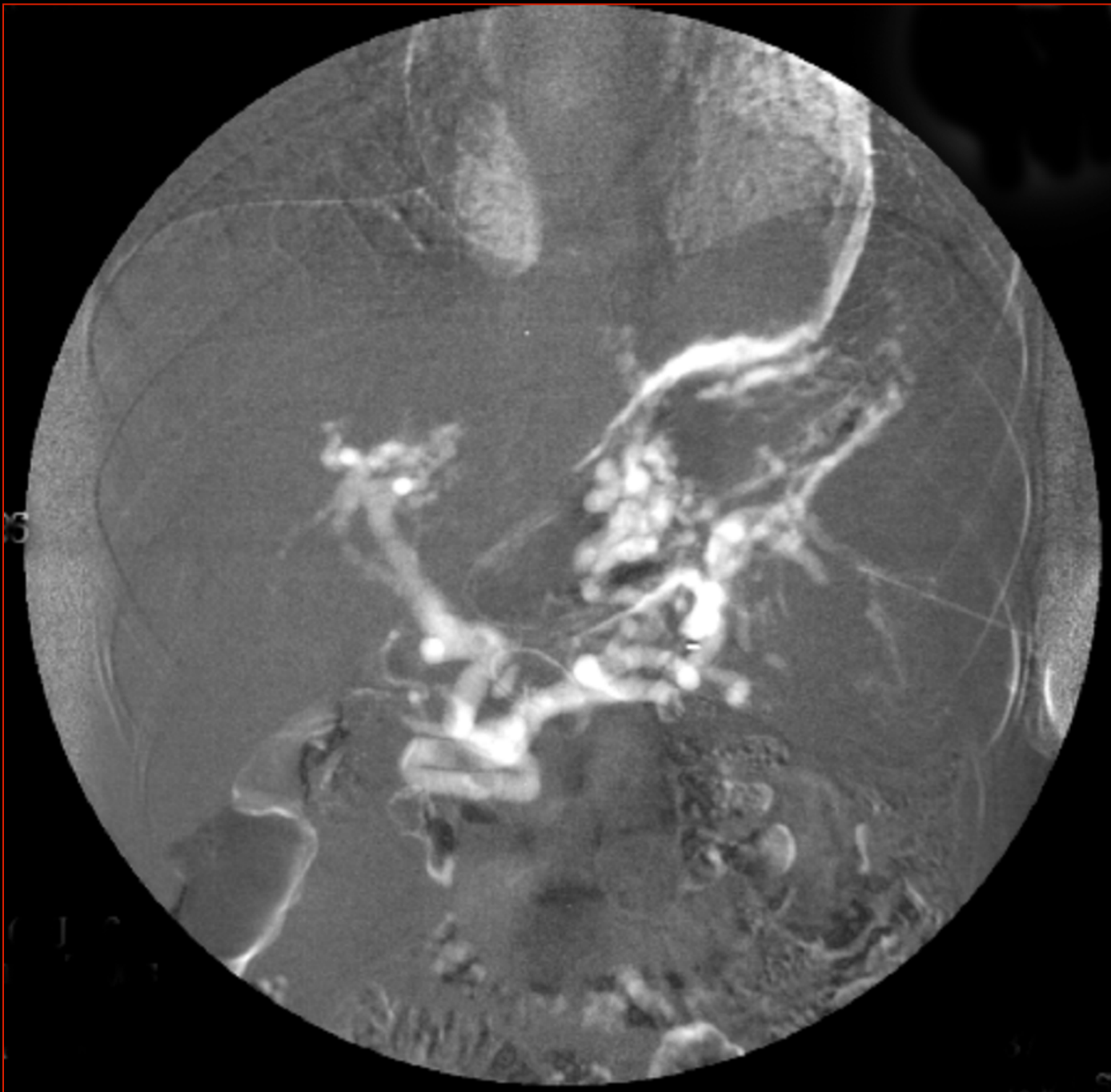

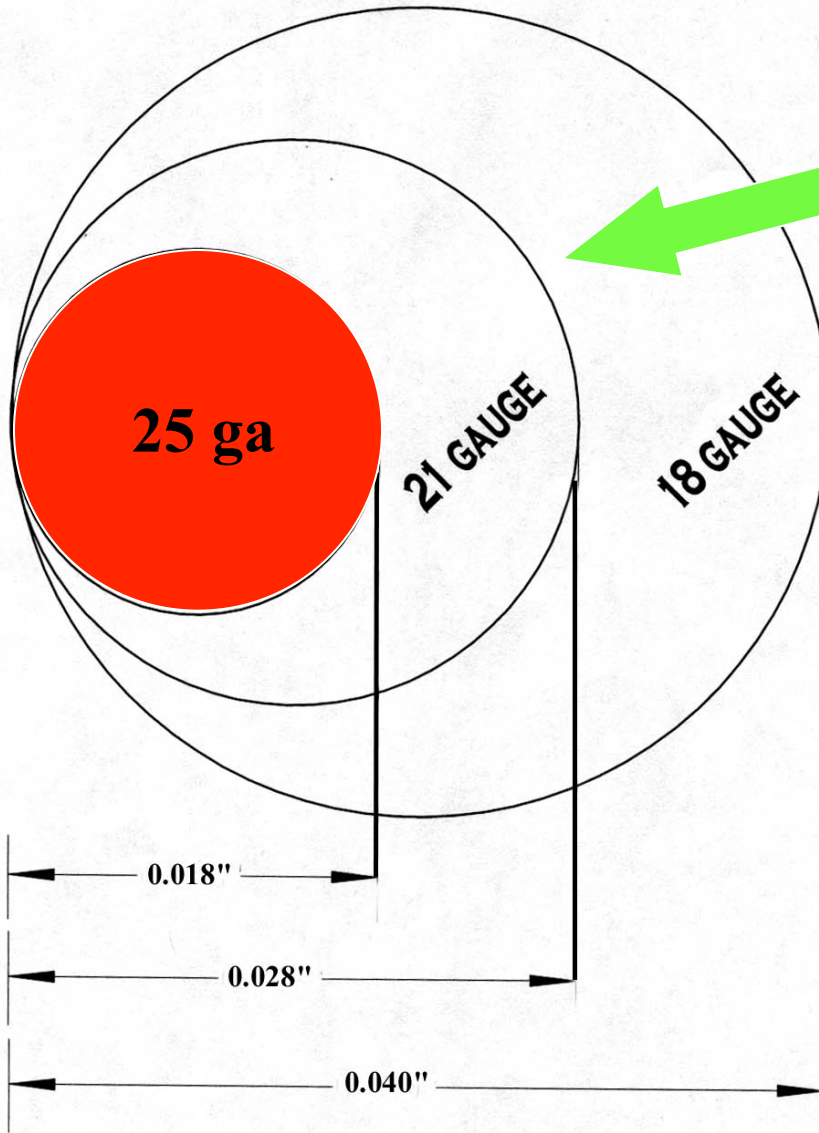
# Renal venogram



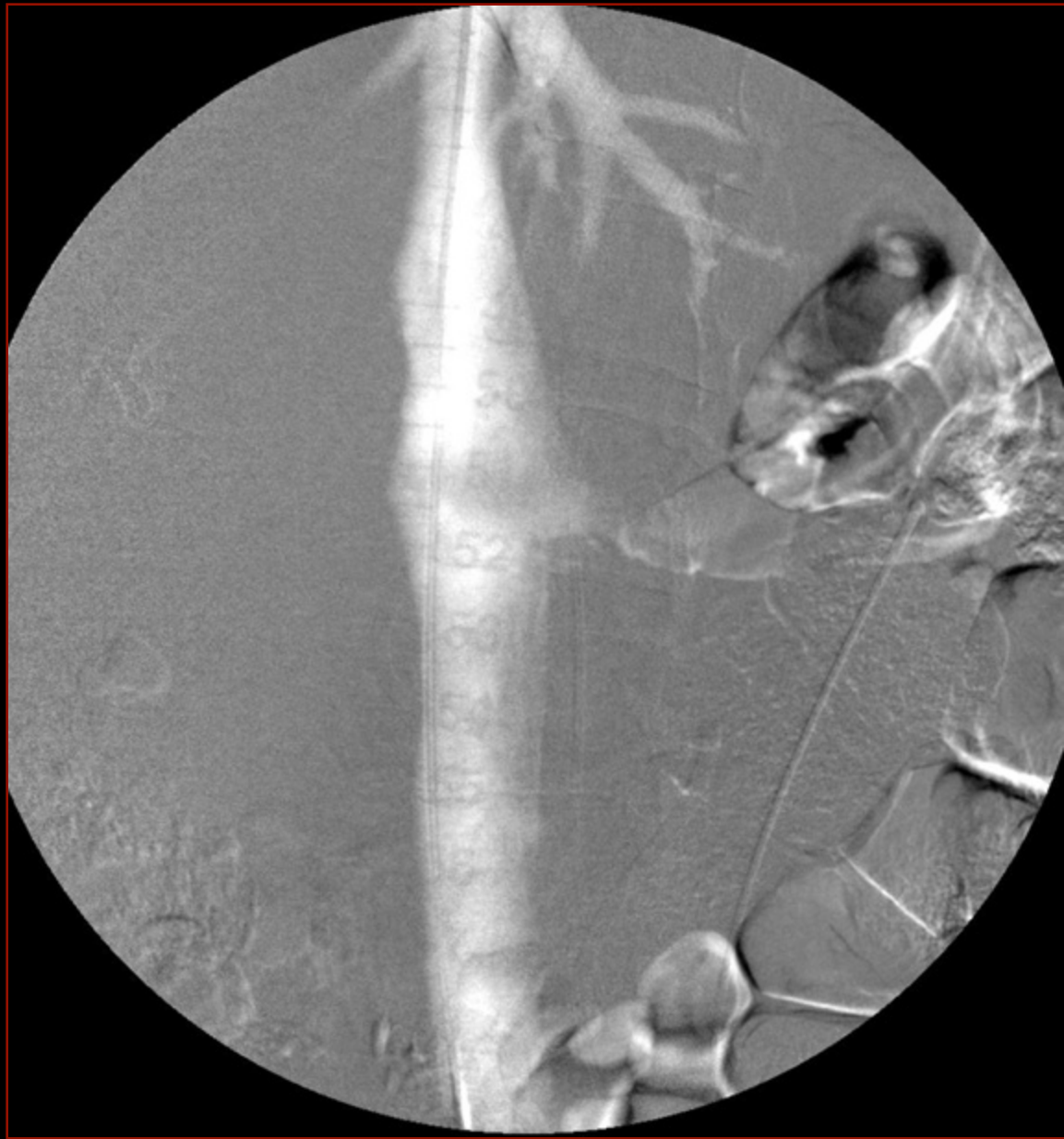

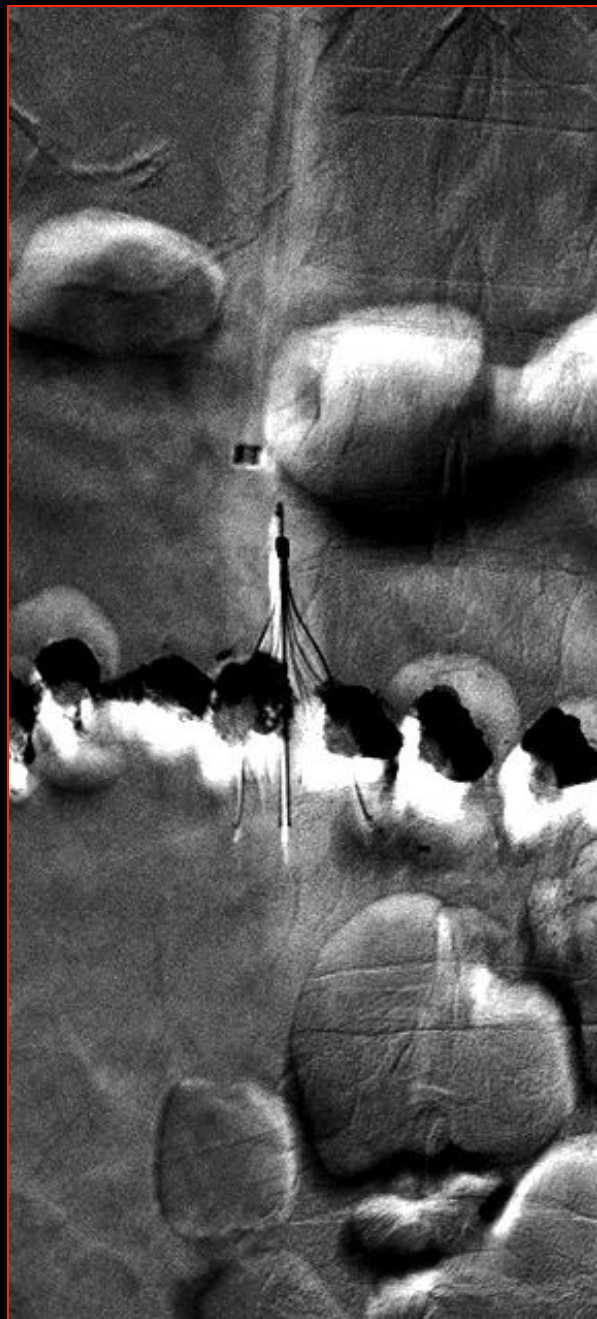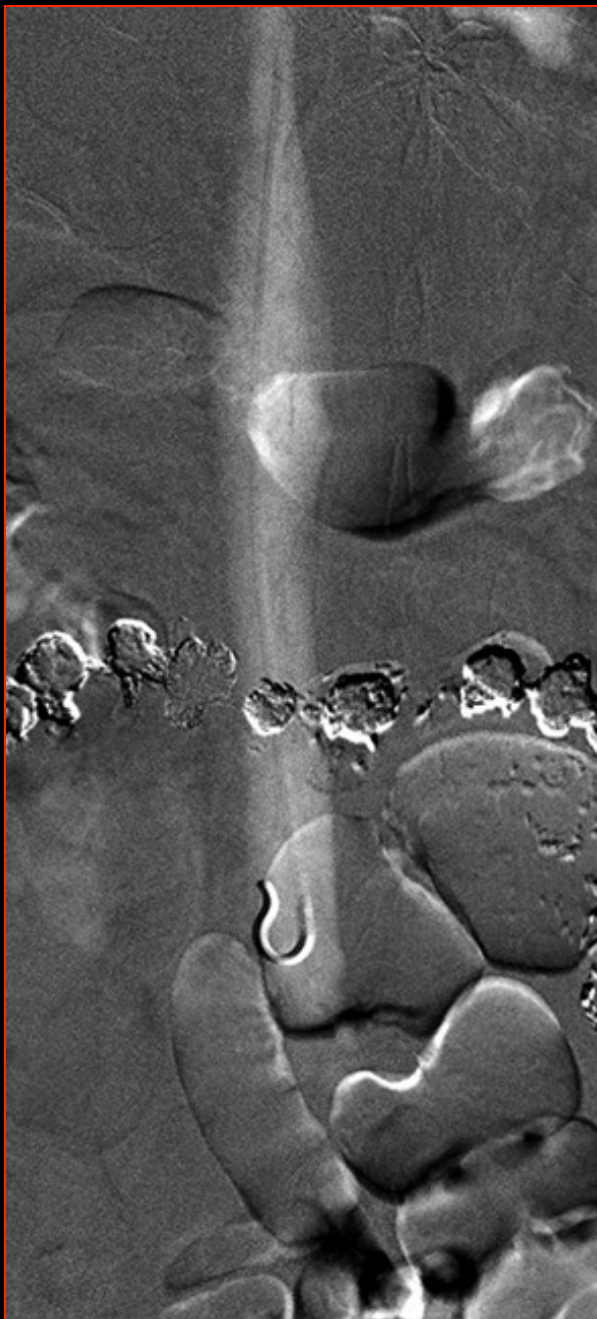
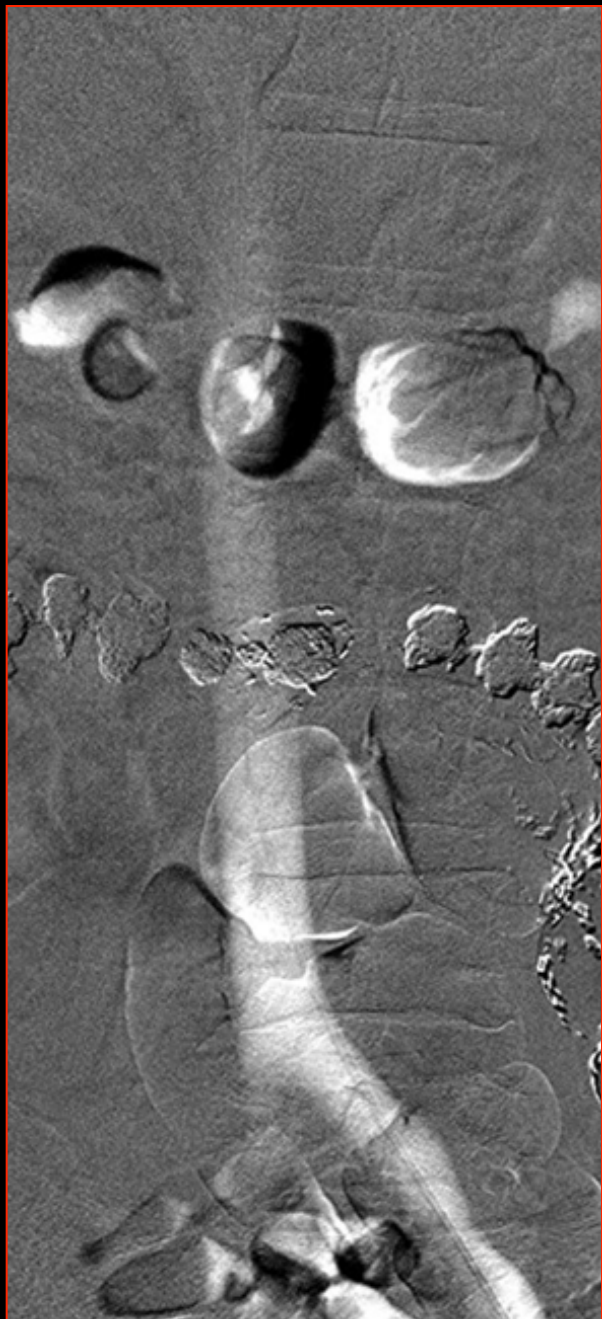
**Splenoportogram with direct 25 ga spinal needle injection<sup>137</sup>**





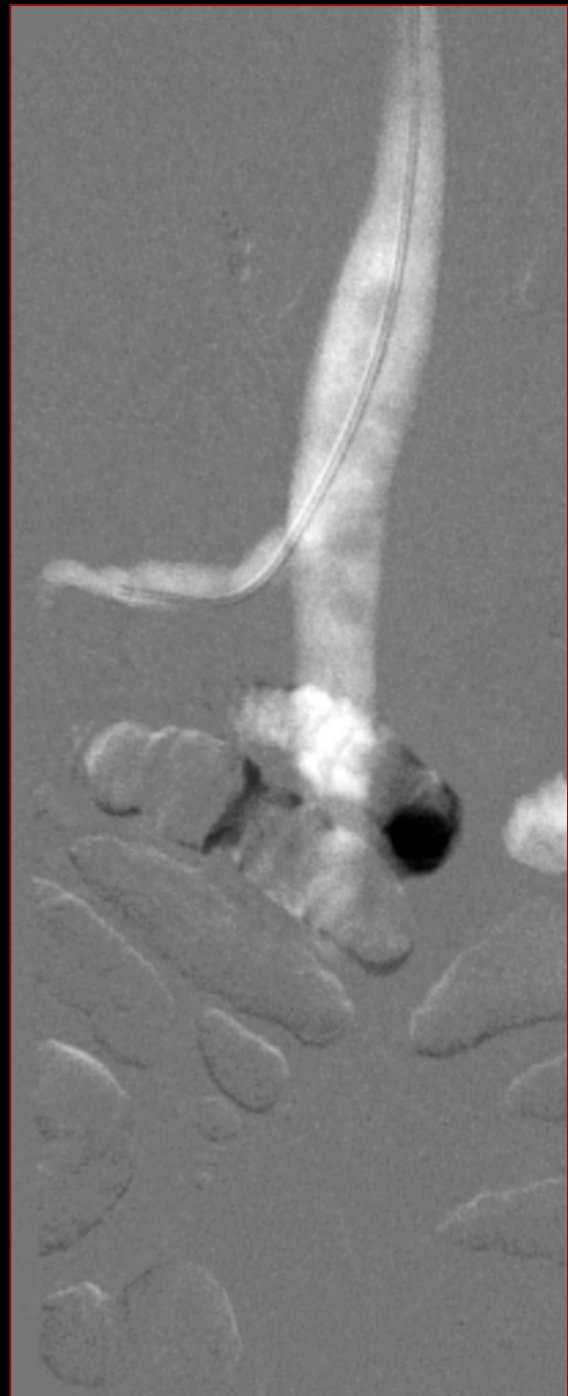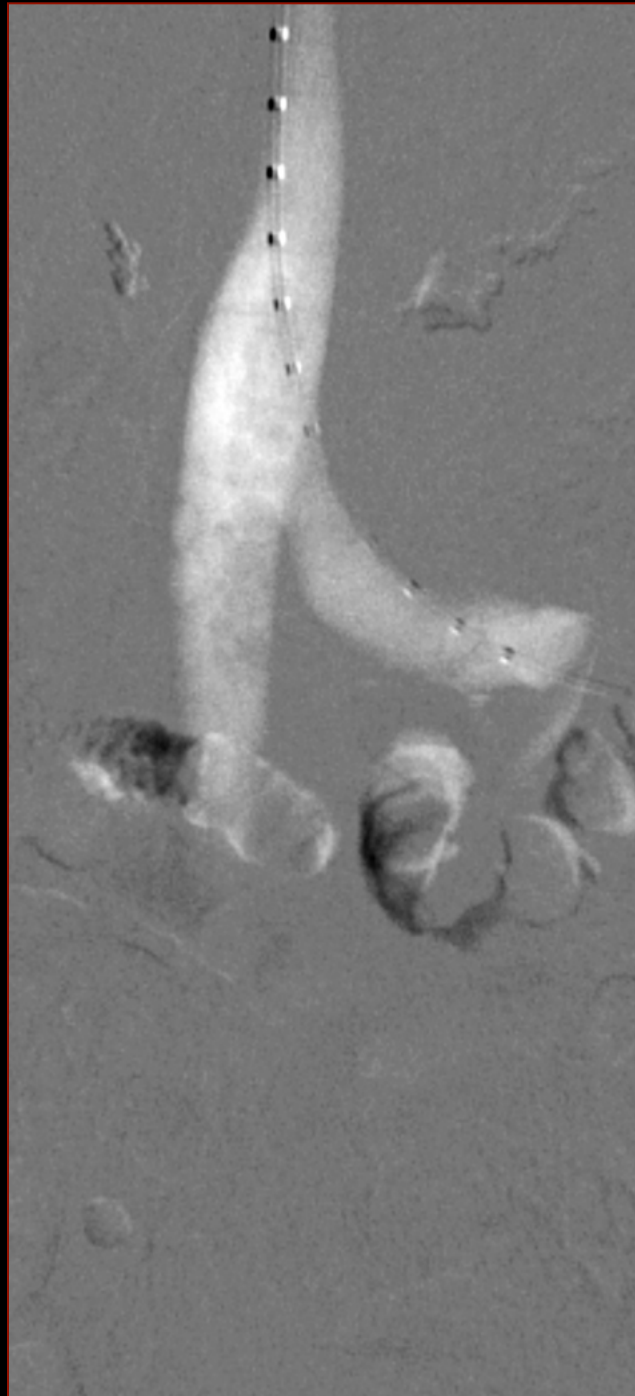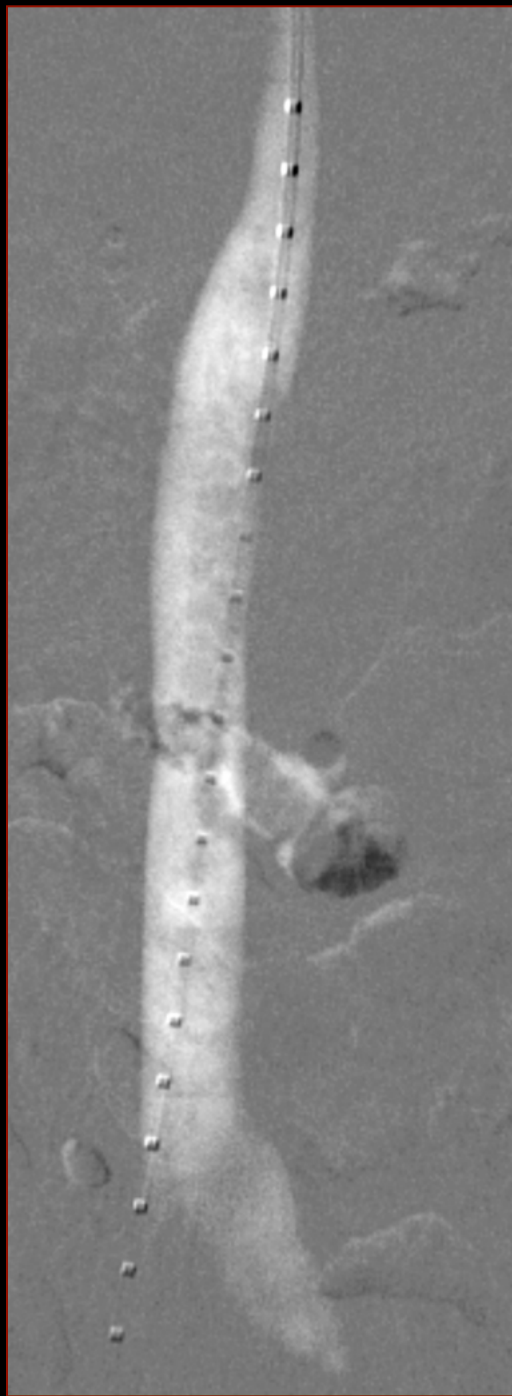**1/3 rd  
x-section area  
of 21 ga**

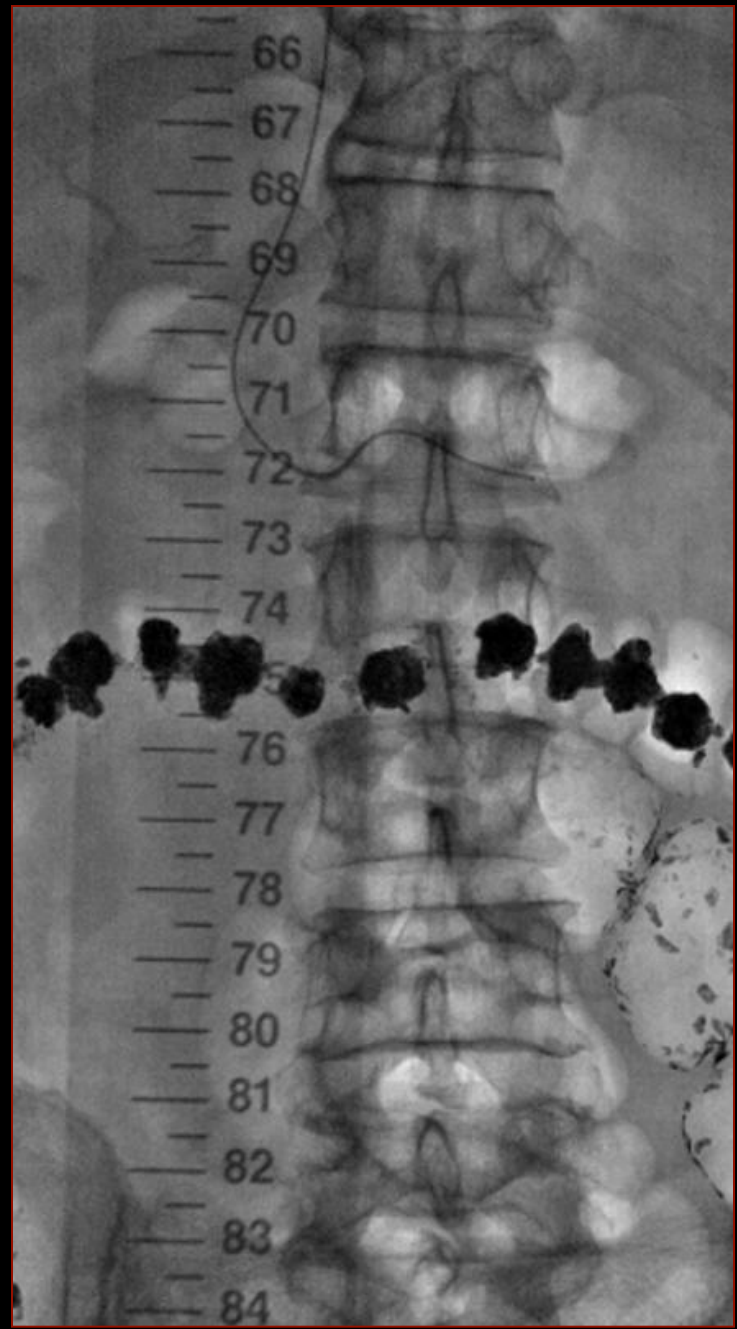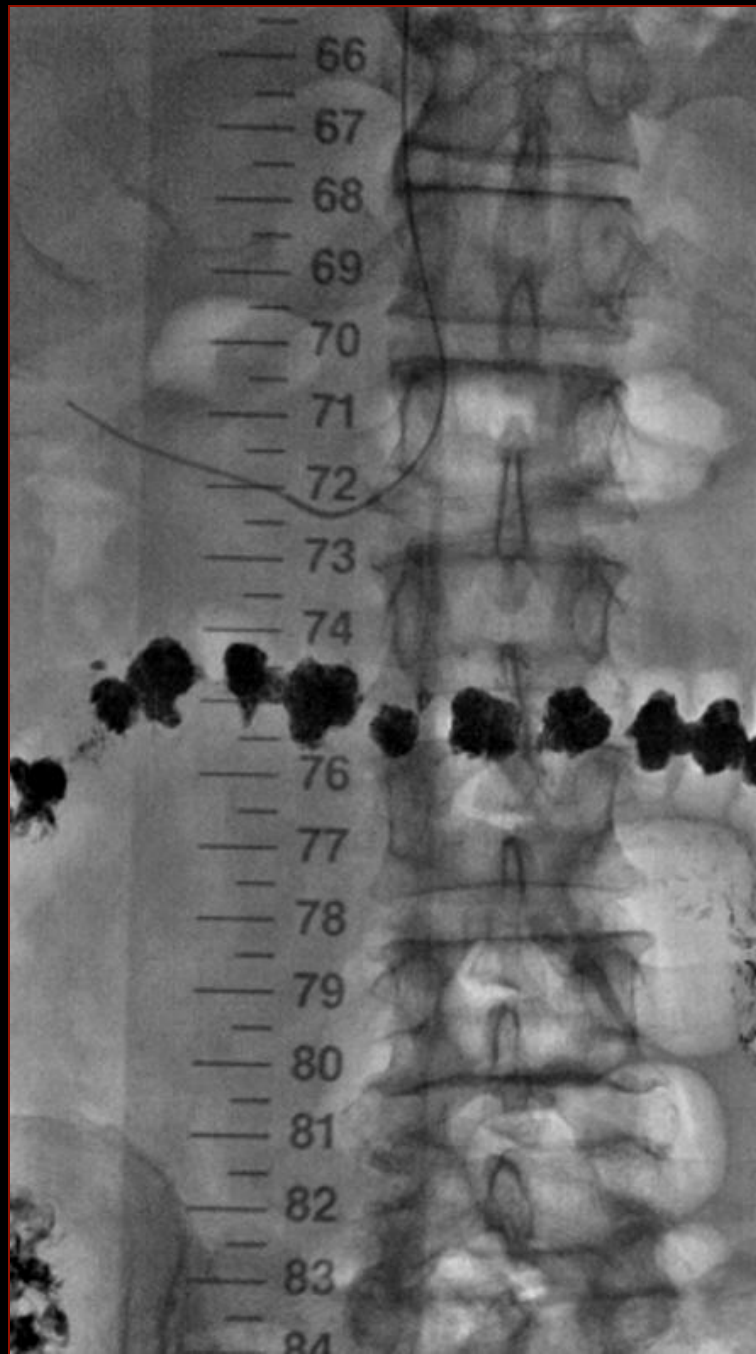




# **IVC GUIDELINES**

- **Review CT first if available for size, and congenital variants**
- **Requires higher volumes: 20-50 cc**
- **Literature support with almost 1/1 correlation with iodinated contrast**
- **Right posterior renal vein more posterior and may not be visualized**
- **May require guide wire or catheter localization for renal vein origins**

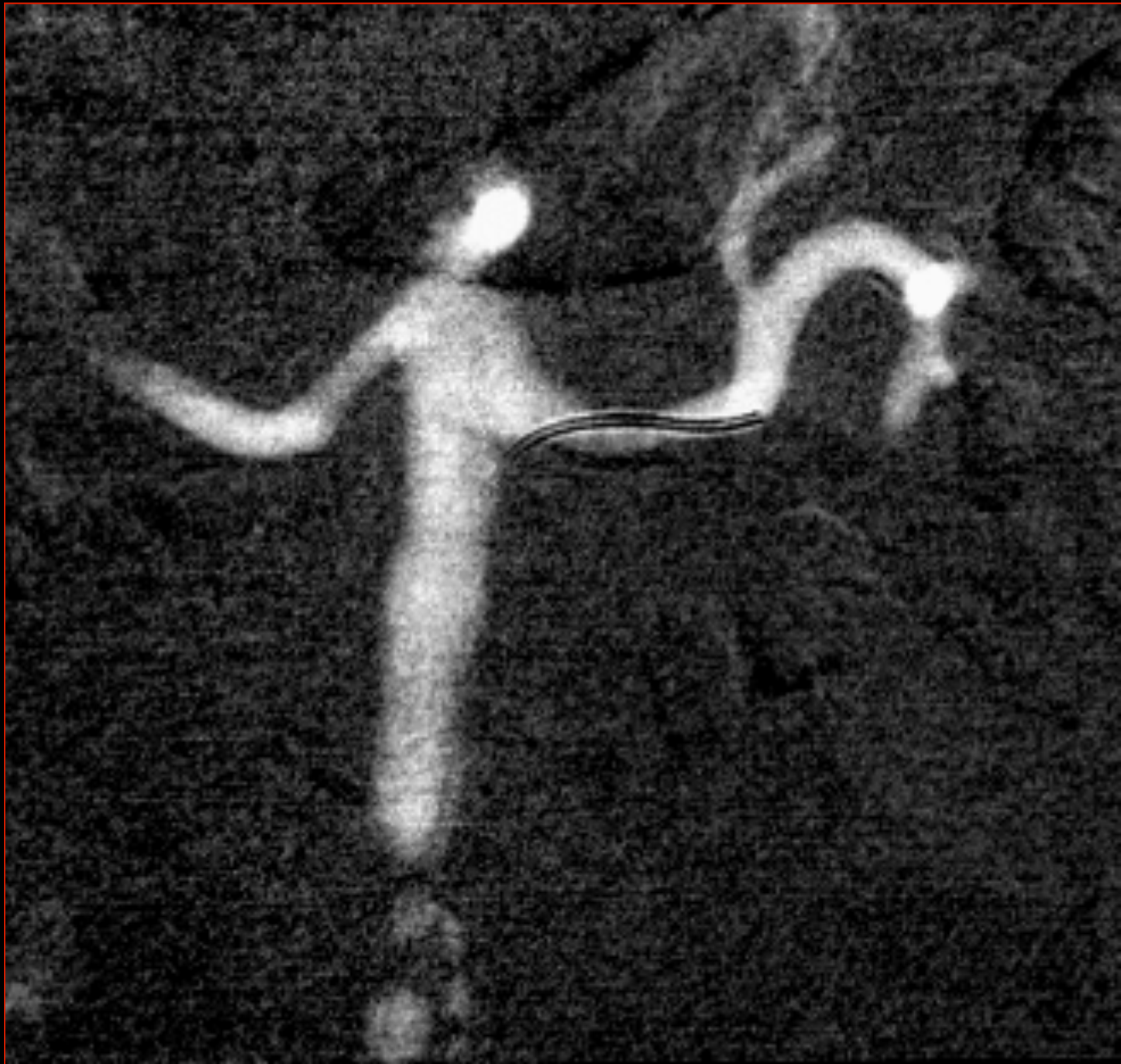


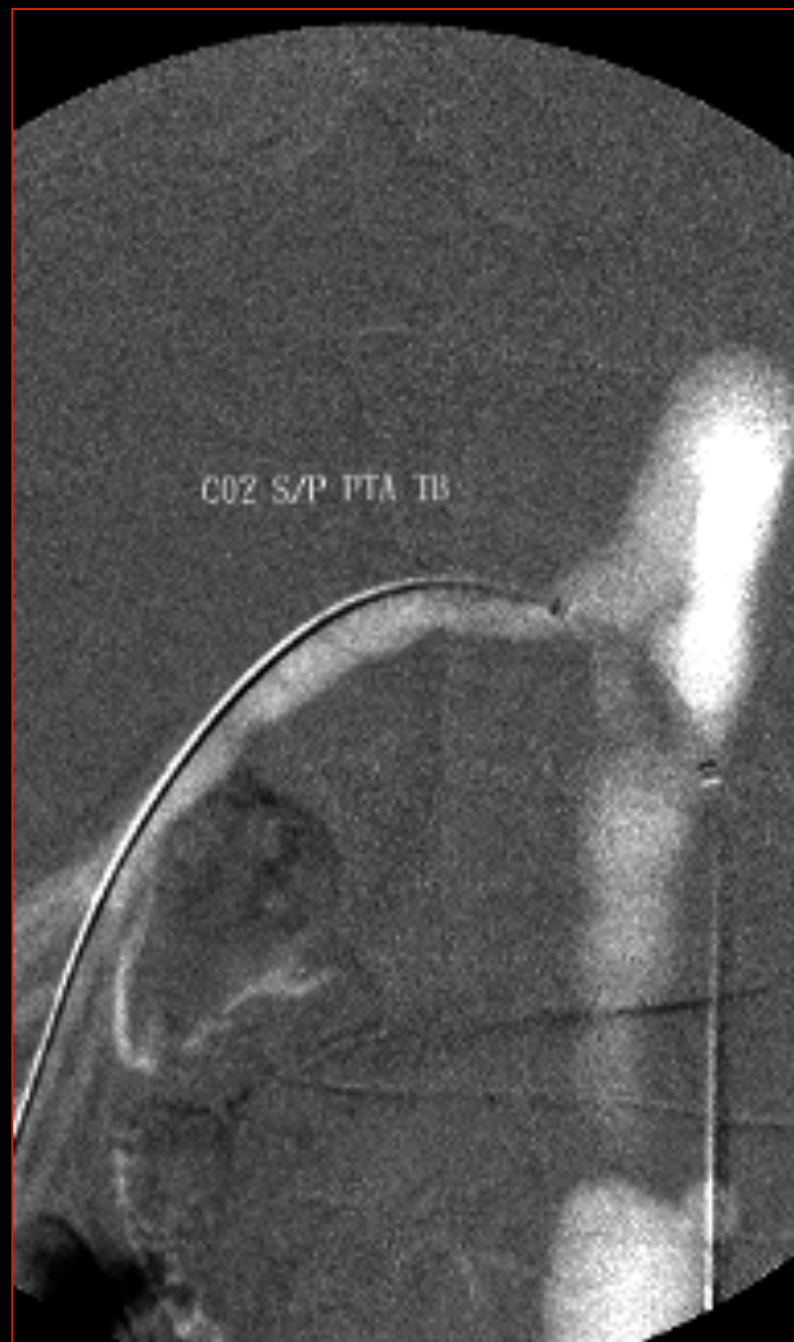
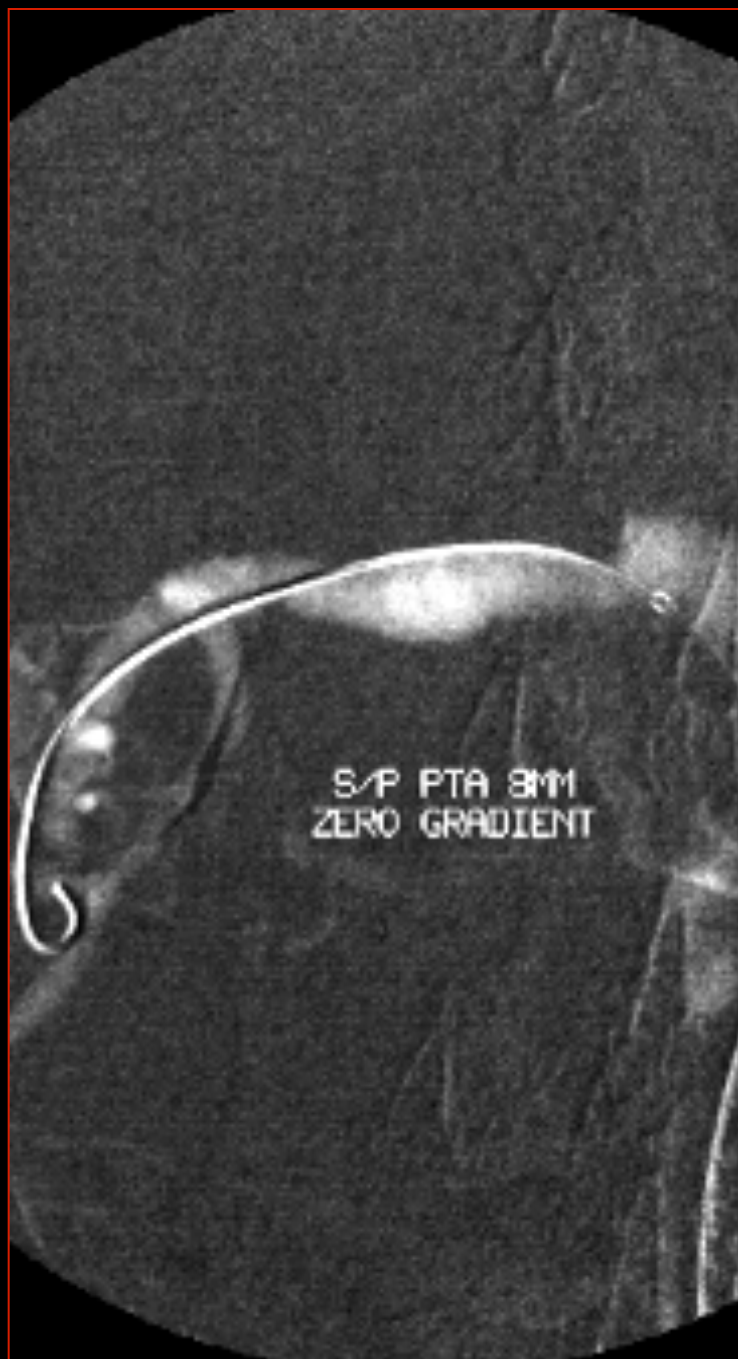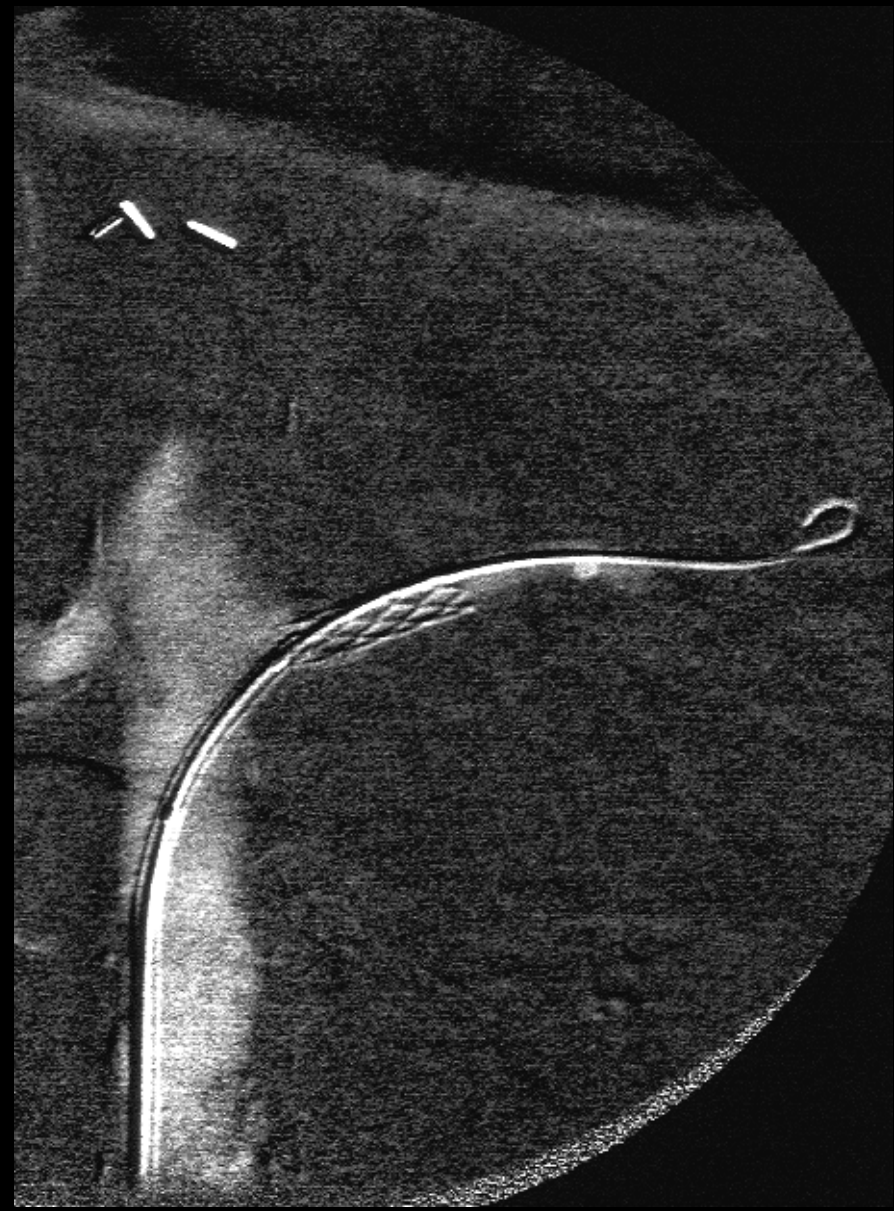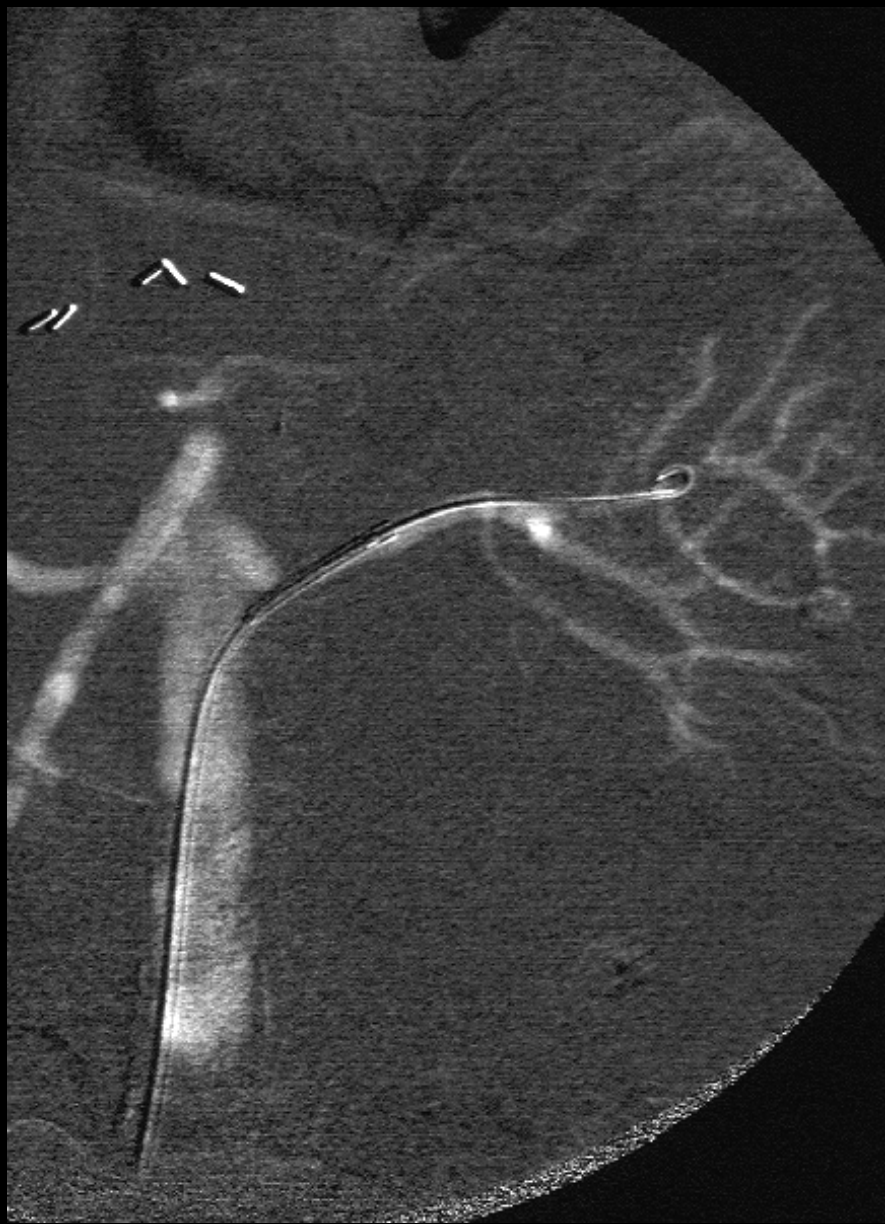# INTERVENTION

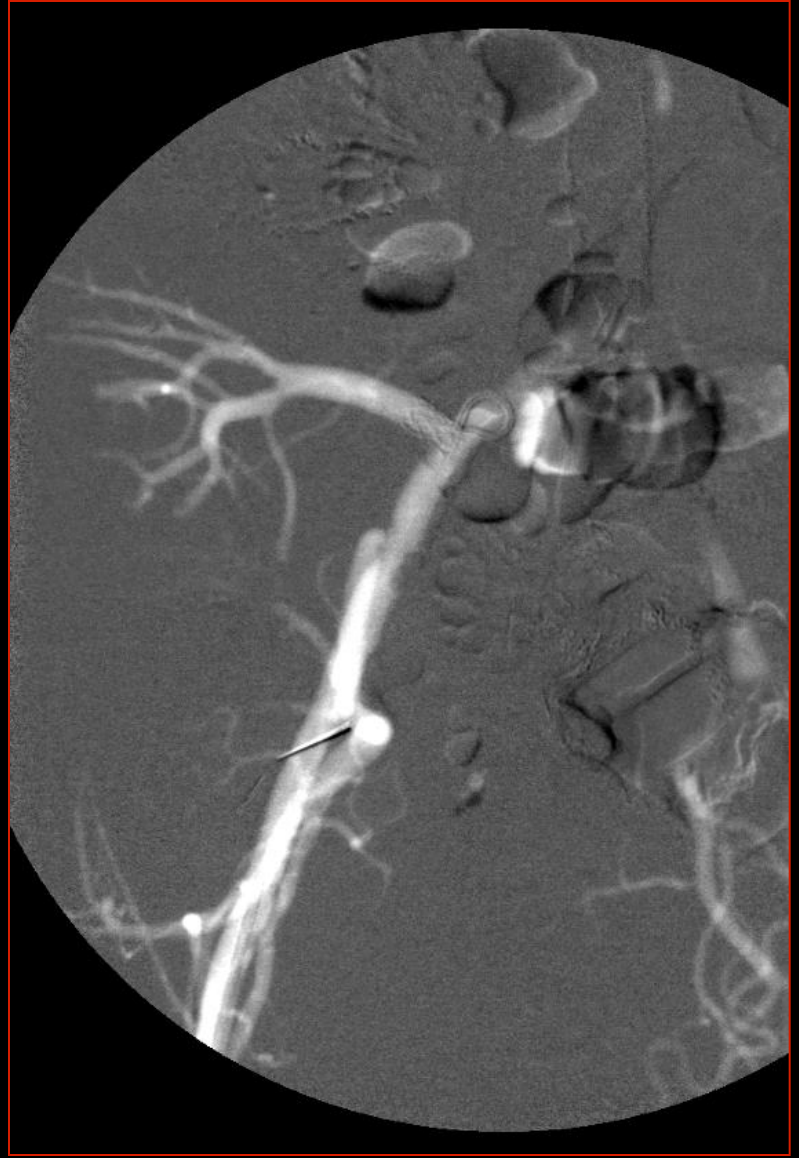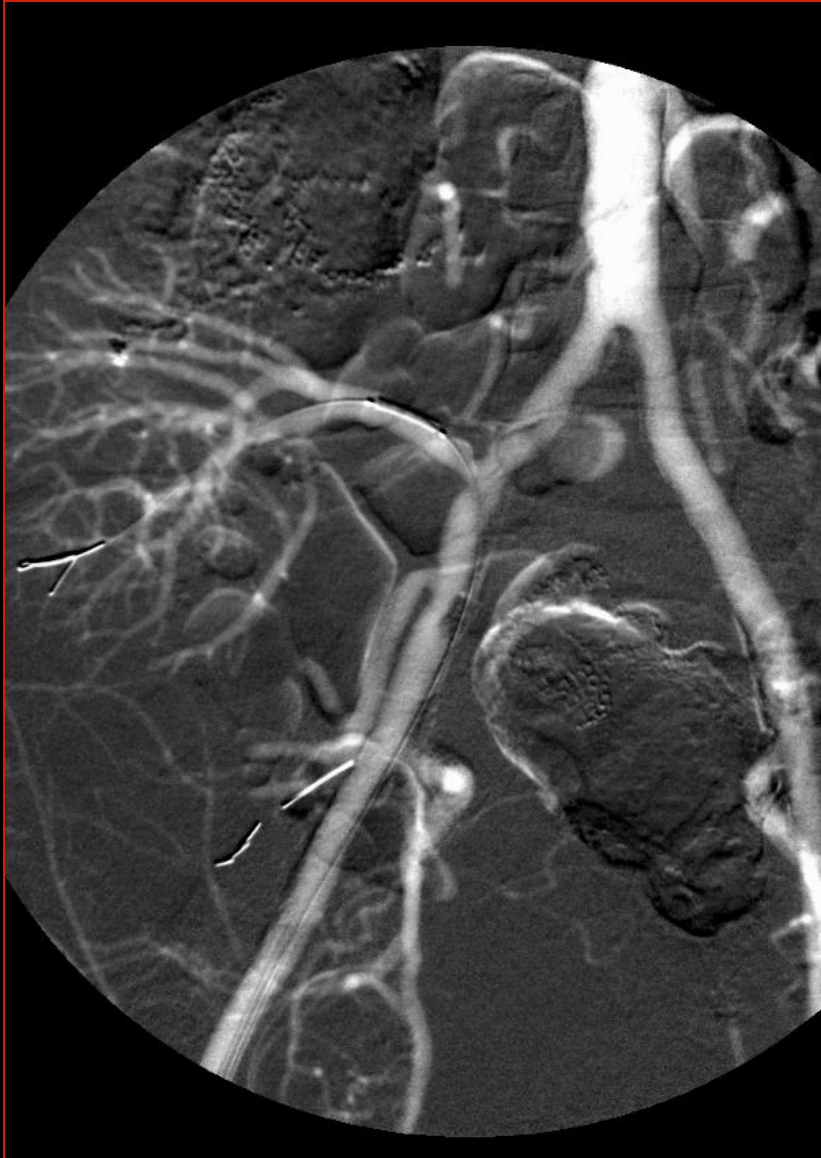
# ARTERIAL INTERVENTION

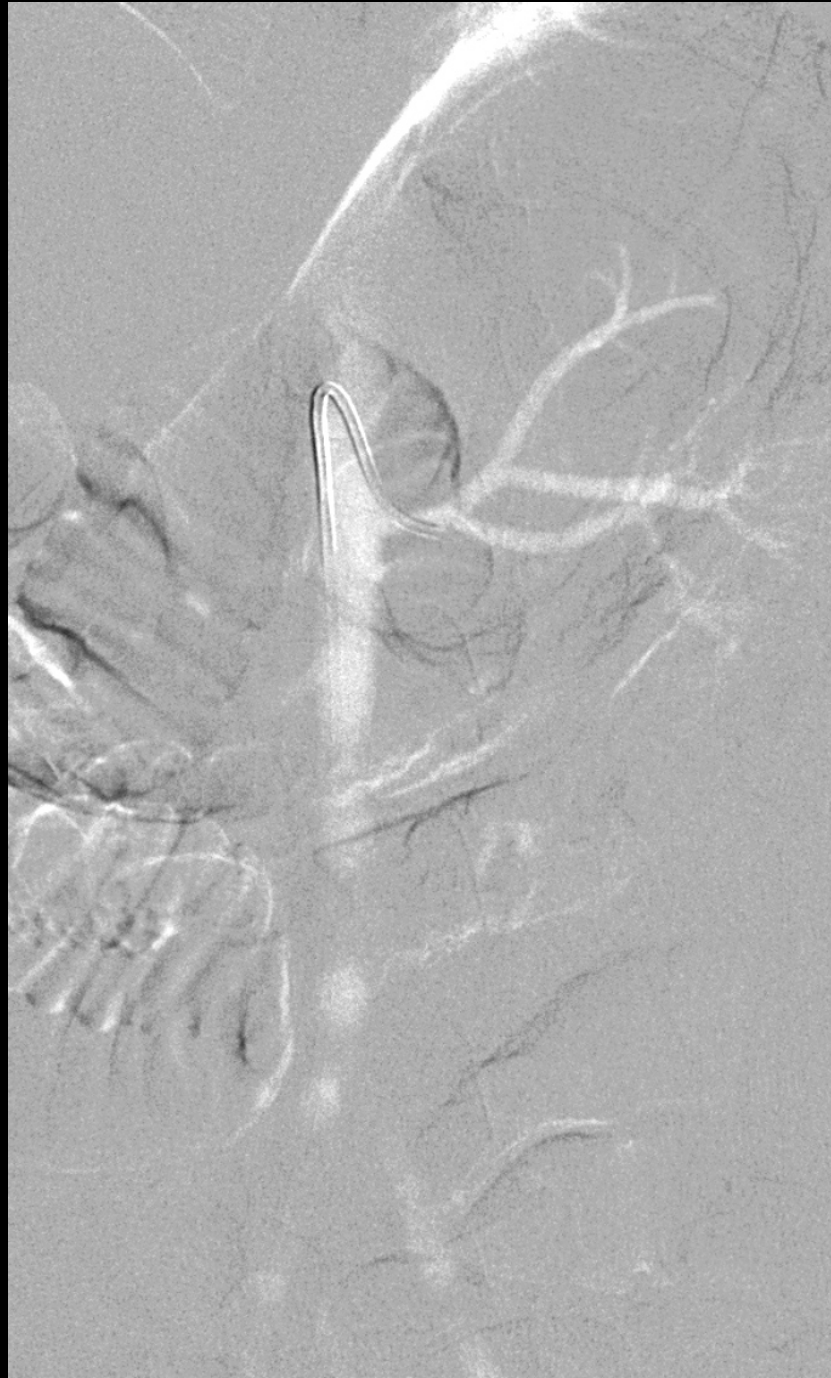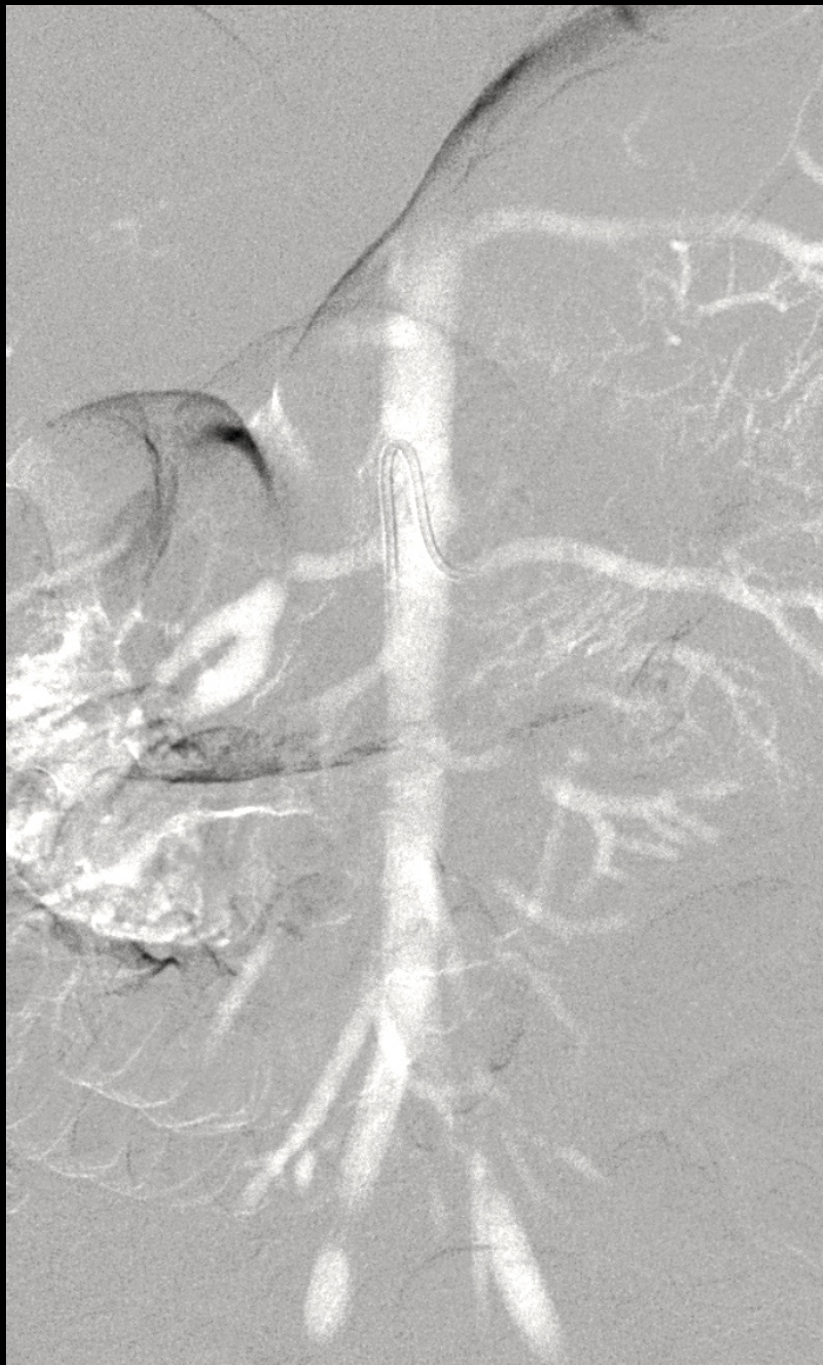
- **Reflux - can opacify the entire vessel including ostium for more precise stent placement**
- **Can inject between guide cath and catheter or wire and catheter to check placement without compromising position for PTA and stenting**
- **Microcatheter injections for easy opacification**
- **Can perform repeated injections without the fear of renal failure**

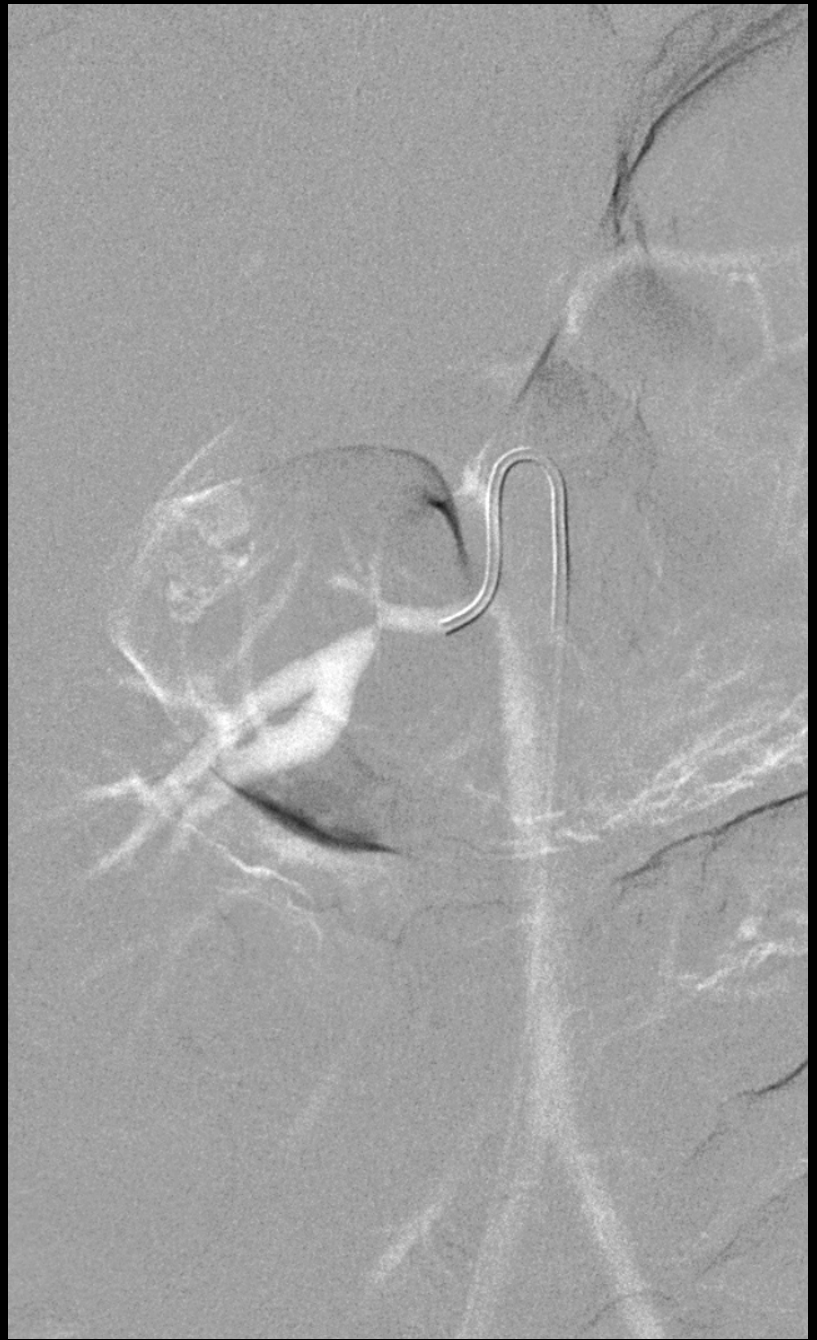
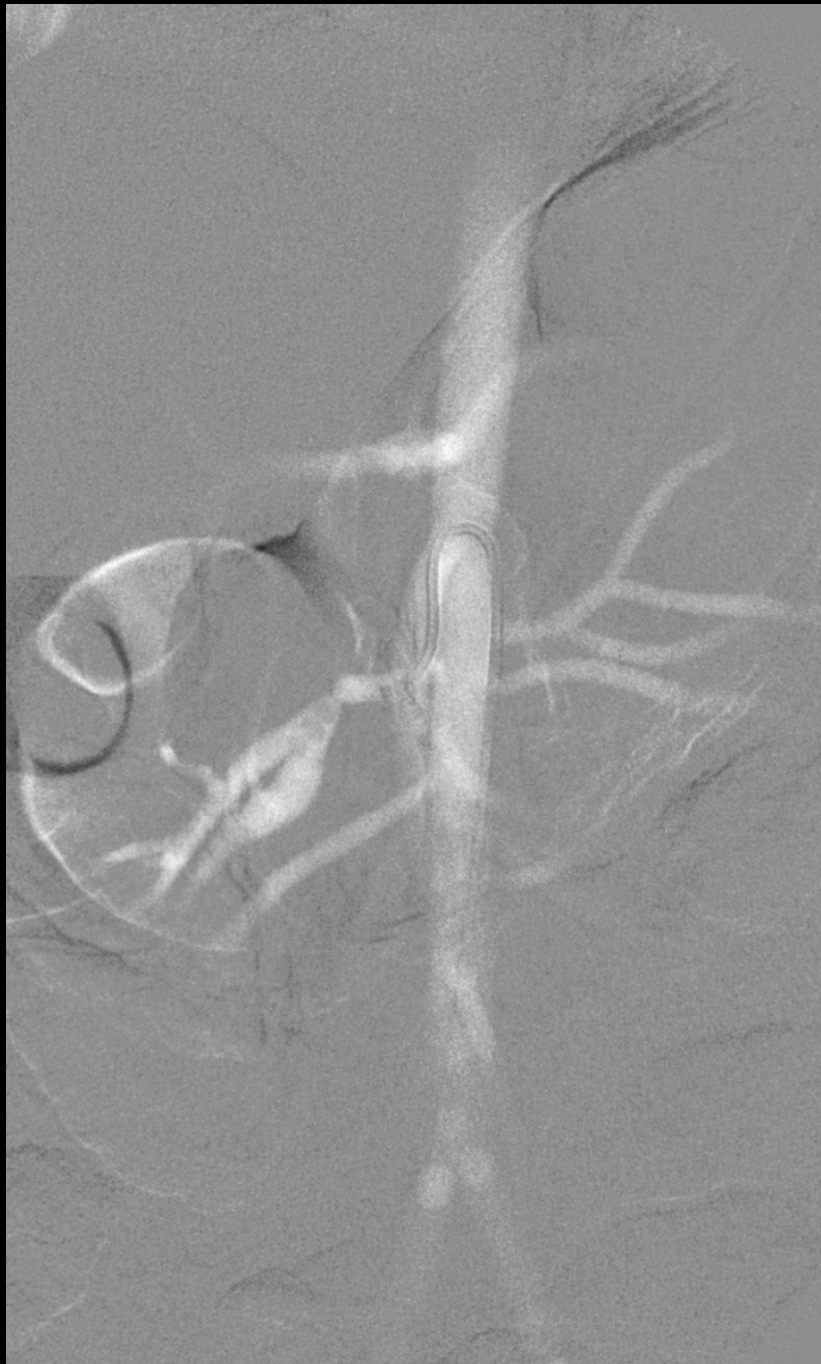
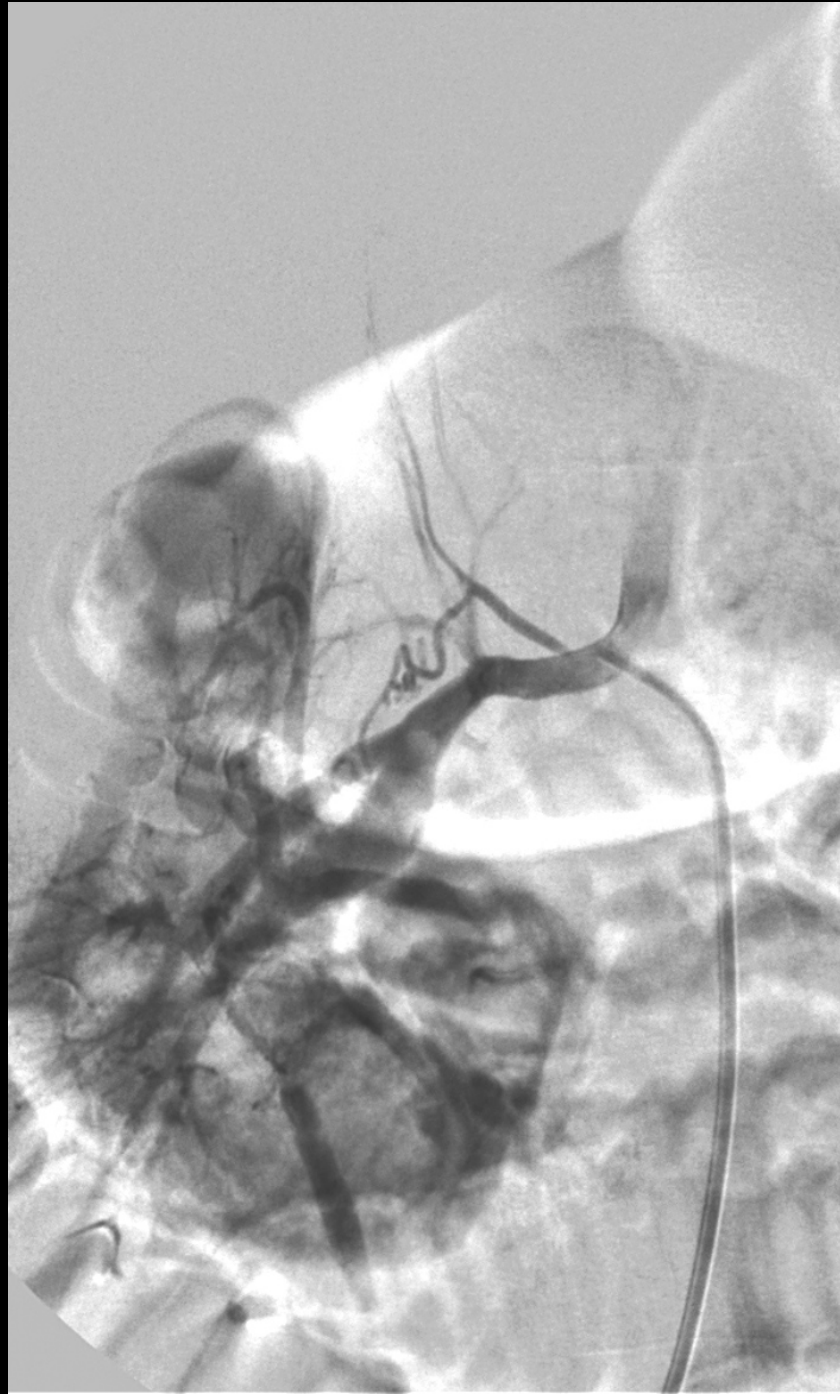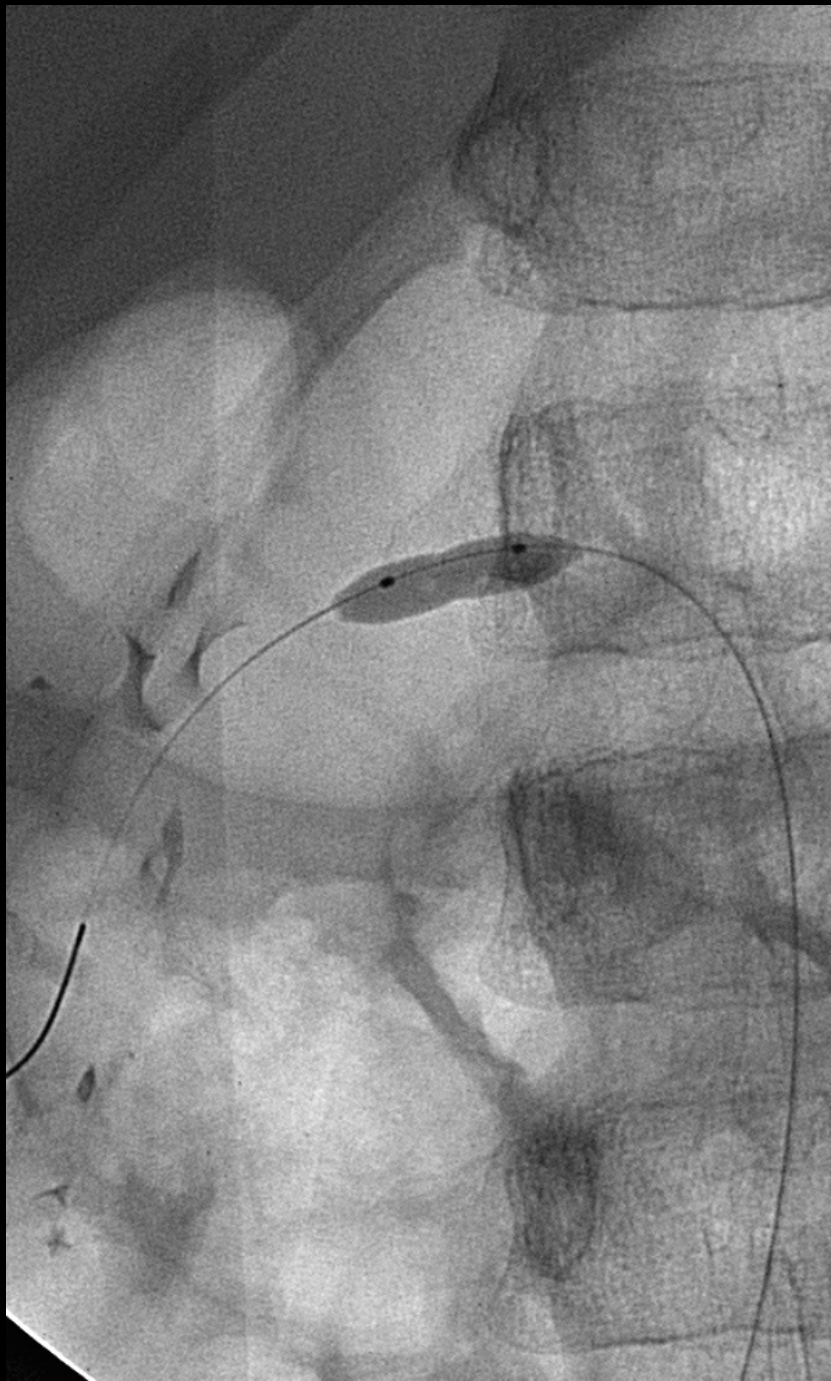




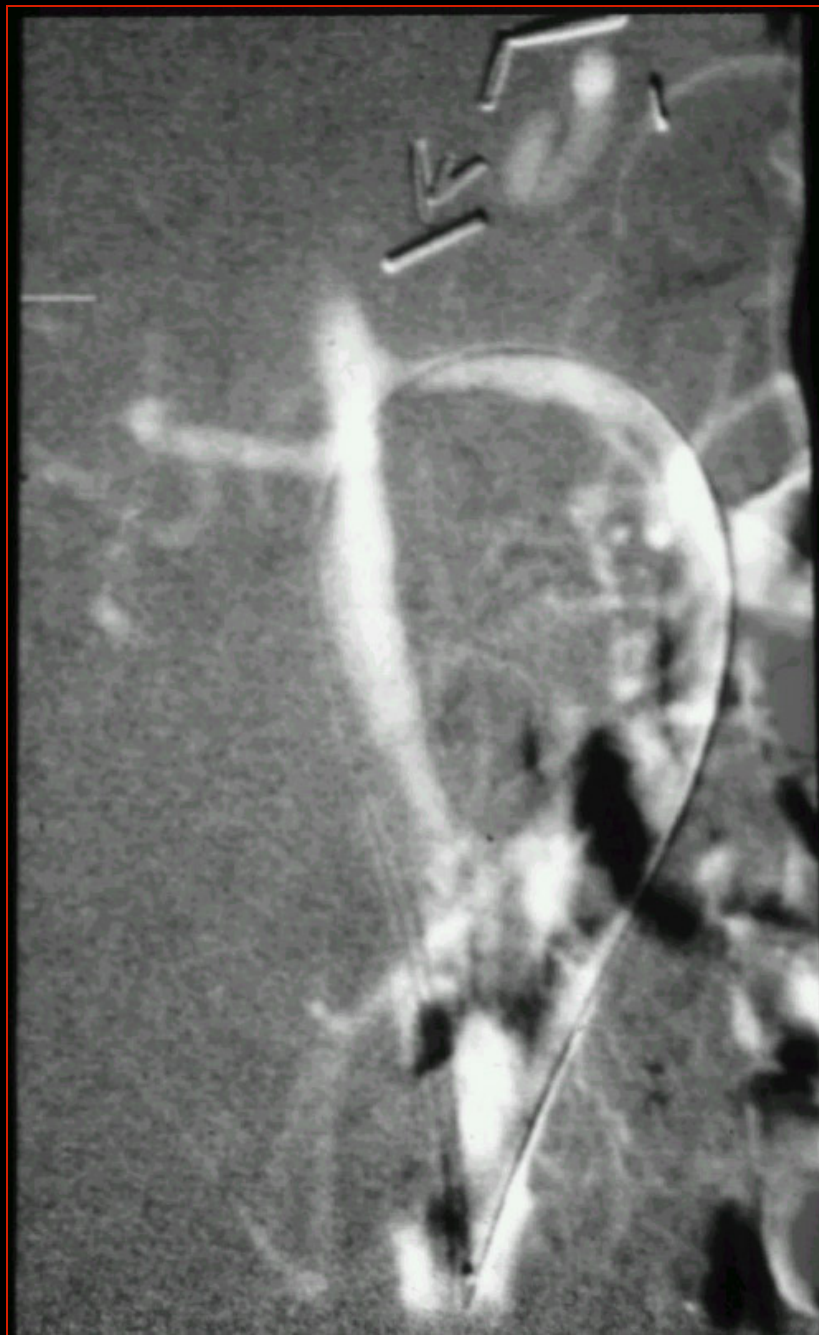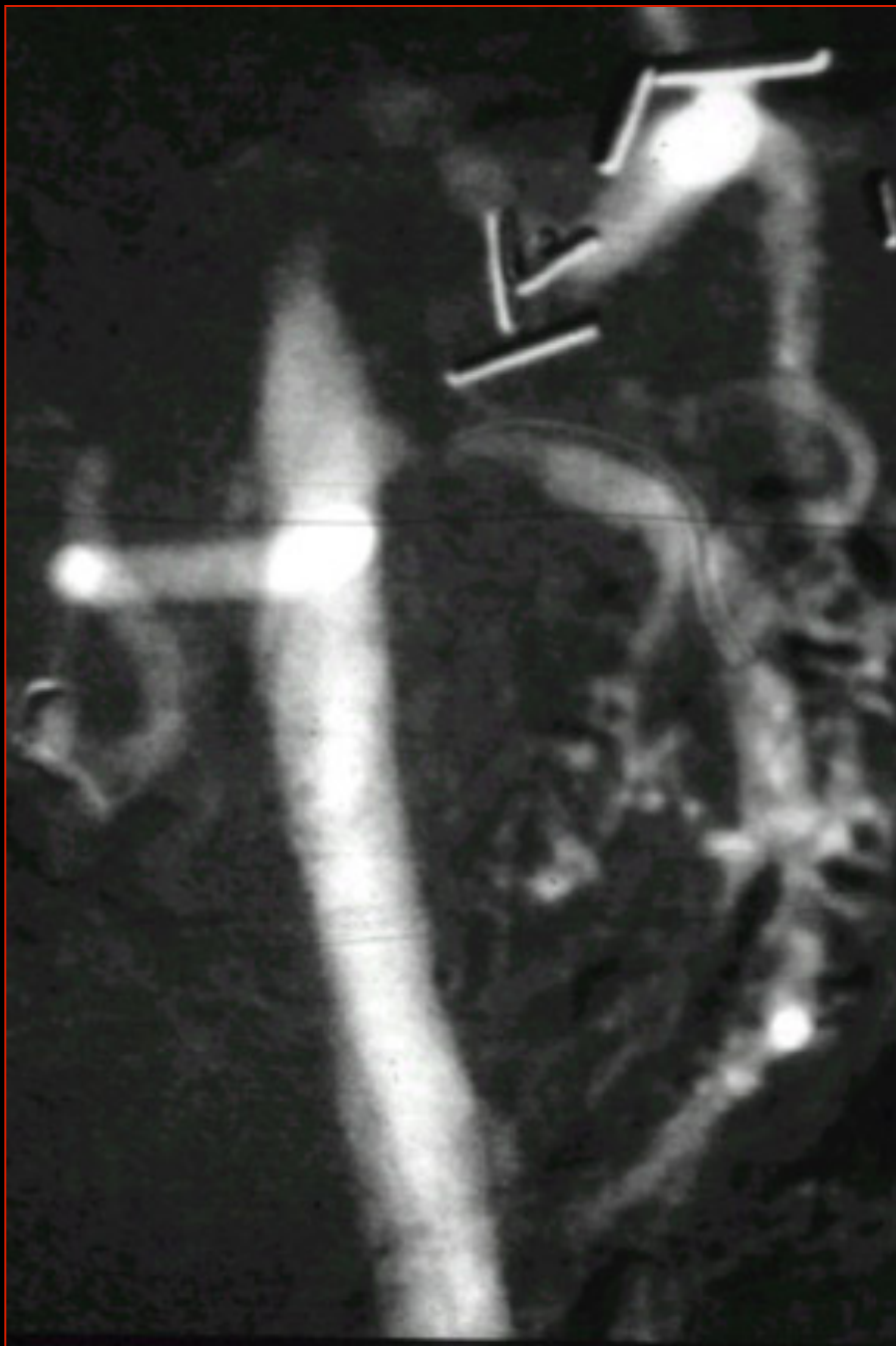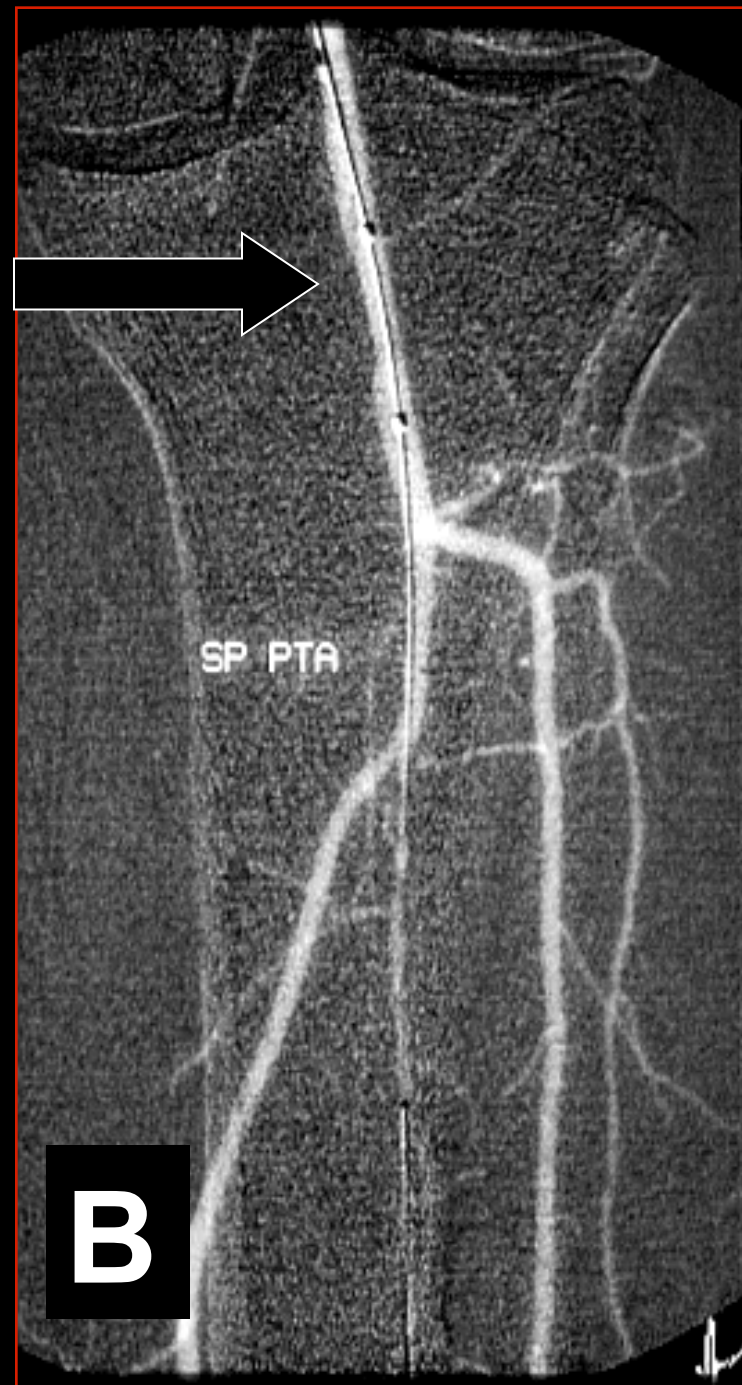
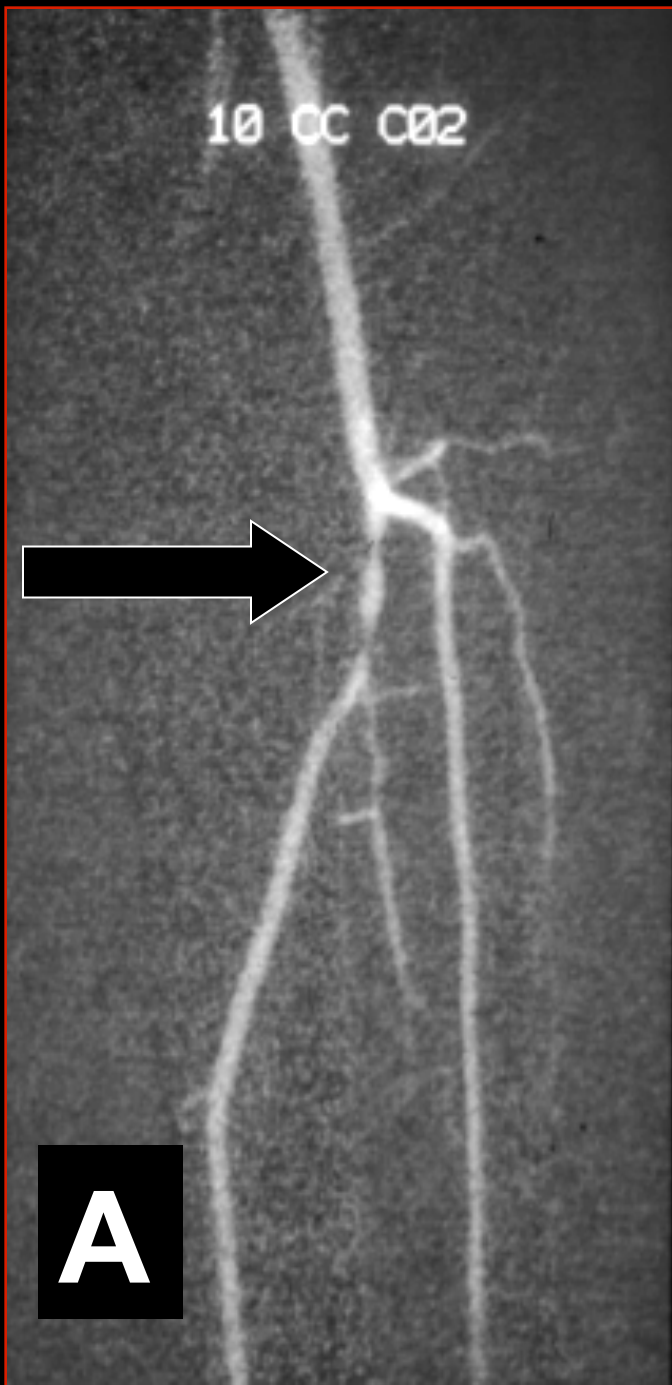


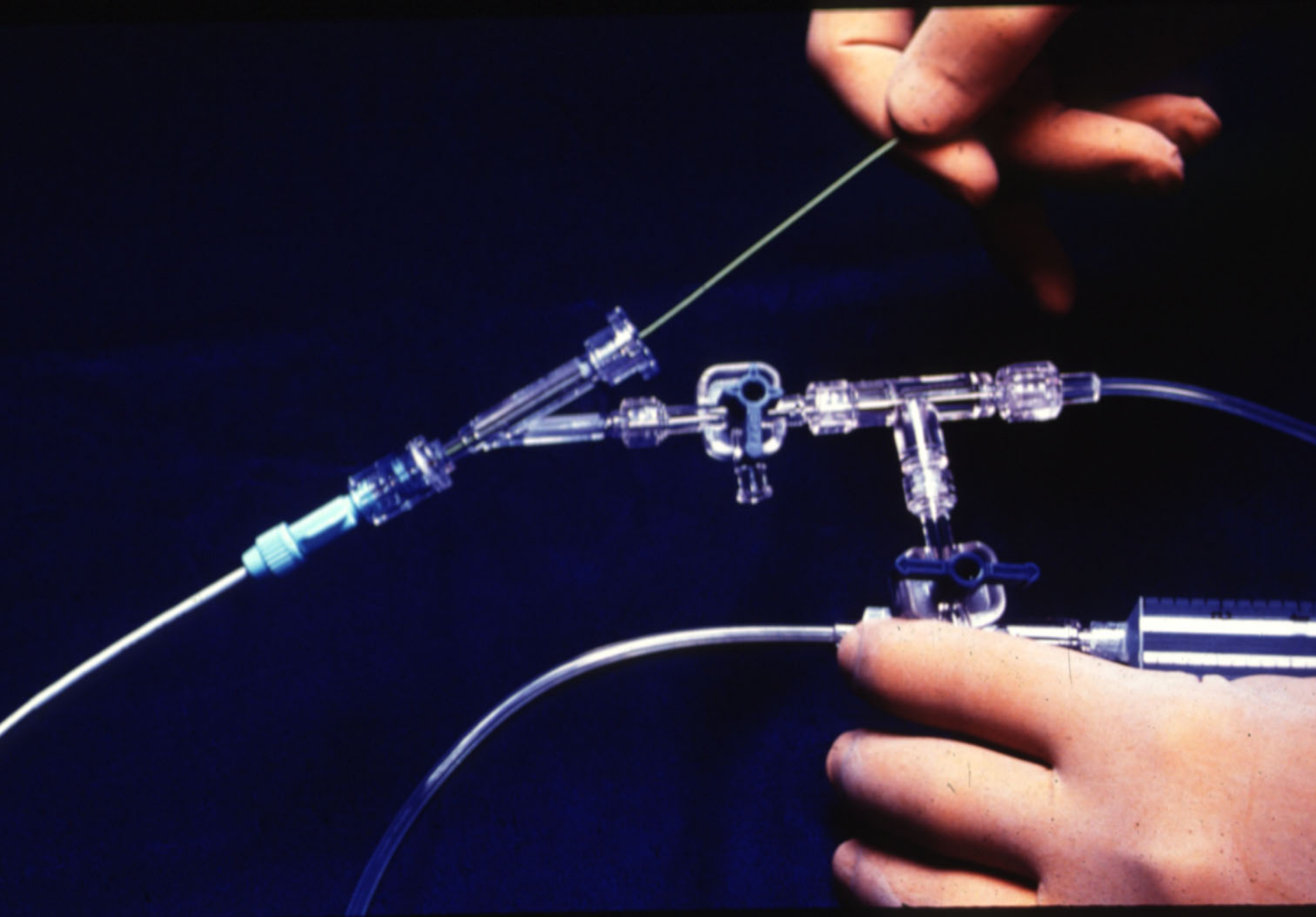






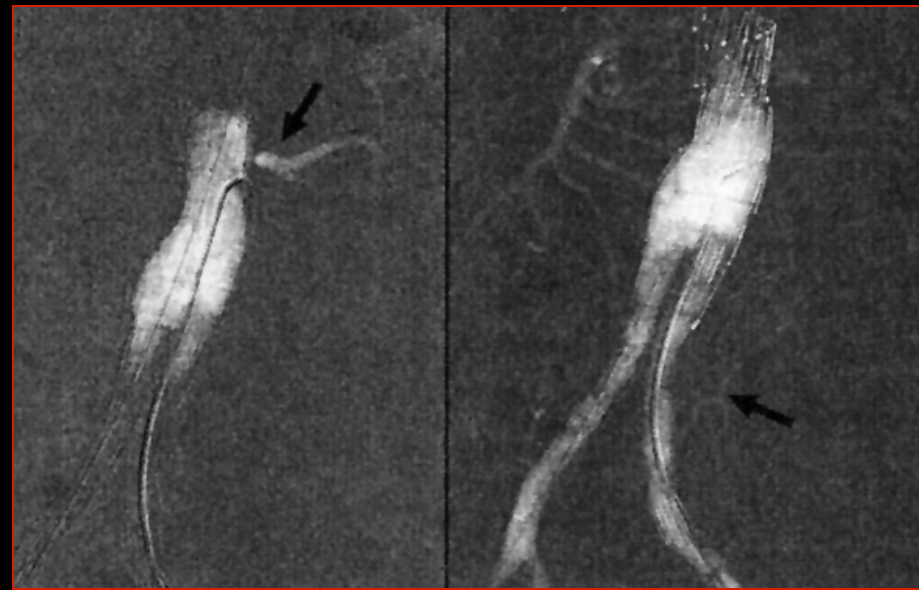
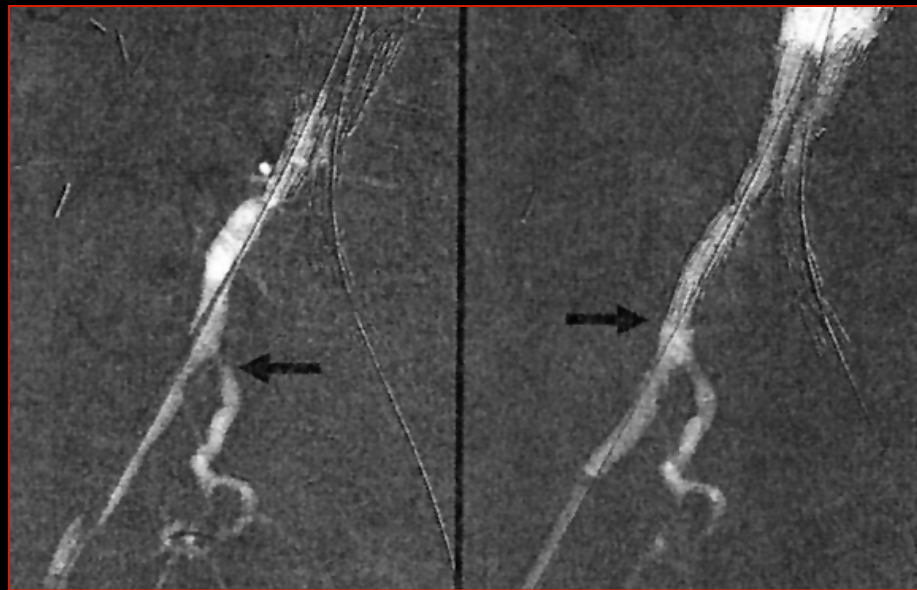
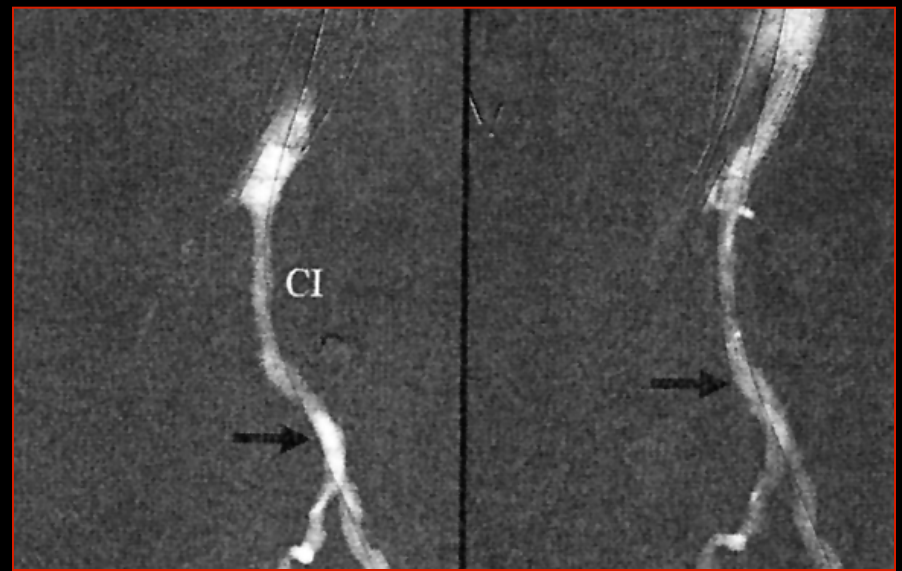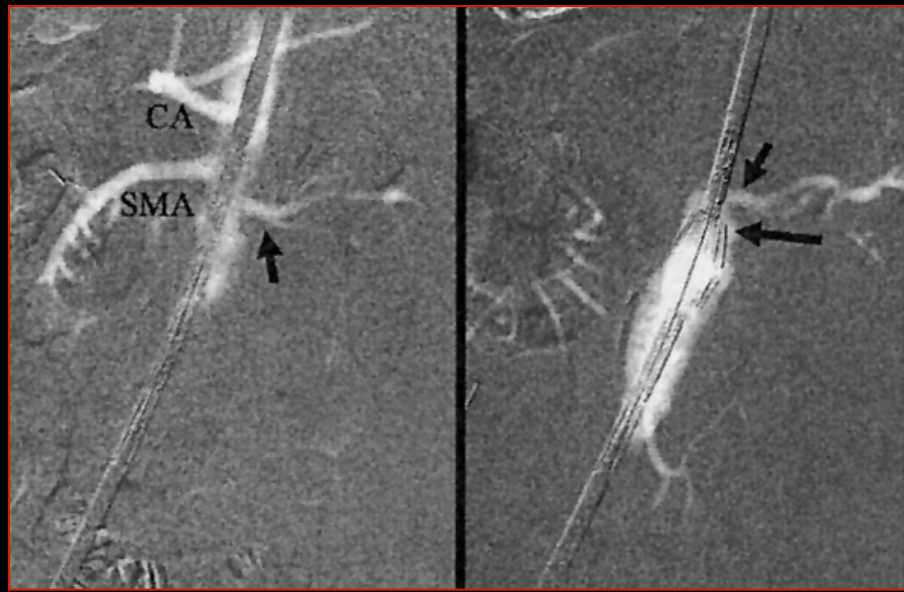






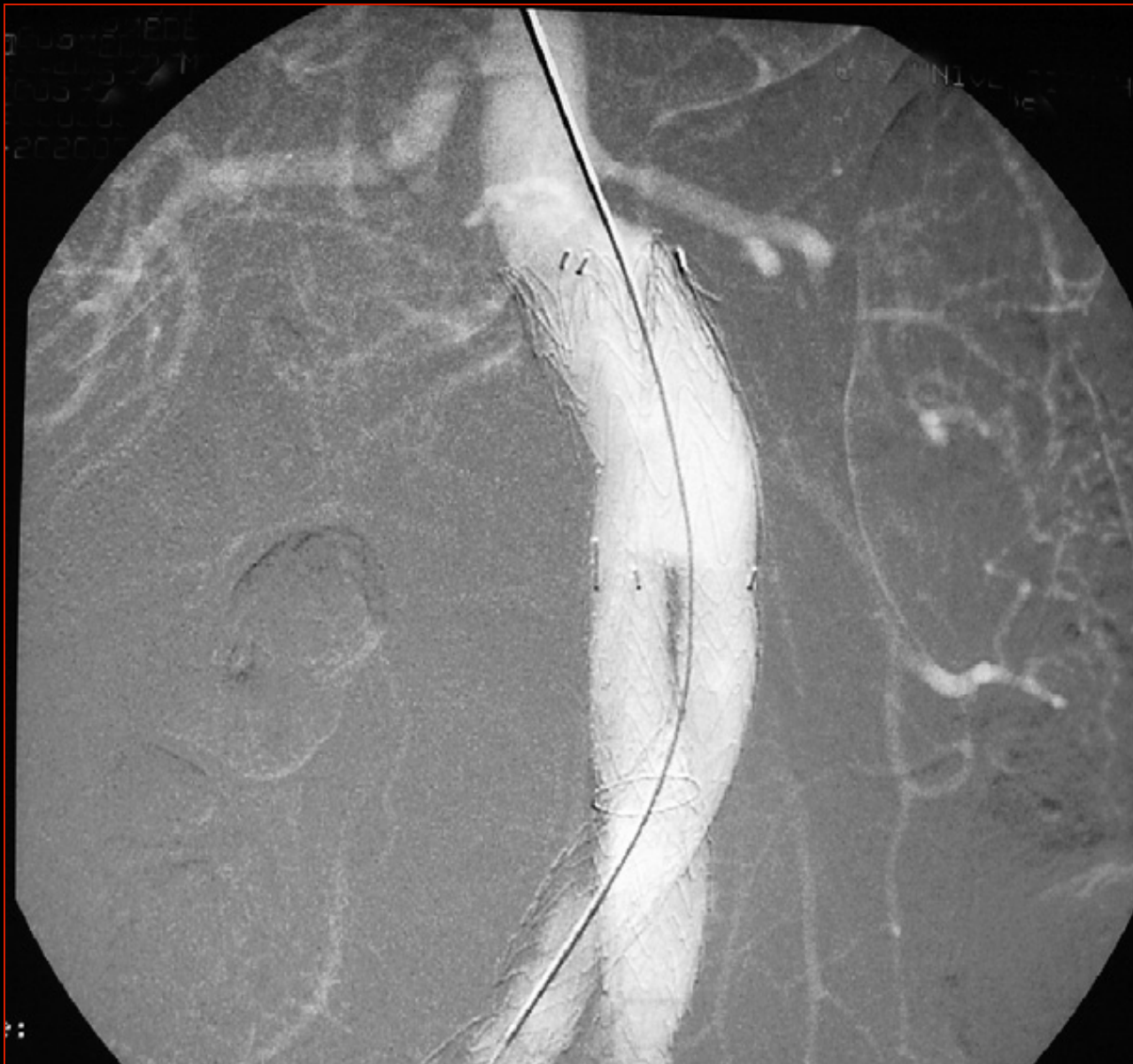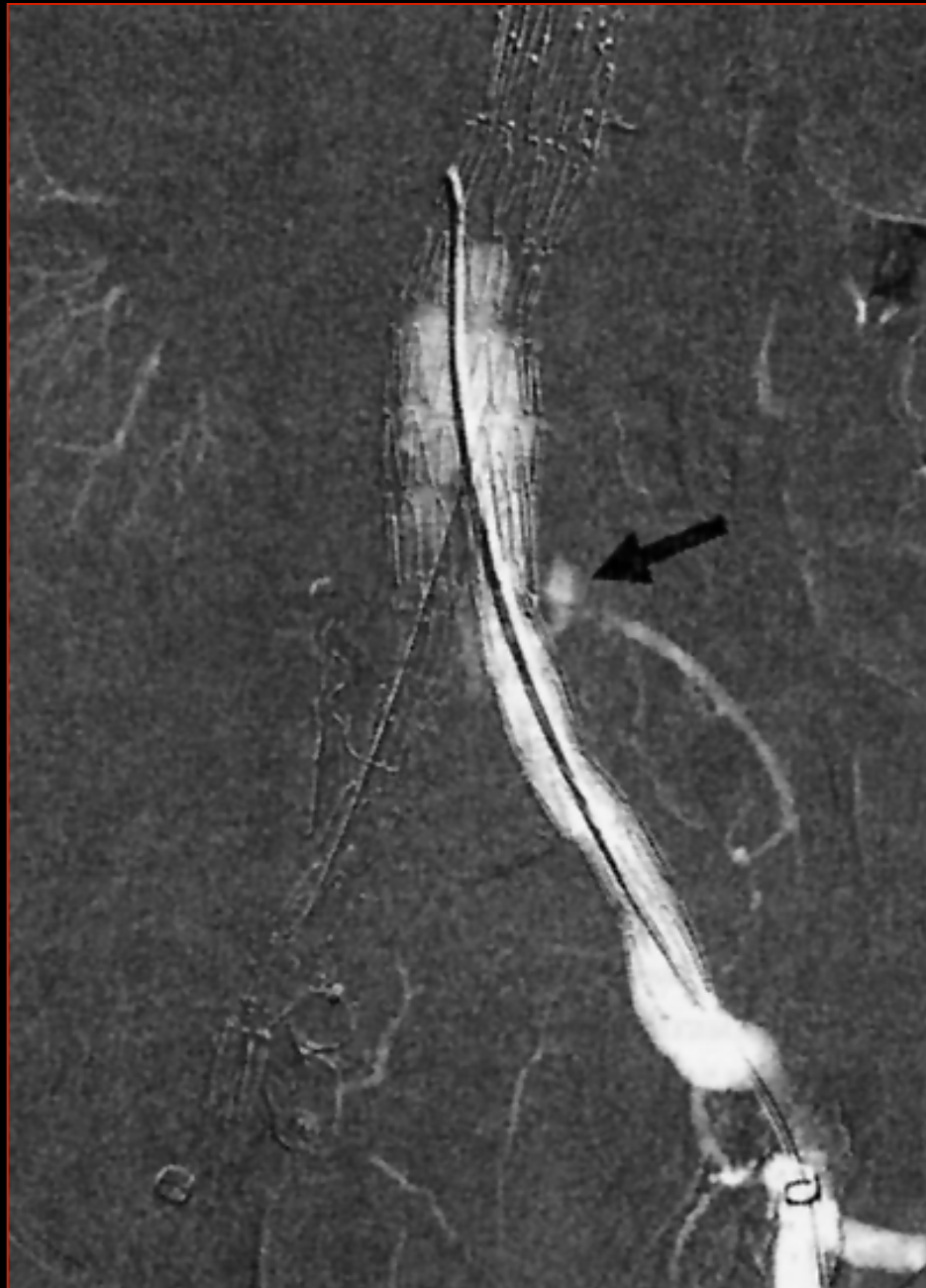# EVAR FACTS

- **Predisposition for renal dysfunction > open**
- **Occurs in pts with & without renal insufficiency**
- **ARF = 7 – 25% with & 2.5% without**
- **Associated mortality is 30 – 50%**







# Use of CO2 Angiography for Complex EVAR

J Cross, D Strring, L Morgan Rowe, K Ivancev, P Harris, T Richards

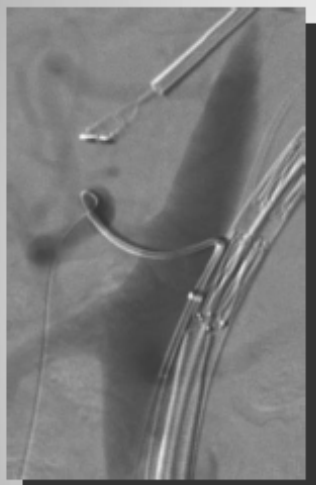University College Hospital, London



- Introduction:**
- Incidence of contrast induced nephropathy is proportional to volume of iodinated contrast used
  - Complex EVAR:
    - technically challenging requiring multiple images and larger volume of contrast
    - higher incidence of post op renal dysfunction
- Aim:**
- To assess role of CO2 as primary contrast agent in complex EVAR
- Methods:**
- Two Cohorts undergoing branched or fenestrated EVAR were compared :
- Cohort 1 Iodinated contrast only  
Cohort 2 CO2 primary contrast
- Endpoints:** Renal function, Contrast volume, Radiation dose

**Results:**

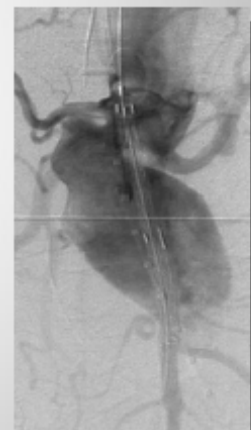	Iodinated contrast	CO2	P value
Change in creatinine (median)	28.5	9.5	<b>0.048</b>
Post op renal dysfunction*	13/41	8/27	N/S
Temporary dialysis	7/41	3/27	N/S
Vol. Iodinated contrast (median)	226.25mls	75mls	N/S
Radiation dose	52005 Gy	41836 Gy	N/S



CO2 angiography

**CONCLUSION**

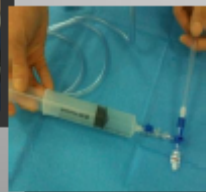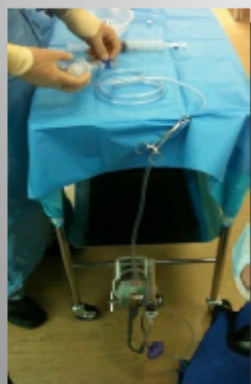
- Useful adjunct for complex EVAR
- Allows 'unlimited' images
- Renal dysfunction likely to be multifactorial
- Significant reduction in the median creatinine difference



Iodinated Contrast

**Technique**

- Lab grade CO2
- Standard cylinder attached to filter and 3 way tap
- Attach 50 ml syringe with floswitch to 3 way tap
- Avoid air contamination and fill using cylinder pressure
- Manually compress syringe of CO2
- Rapidly inject gaseous CO2 into aorta in 30-50ml aliquots



Floswitch

DEMOGRAPHICS	Iodinated contrast	Primary CO2
Male	32	22
Female	9	5
Median age	75 yrs	74 yrs (P=0.15)
Age range	66-85	68-86
Median baseline creatinine	96	102 (P=0.21)

# **CLASSIC CONTRAST ASSOCIATED NEPHROPATHY RISKS**

- **Diabetic nephropathy**
- **Myeloma**
- **Large volume contrast**
- **Intravascular volume depletion**

# **INTERVENTIONAL ONCOLOGY**

- **Comorbid conditions predisposing to CIN**
  - **Renal insufficiency, Diabetes, Hepatic insufficiency**
- **Peri –procedural medications can predispose to renal failure**
  - **NSAIDS**
- **Post embolization syndrome can deplete intravascular volume**
- **Many embolization procedures require high volume contrast**
- **Tumor lysis syndrome can induce renal failure**
- **Rare - non-target embolization of kidneys**

# INTERVENTIONAL ONCOLOGY

- **Prospective study 140 patients for HCC**
- **Pre procedure creatinine 1.1 +/- .2**
- **8.6% developed ARF**
- **2.8% irreversible renal failure (all diabetics)**
- **ARF correlated with the number of procedures, severity of liver disease and presence of post-embolization syndrome**

# **INTERVENTIONAL ONCOLOGY**

**1. Vessels less than 10 mm**

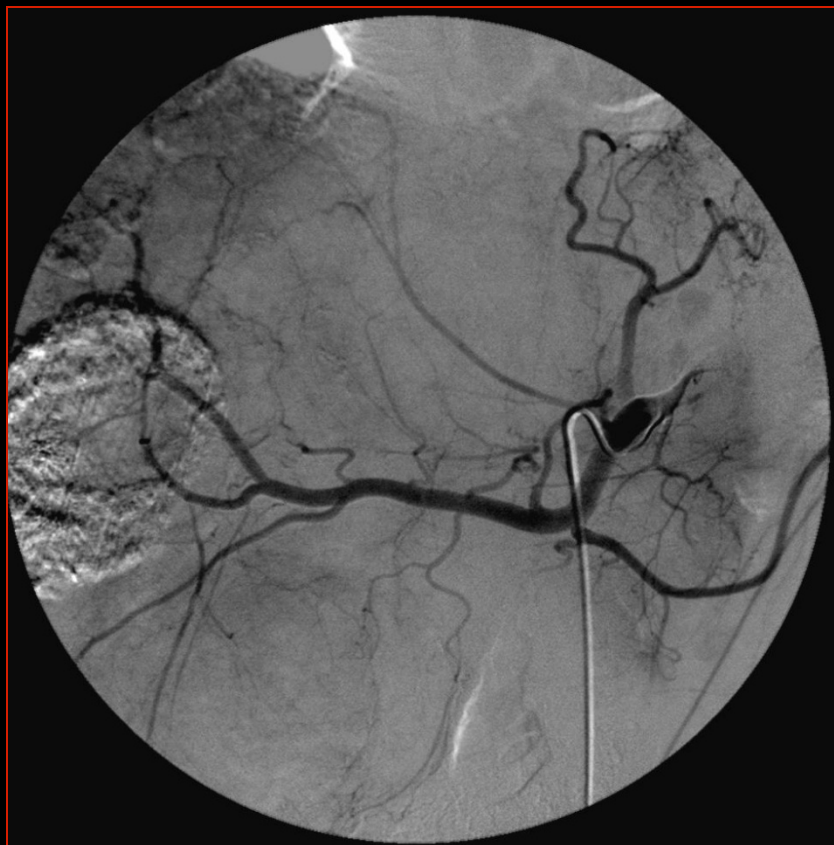**2. Low viscosity**

**Tumor vessel visualization**

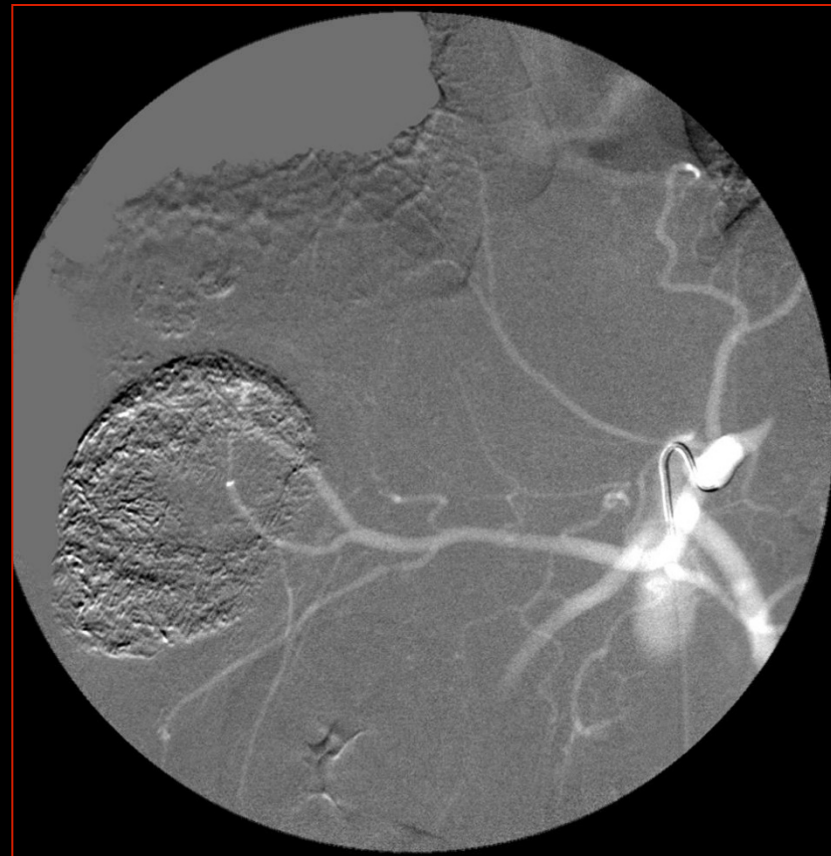**Ease of use with microcatheters**

**3. Central reflux**

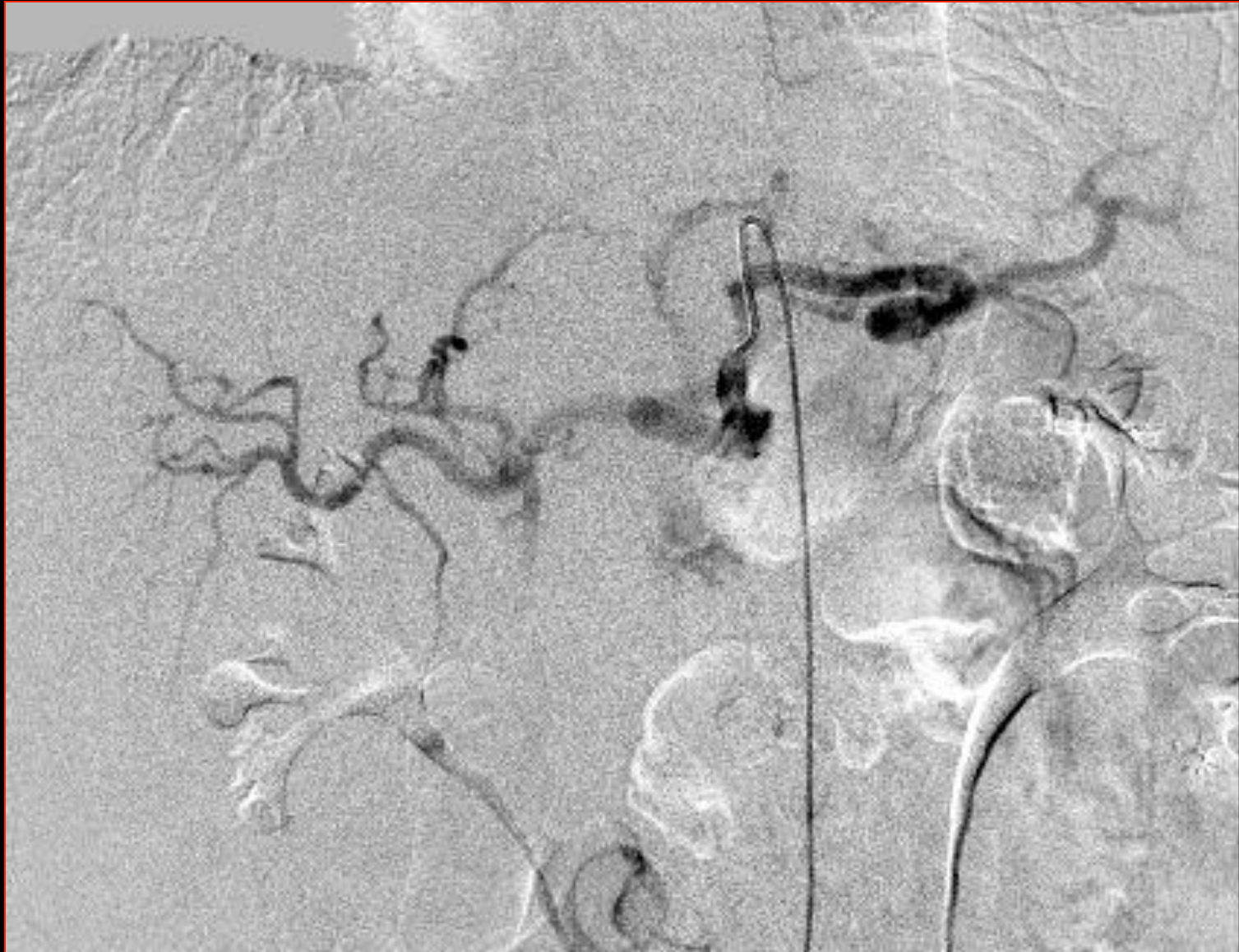
# Chemoembolization

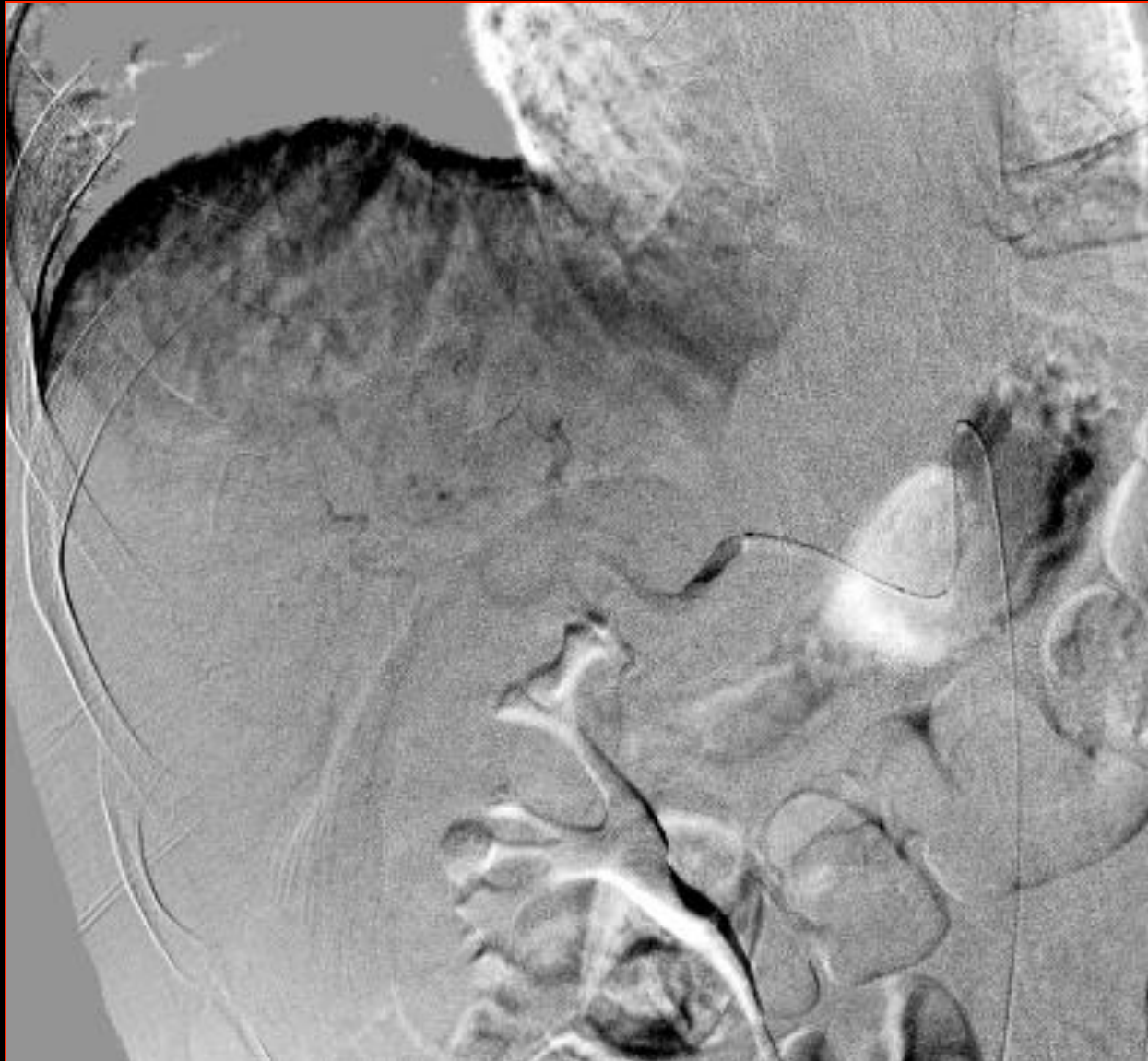

**Contrast**

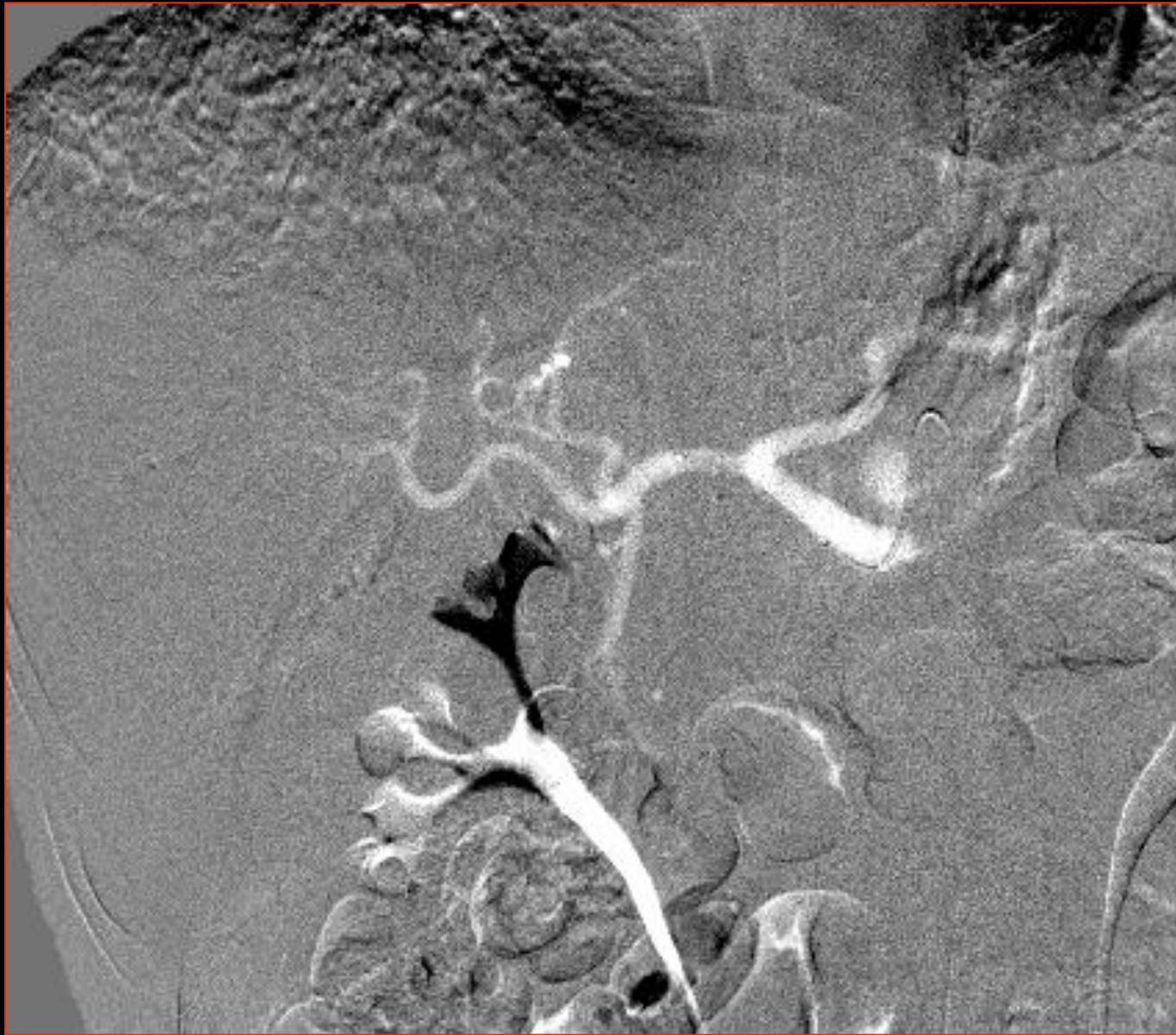

**CO<sub>2</sub>**



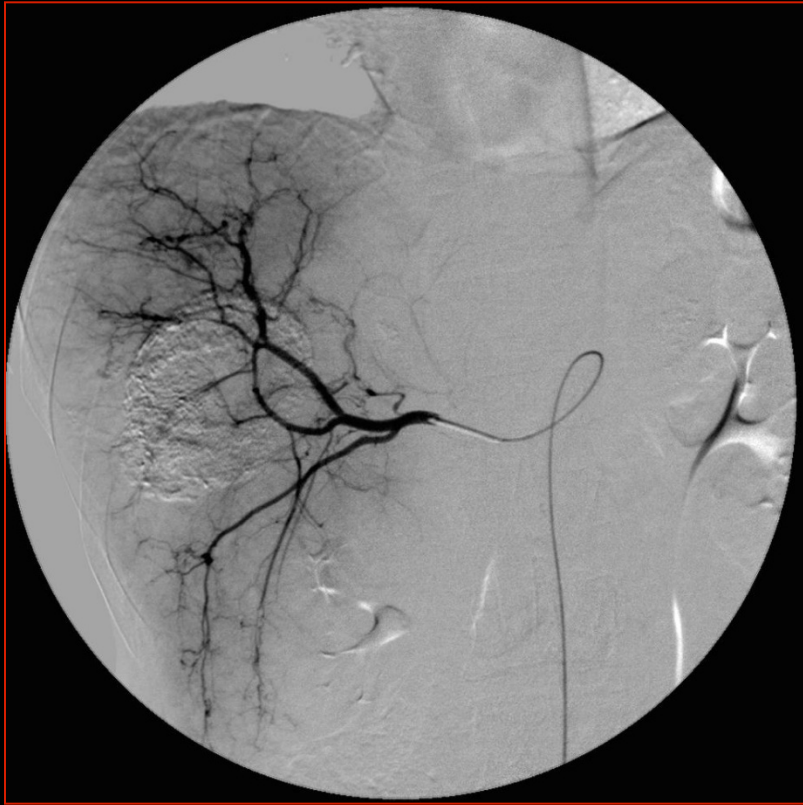

**Poor opacification attempting contrast through microcatheter<sup>168</sup>**

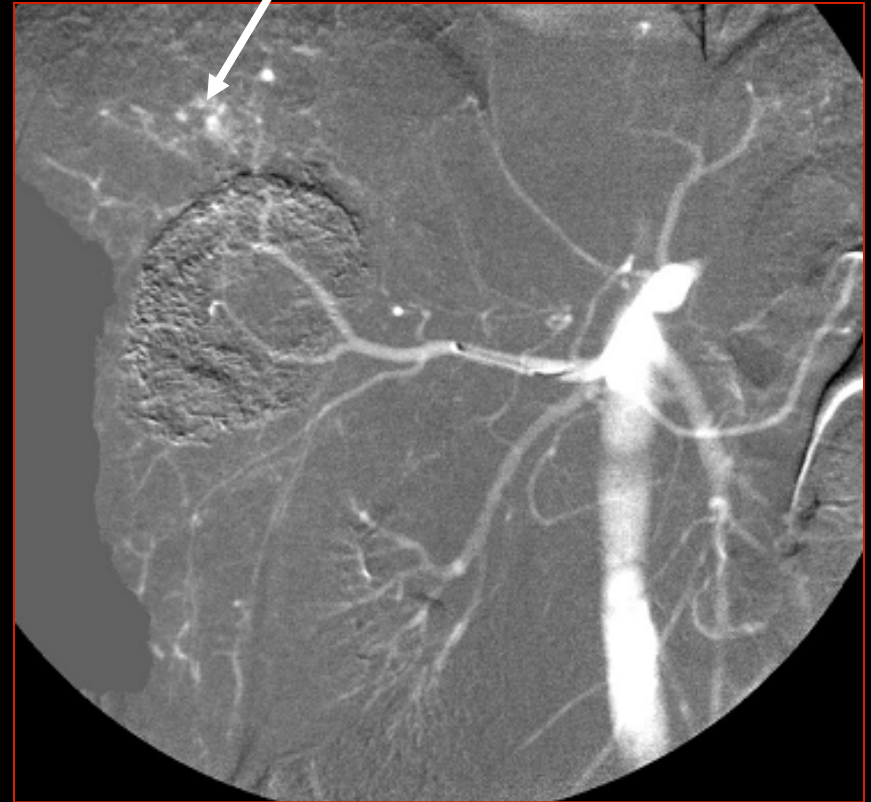

**Easy opacification due to low viscosity of CO2**

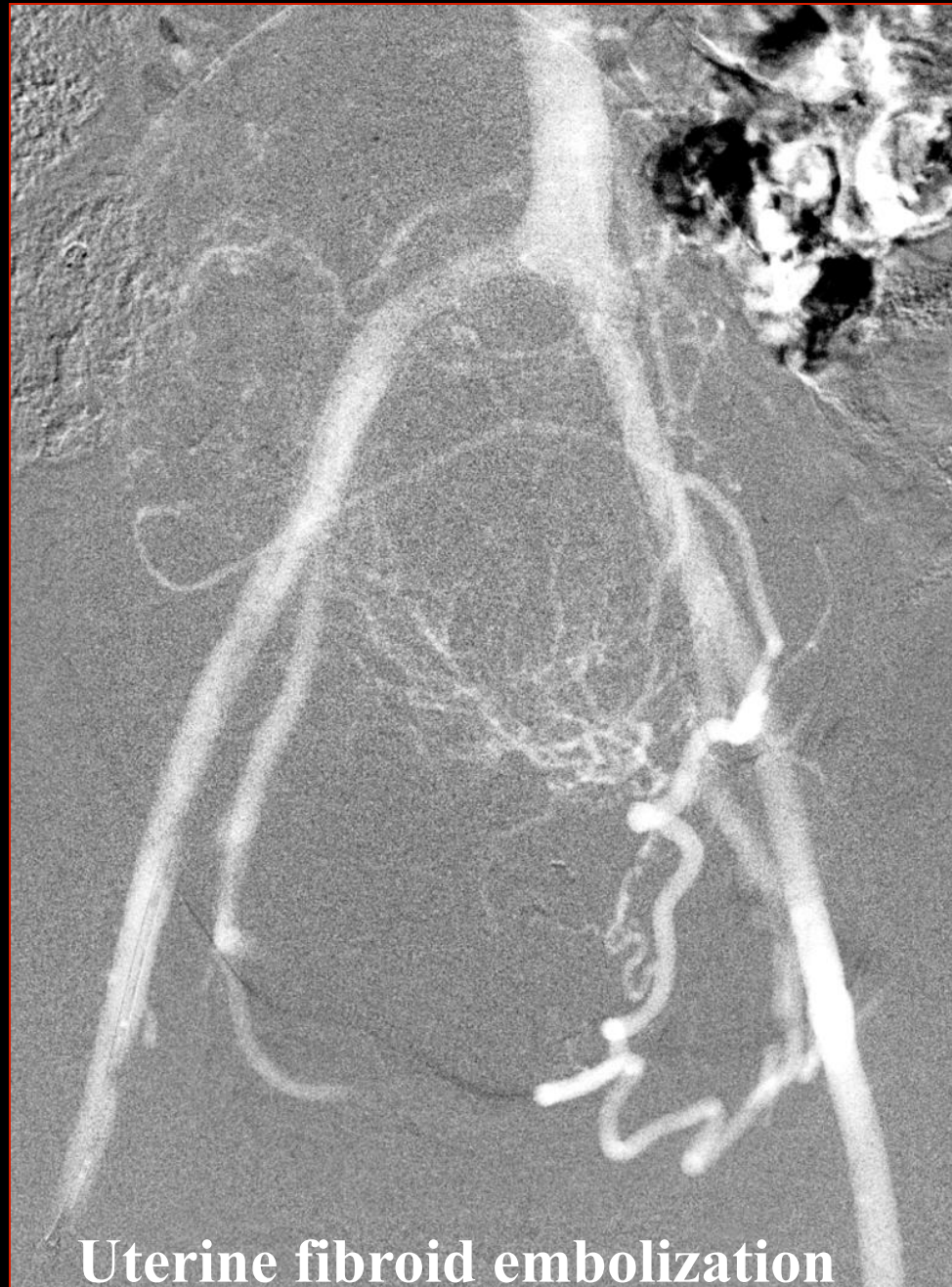**Tumor vessels**



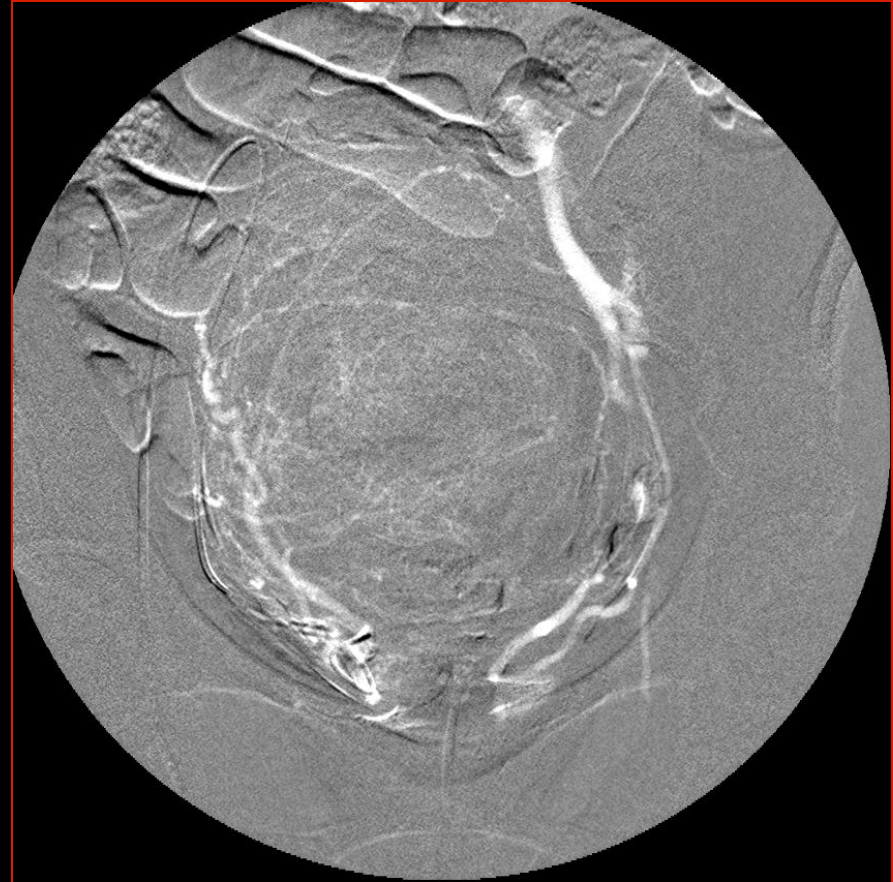
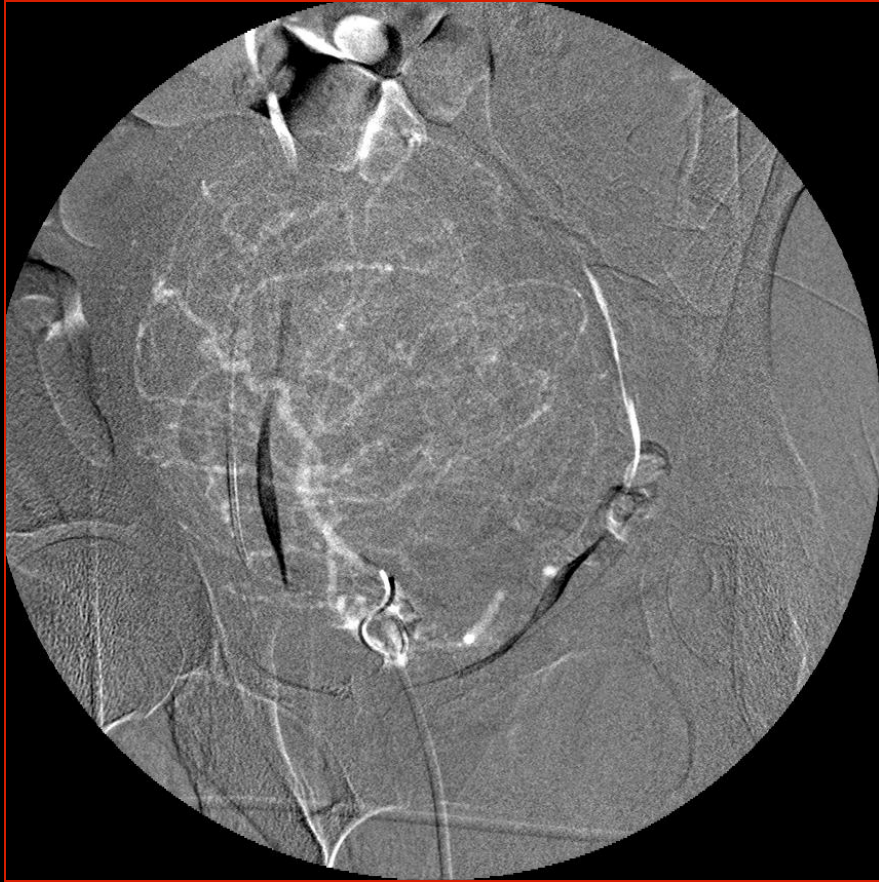**Contrast**

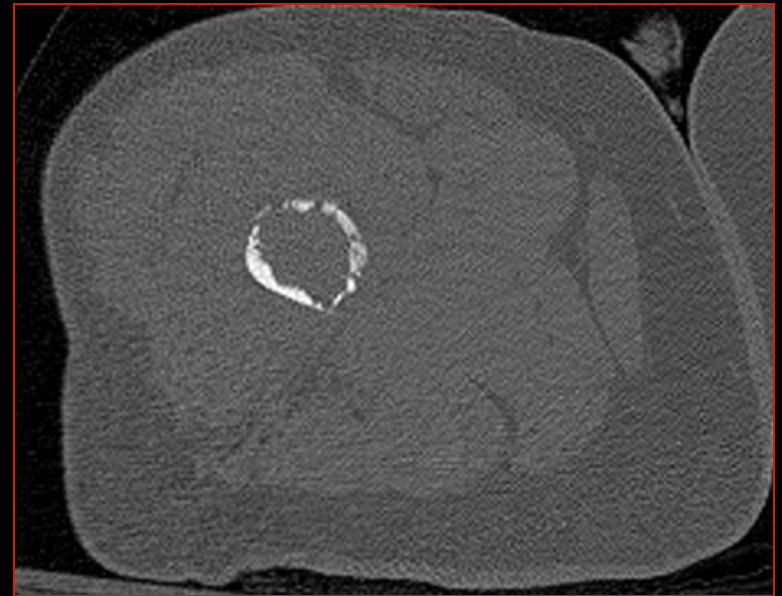
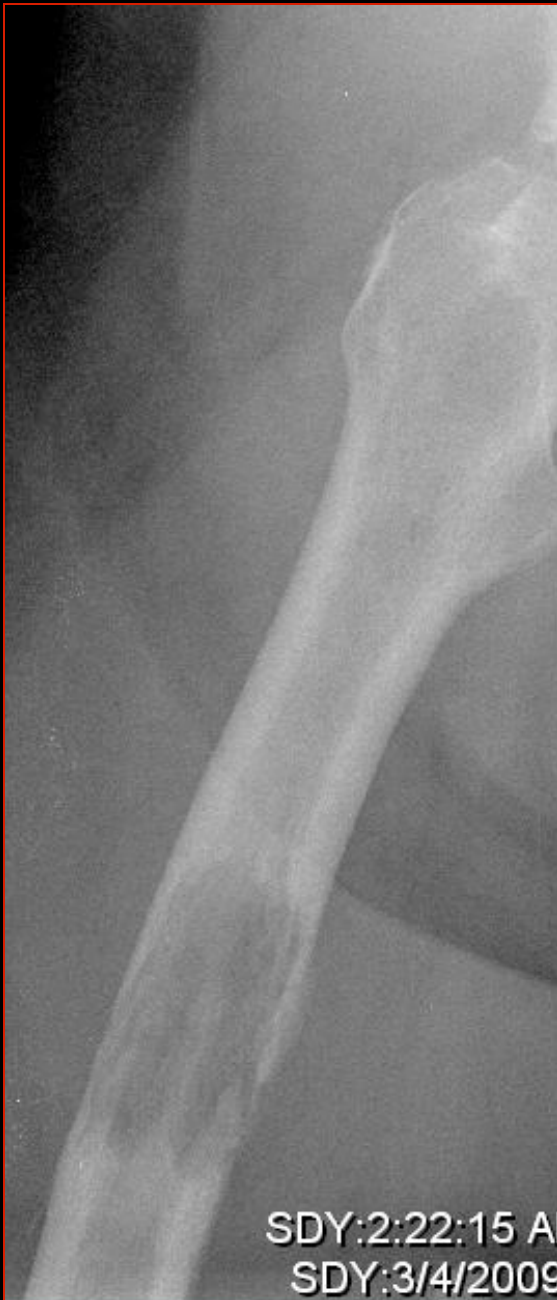

**CO2**

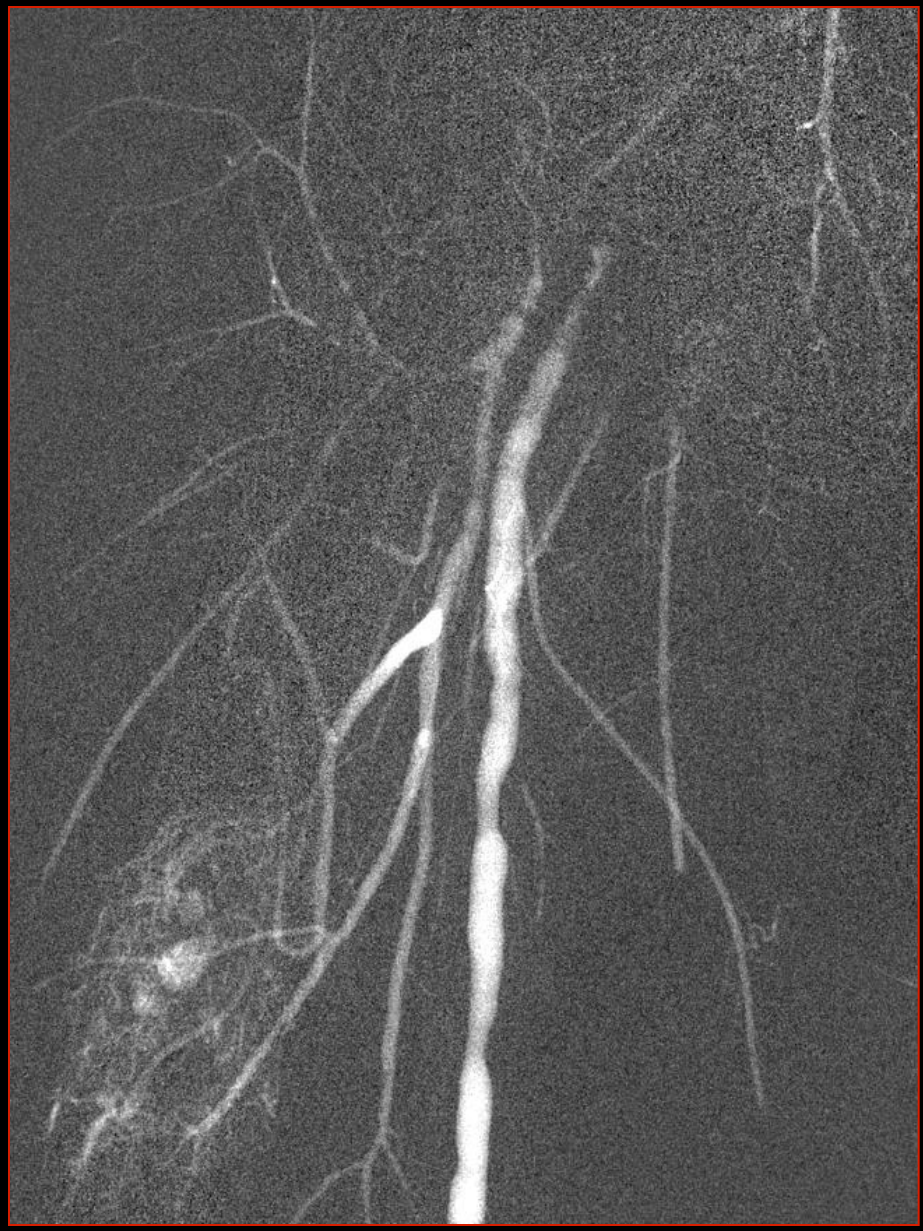
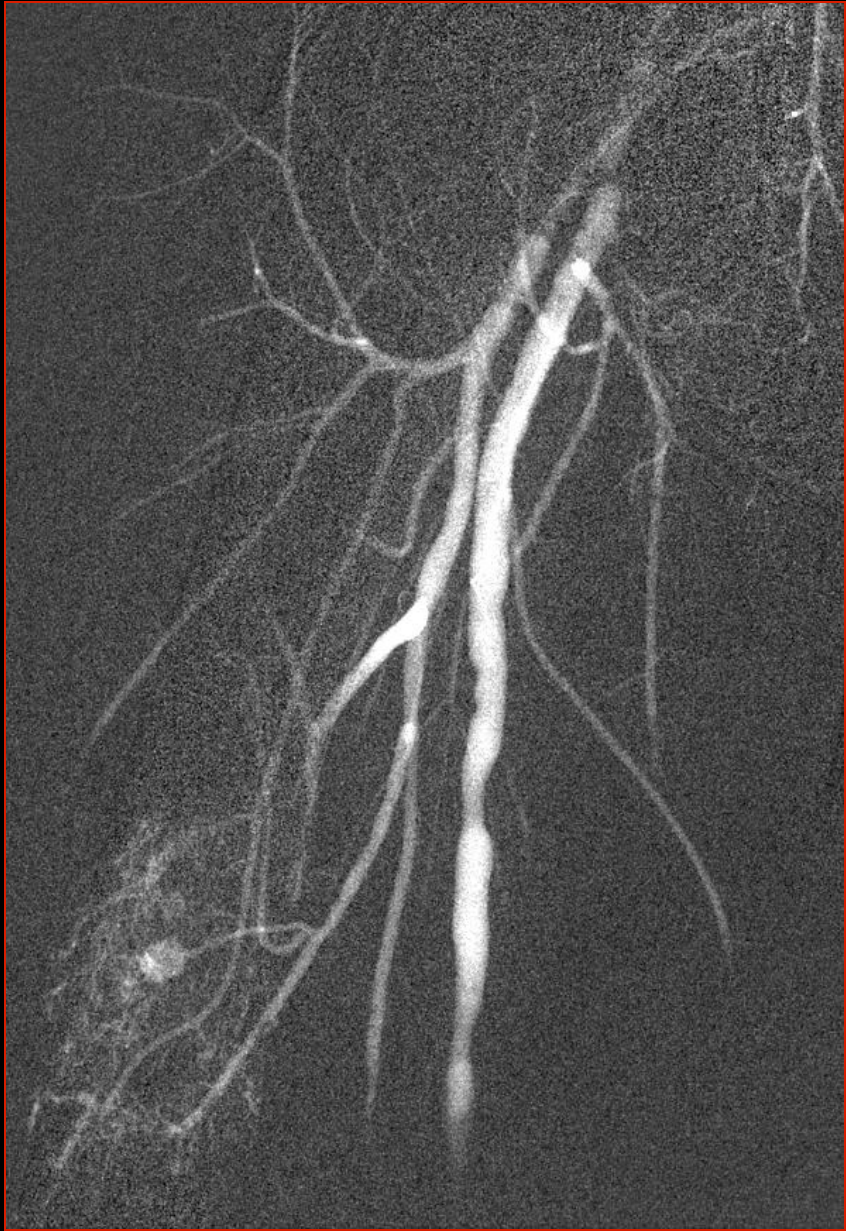
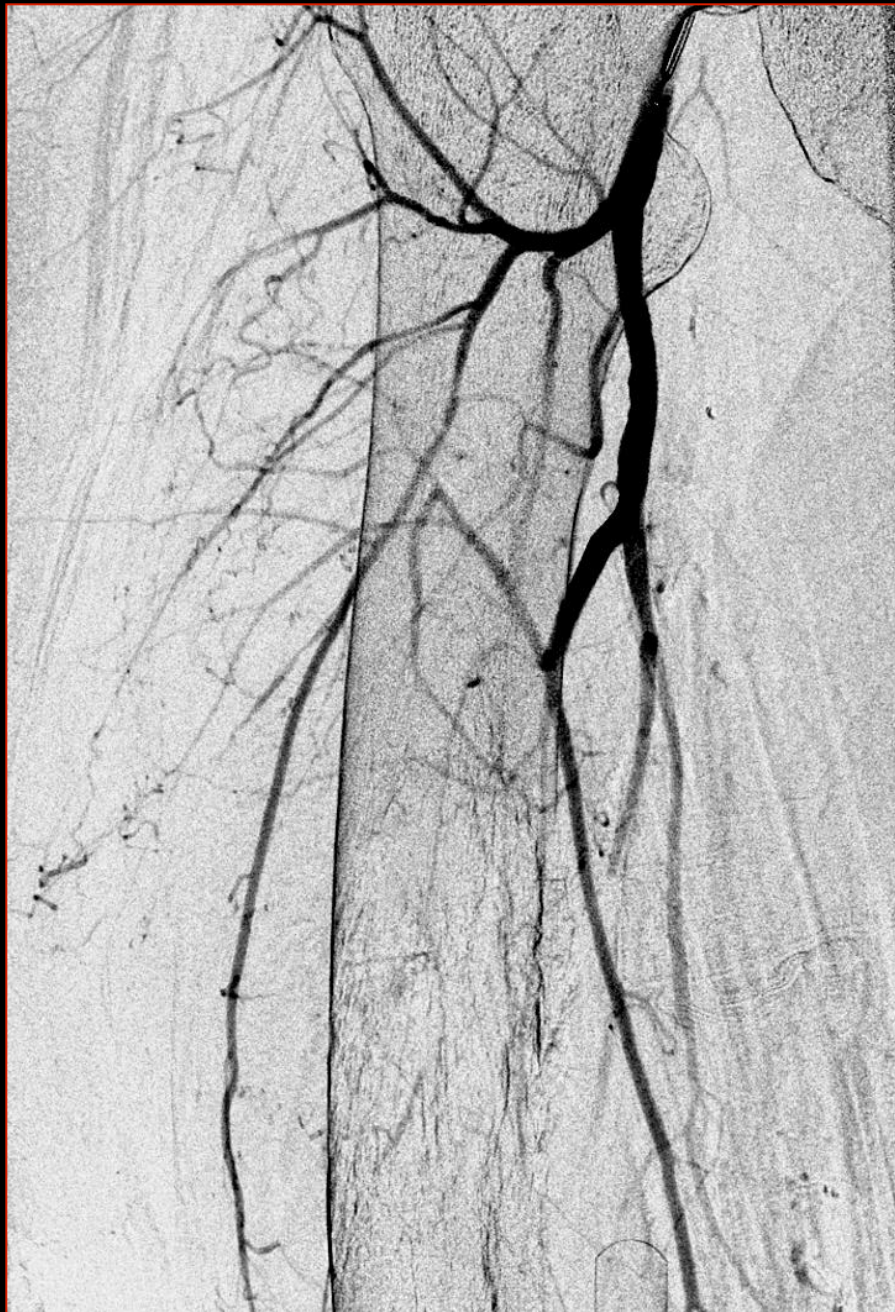**Uterine fibroid embolization**





## Renal cell carcinoma metastasis





# PORTAL VENOGRAPHY

- **Diagnostic:**
  - **When CT/MR is not sufficient or feasible (commonly pediatrics)**
  - **Portal vein thrombosis**
  - **Portal vein stricture**
  - **Venous sampling**
- **Localization for intervention:**
  - **TIPS**
  - **Pre operative portal vein embolization**

# **CONTRAST WEDGED HEPATIC VENOGRAPHY**

- **Portal vein visualization 40 – 75%**
- **Main portal vein visualization 40%**
- **Direct portal venography correlation in only 10%**
- **Transient elevation of transaminases**
- **Parenchymal staining with contrast**
- **Parenchymal scarring and hemorrhagic infarction and congestion of lobules**
- **When peripheral rarely can result in capsular laceration hemorrhage and death**

Culp et al, JVIR 1999; 10:1265-1270

Castaneda-Zuniga et al, Radiology 1978; 126:53-56

# **CO<sub>2</sub> WEDGED HEPATIC VENOGRAPHY**

- **Portal vein visualization 83% (UF 86%)**
- **Direct portal correlation in 91%**
- **No parenchymal staining**
- **No scarring or hemorrhagic infarction or enzyme changes**
- **Potential small parenchymal hematomas**
- **CO<sub>2</sub> can linger in vein providing target**
- **Peripheral injection can still cause capsular laceration hemorrhage and death**
- **Intraperitoneal extravasation in 1.8%**
- **It is essential to avoid explosive delivery**

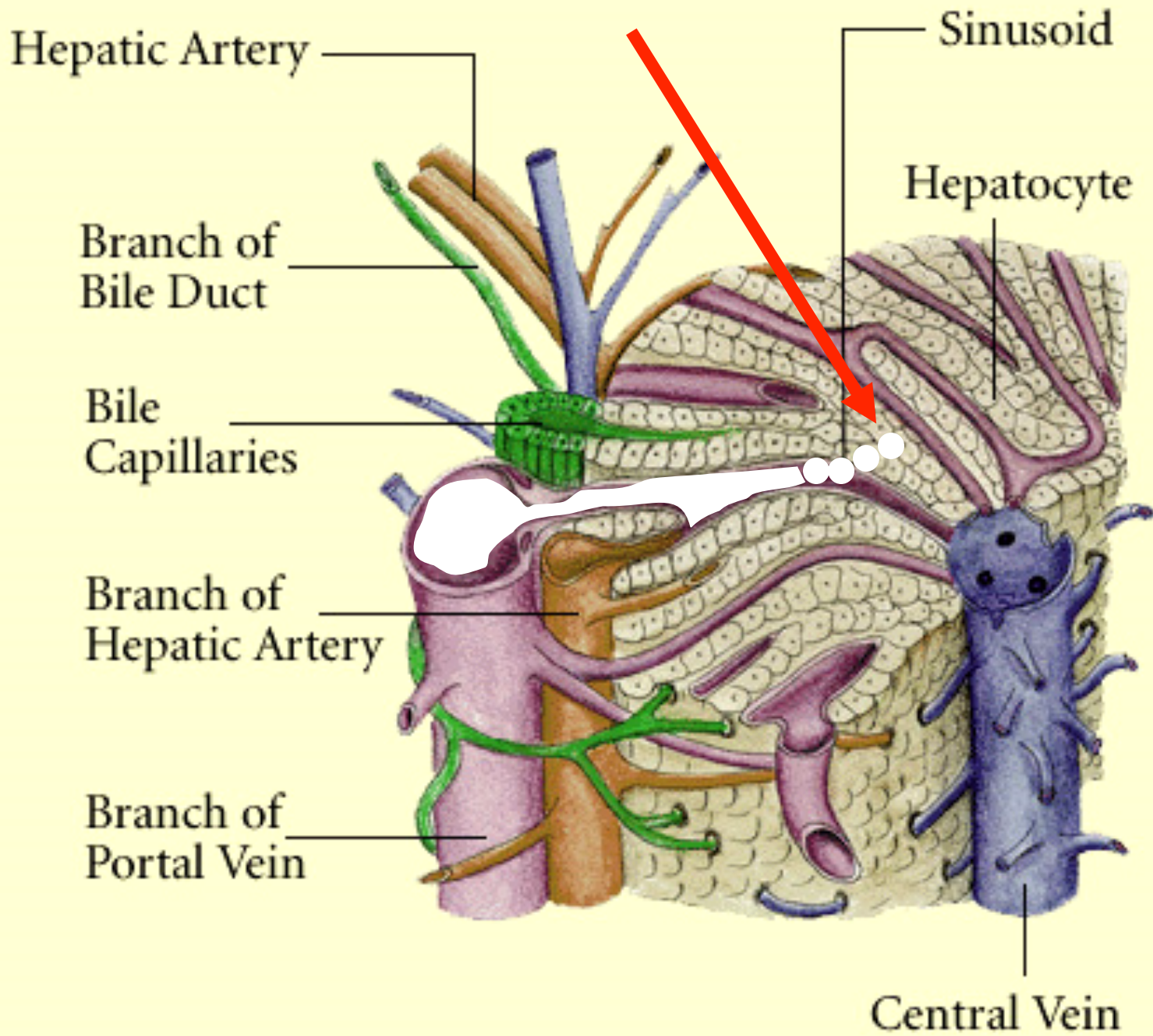
# **DIRECT INTRAPARENCHYMAL CO<sub>2</sub>**

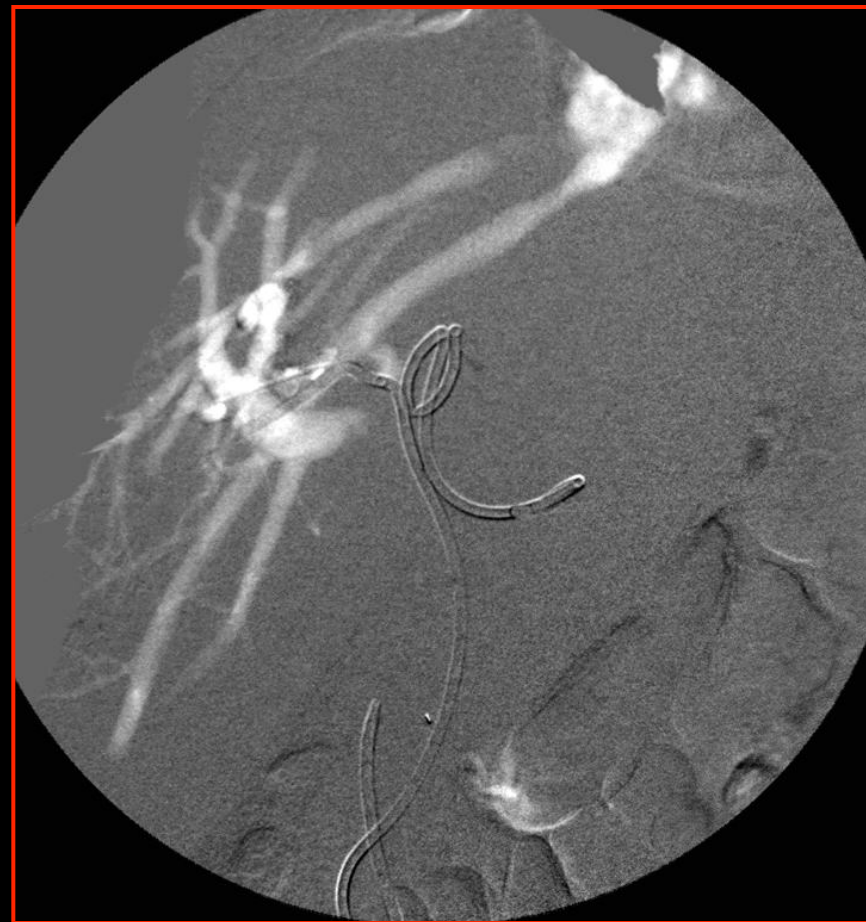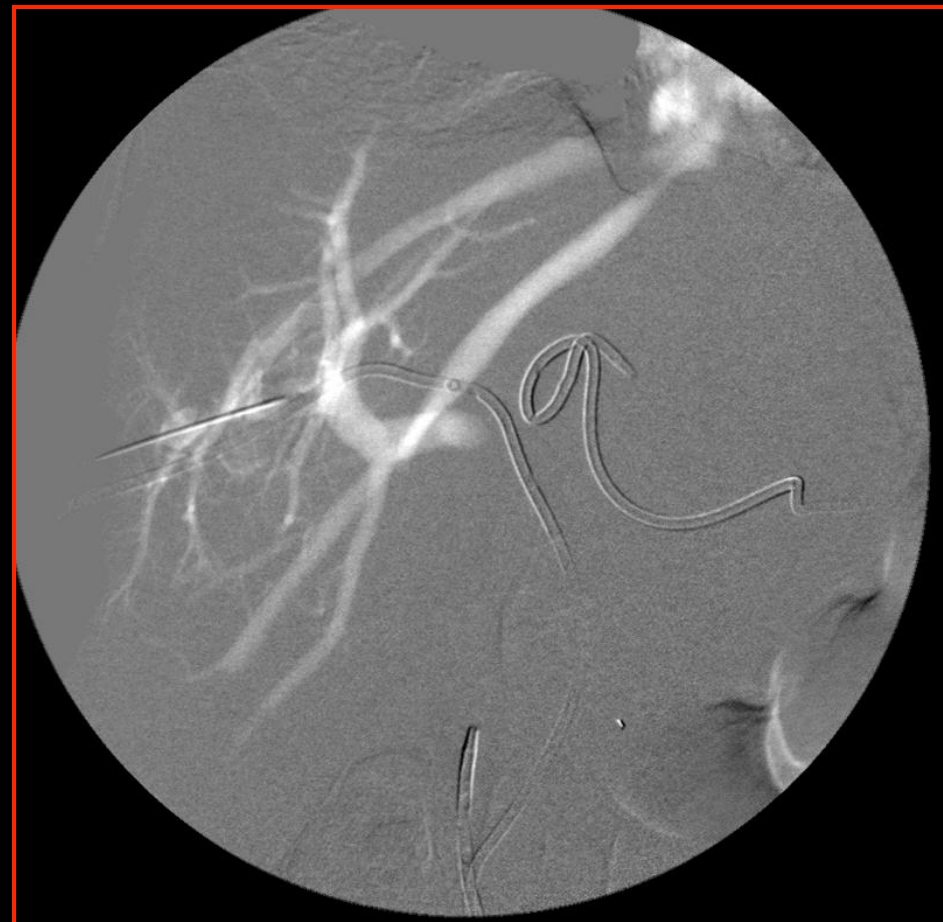- **Animal studies reveal no hepatic necrosis, infarction, congestion, laceration or extravasation**
- **Almost 100% portal vein visualization (120 pt' s)**
- **No complications**
- **No parenchymal staining**
- **Eliminates extra step, time and cost**
- **Uses the needle which is part of the procedure**

Hawkins et al, AJR 173; 625-629

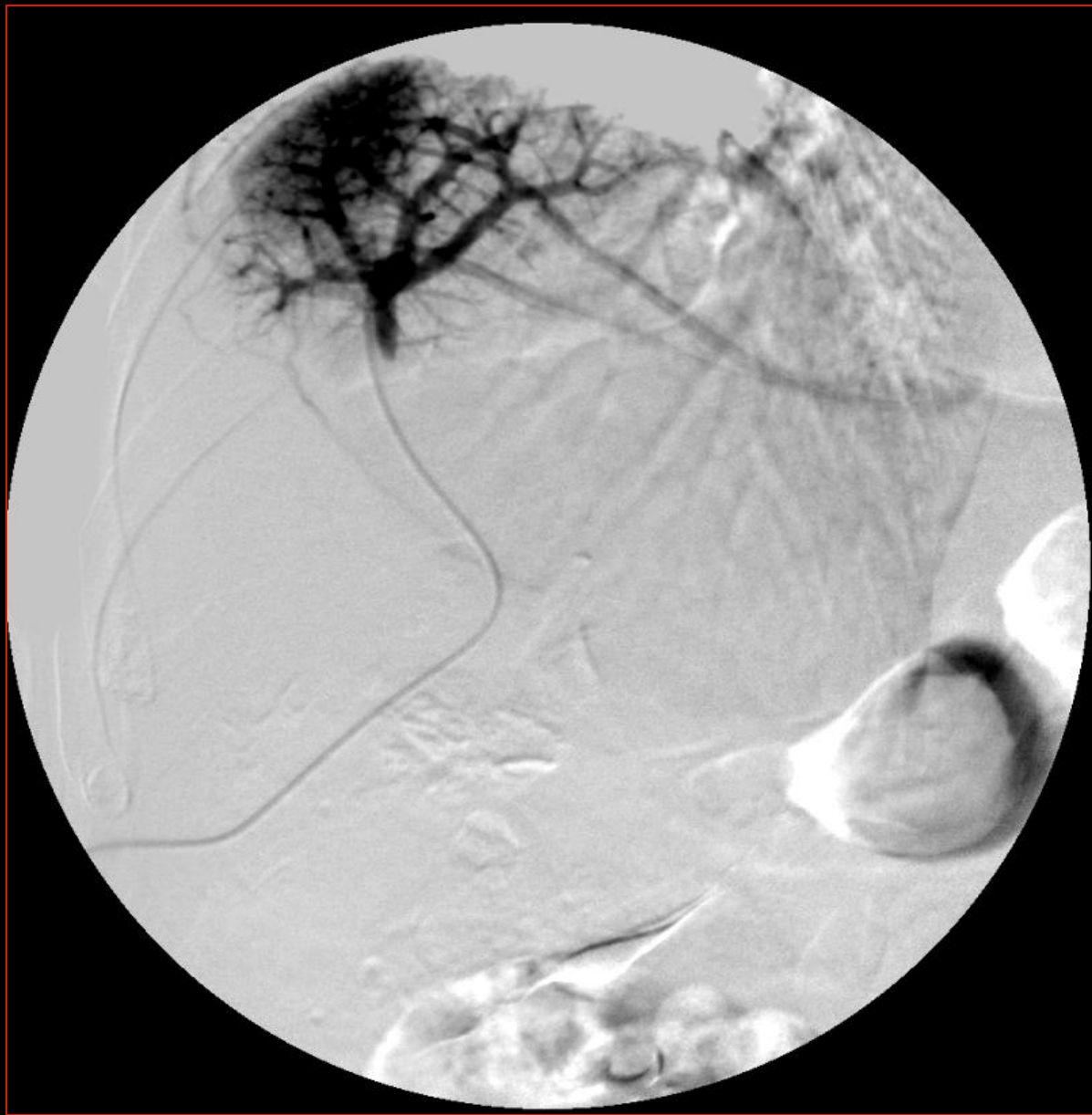Sun et al, Eur Radiol 2003; 13:244-250

Culp et al, JVIR 1999; 10:1265-1270

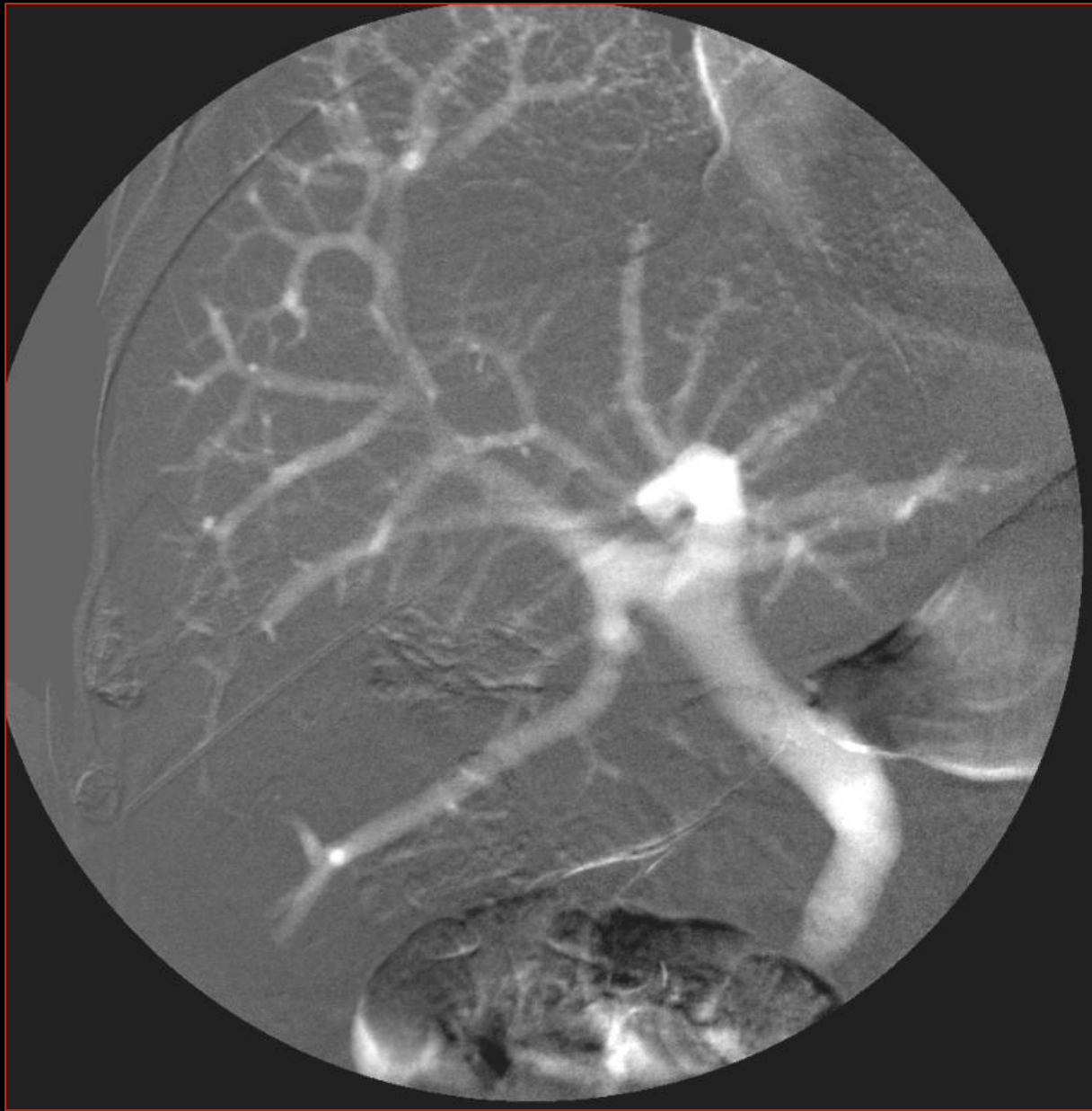



**Intrhepatic parenchymal injection of CO2 20 cc**

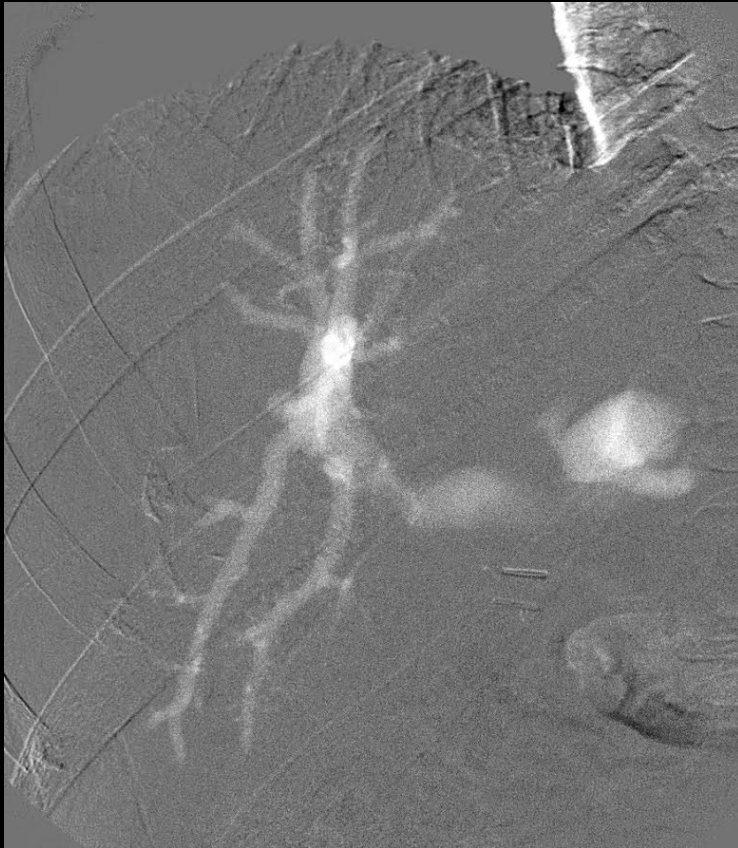

**Liquid contrast only shows peripheral**

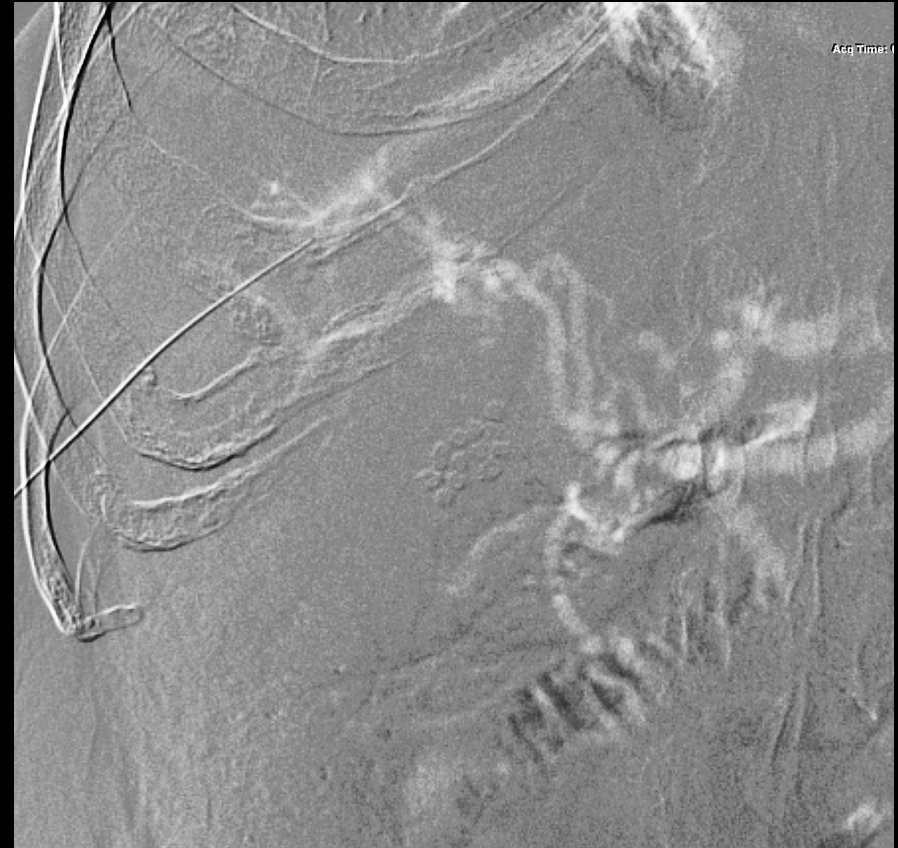

**CO2 demonstrates centrally with reflux**

**Patent**



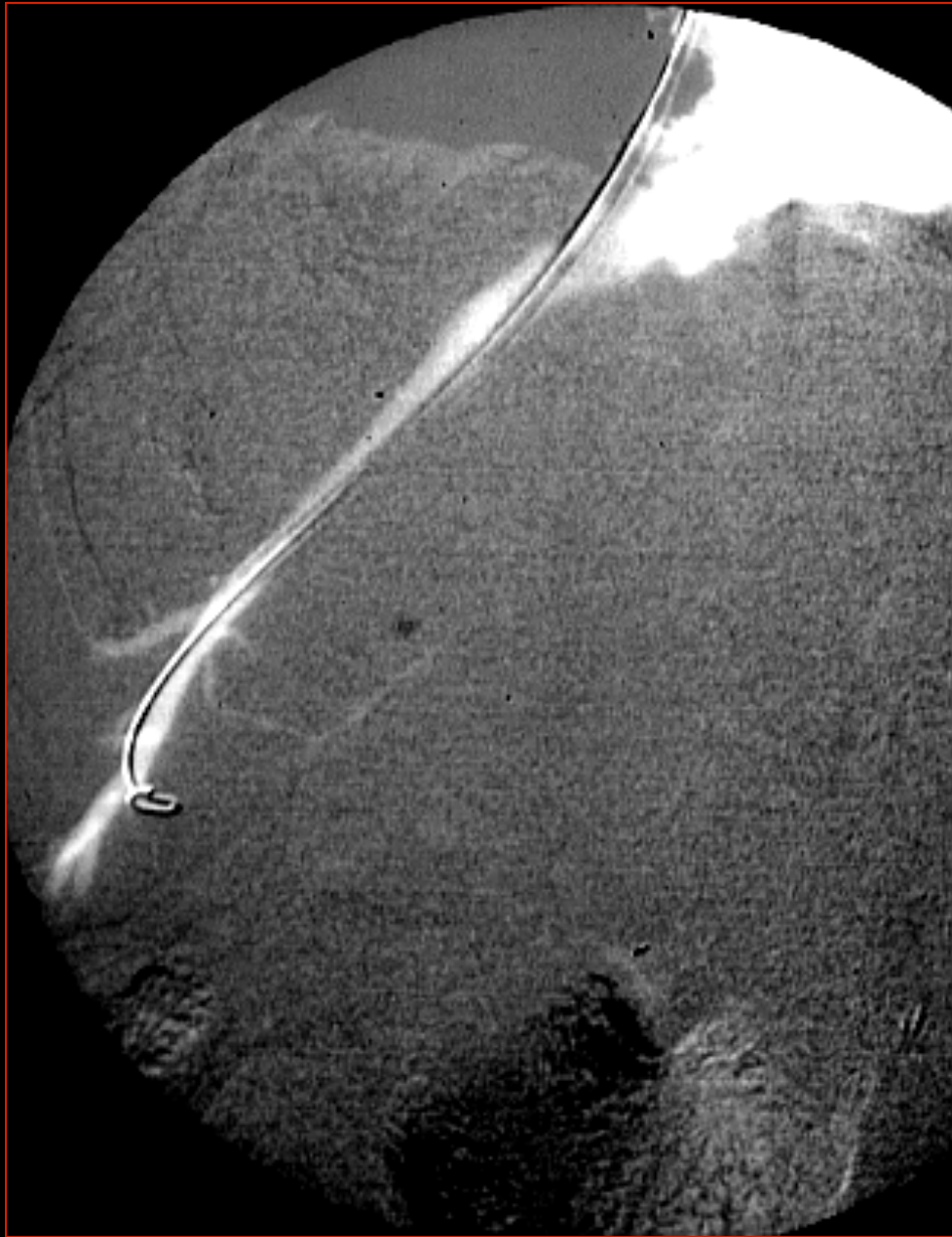**Occluded**



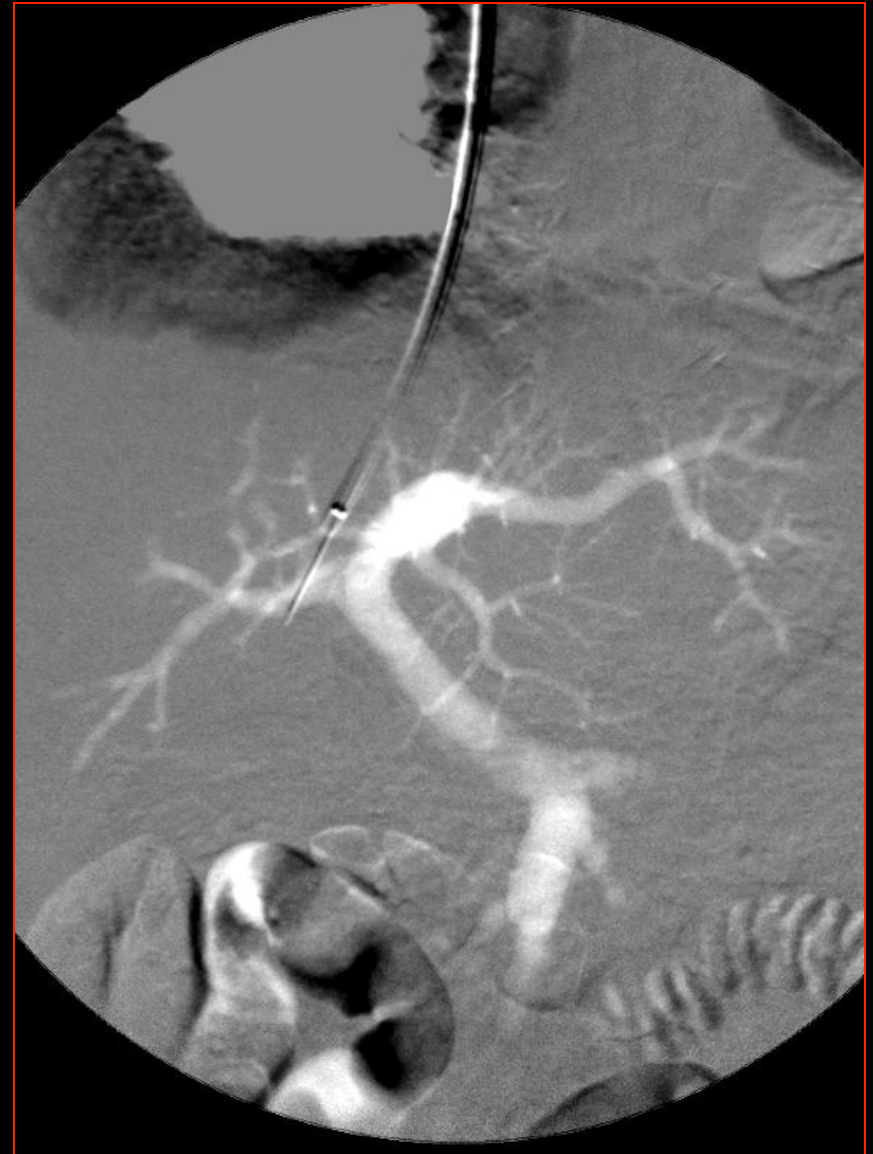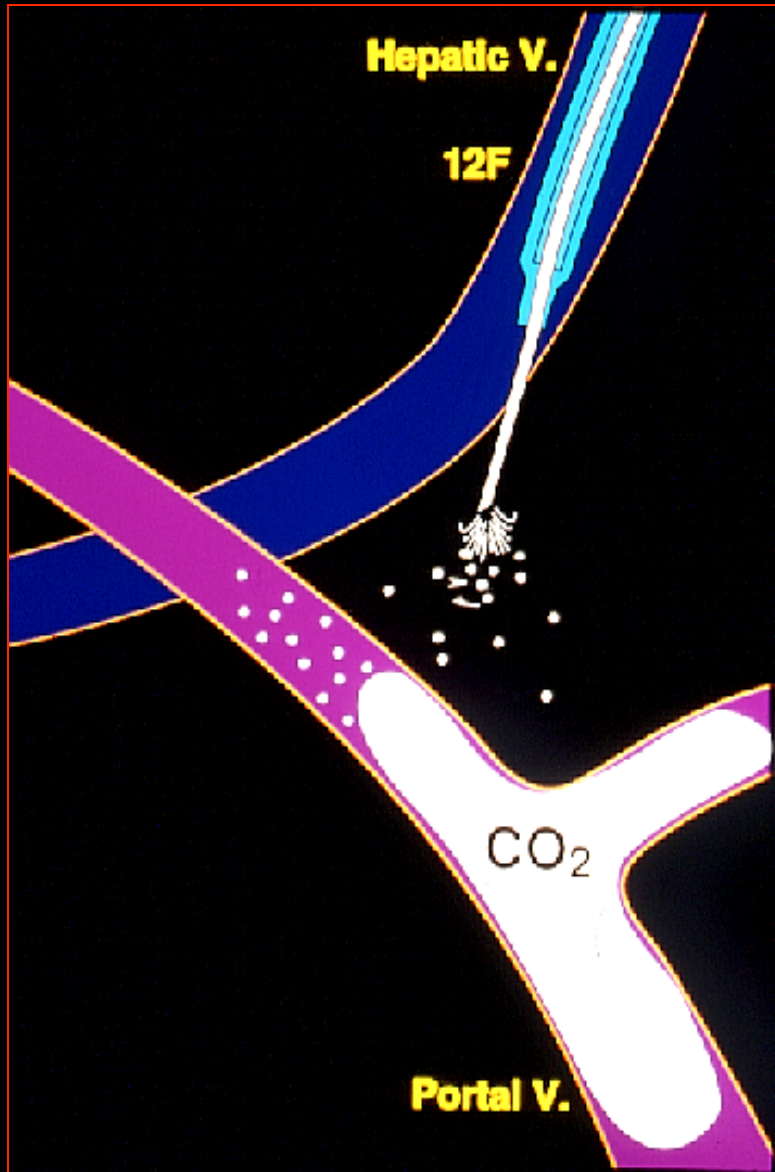
**CO2 10-20 cc through 25 ga spinal needle to determine patency of portal vein pre transplant**

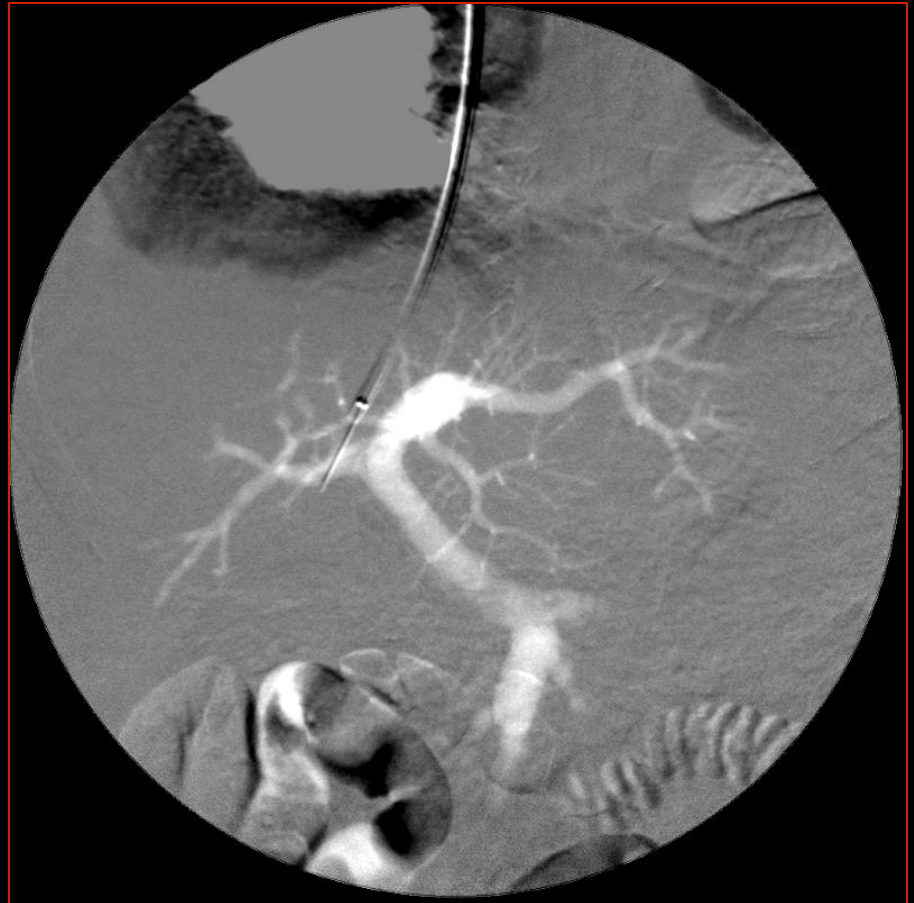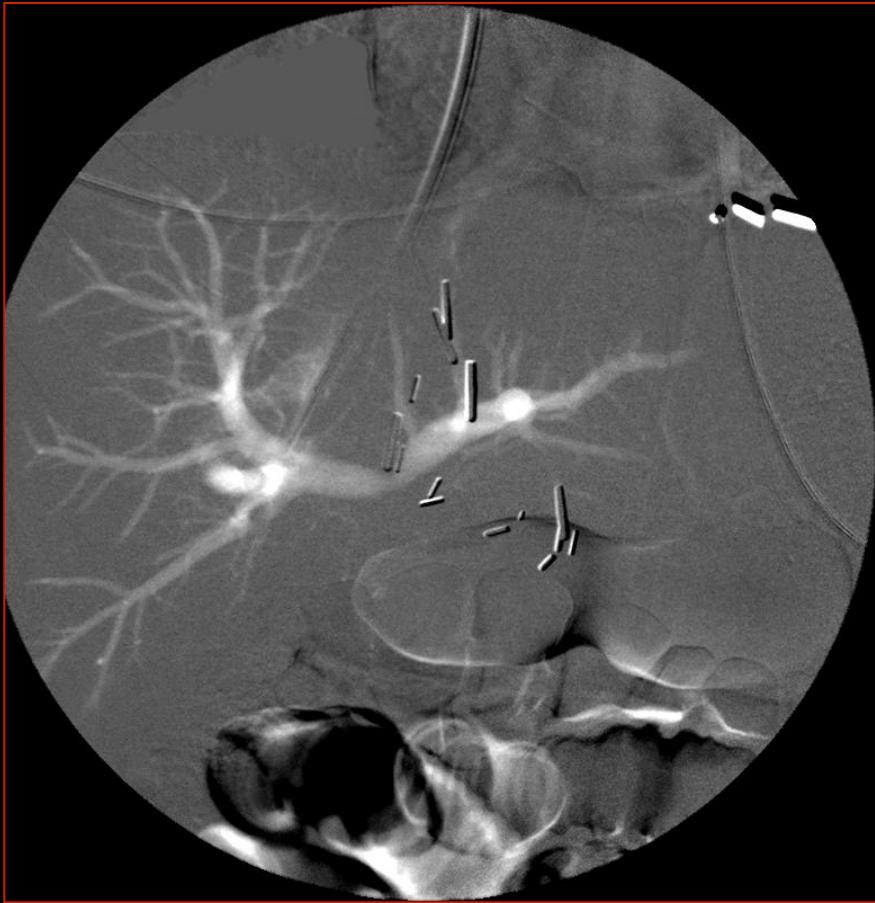# CO<sub>2</sub> GUIDED TIPS

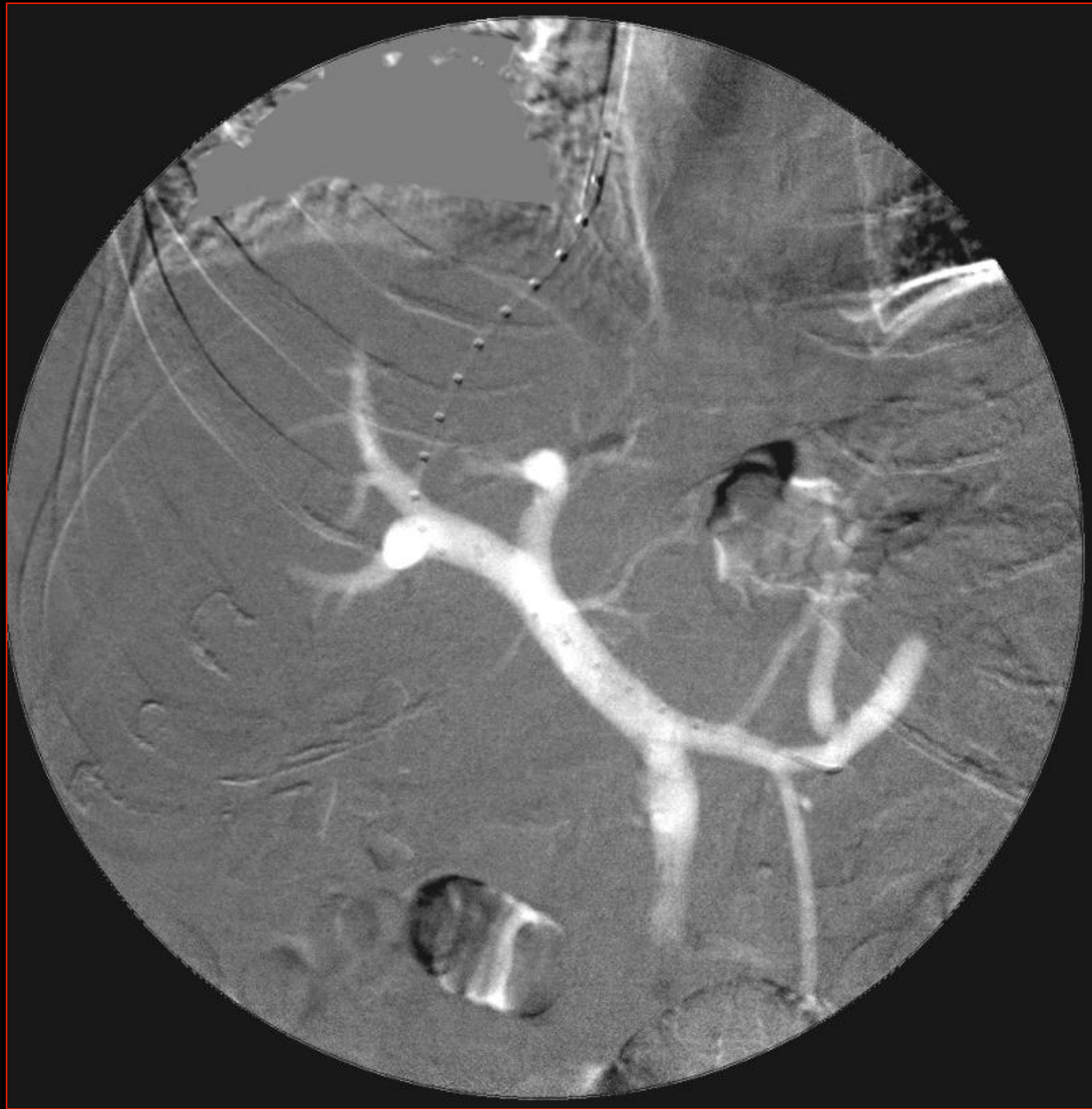- **Hepatic vein evaluation**
- **Intraparenchymal portal venogram**
- **Entry site verification**
- **Portal venogram**
- **Post procedure portogram**



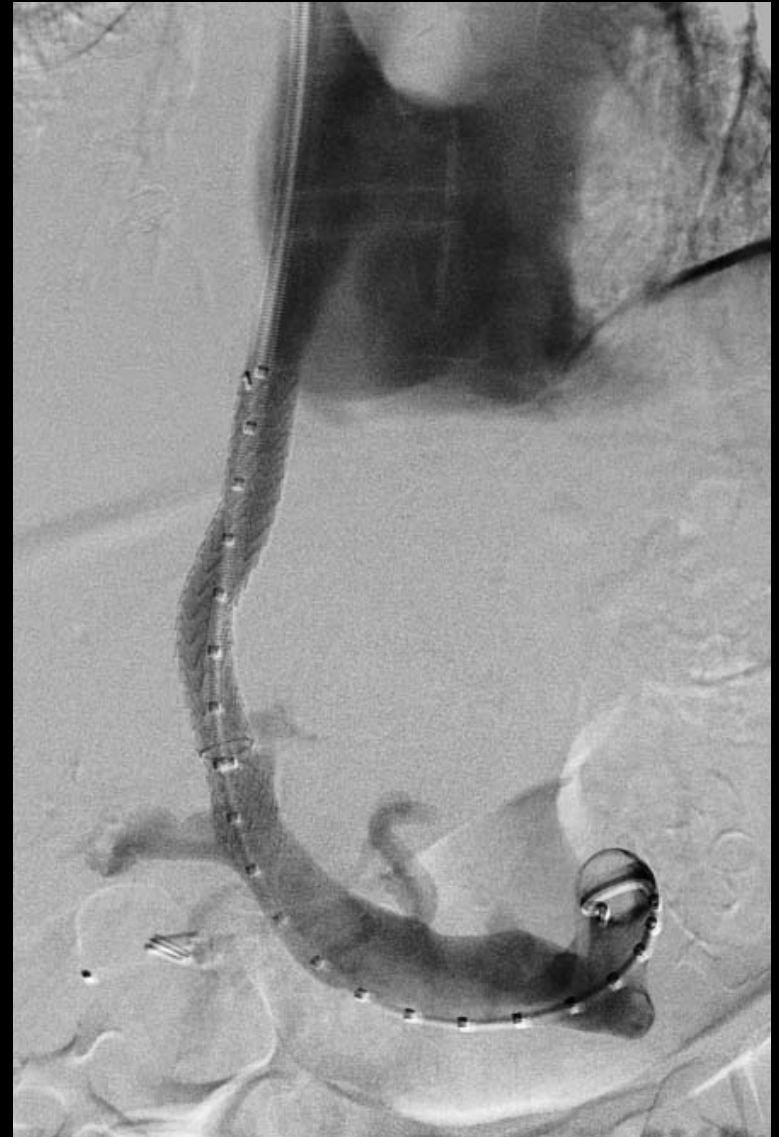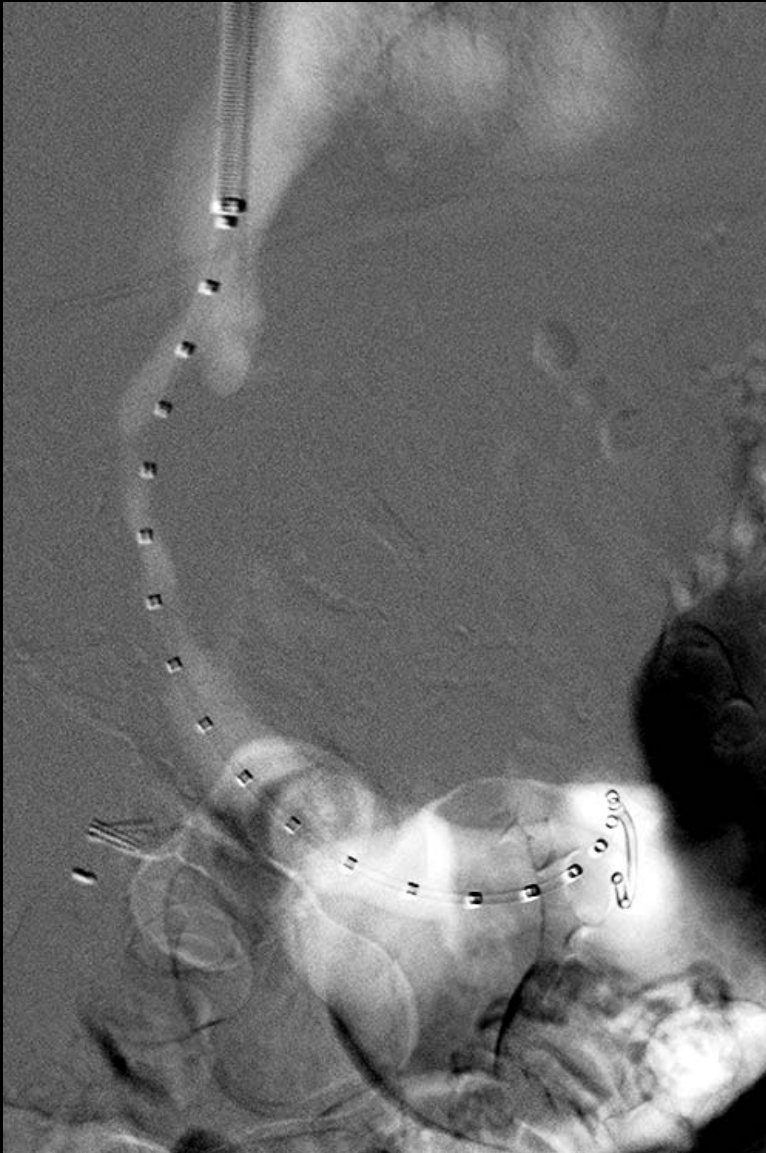
# DIRECT INTRAPARENCHYMAL CO<sub>2</sub>

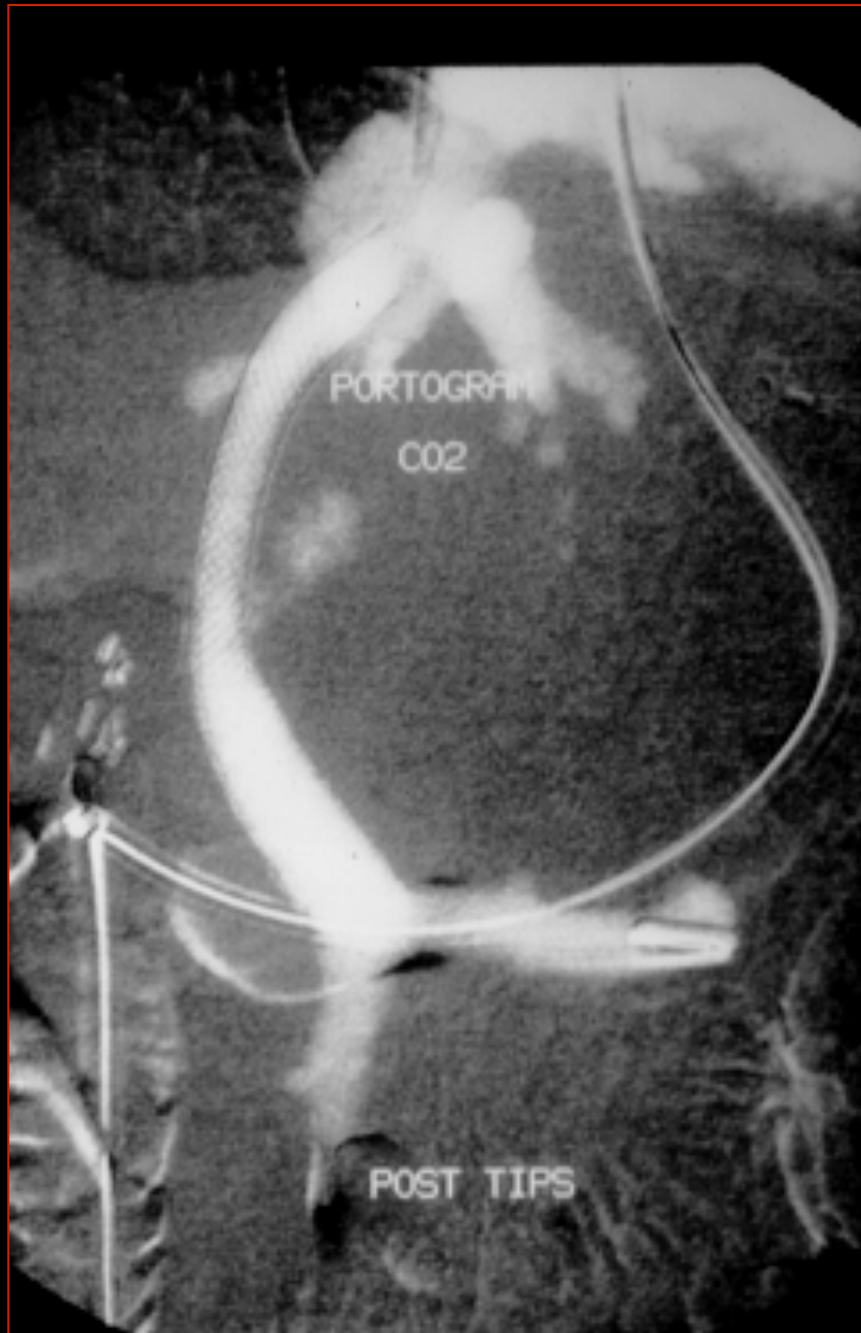






# MEASURING THE TRACT





# **CARBON DIOXIDE DIGITAL SUBTRACTION ANGIOGRAPHY**

- **CO<sub>2</sub> angiography is safe when used appropriately**
- **The delivery system is simple**
- **CO<sub>2</sub> has unique properties as a contrast agent**
- **These properties make it a useful tool in both diagnosis and intervention**