

See discussions, stats, and author profiles for this publication at: <https://www.researchgate.net/publication/13591704>

Lower limb angiography: A prospective study comparing carbon dioxide with iodinated contrast material in 30 patients

ARTICLE *in* AMERICAN JOURNAL OF ROENTGENOLOGY · SEPTEMBER 1998

Impact Factor: 2.73 · DOI: 10.2214/ajr.171.2.9694446 · Source: PubMed

CITATIONS

30

READS

18

7 AUTHORS, INCLUDING:



[Régis Duvauferrier](#)

Université de Rennes 1

159 PUBLICATIONS 1,166 CITATIONS

SEE PROFILE

Lower Limb Angiography: A Prospective Study Comparing Carbon Dioxide with Iodinated Contrast Material in 30 Patients

Yan Rolland¹
Regis Duvaferrier¹
Antoine Lucas²
Christine Gourlay¹
Nicolas Morcet¹
Marc Rambeau¹
Jacques Chaperon³

OBJECTIVE. We prospectively compared patients' tolerance for and the usefulness of carbon dioxide (CO₂) with iodinated contrast material in the study of lower limb arteries in 30 patients.

SUBJECTS AND METHODS. We systematically performed digital subtraction angiography with electronic injection of CO₂ (injection average, 330 ml) and digital subtraction angiography with iodinated contrast material in 30 patients (20 men and 10 women; mean age, 67.5 years) suffering from lower limb ischemia. Patients were monitored for vital signs and comfort. Four reviewers subjectively evaluated vessel visibility at five levels (pelvis, thigh, knee, calf, and ankle). We used the Student's *t* test to evaluate the tolerance and the global examination quality. The chi-square test was used to evaluate the stratified analysis of the observers and scores of the image quality according to the anatomic level studied. Bartlett's test of equality of variances was used to compare the variances between the readers.

RESULTS. CO₂ was less well tolerated ($p < .01$) than iodine was. Fifty-three percent of patients reported CO₂ was equally well tolerated (53%), 40% reported more discomfort than with iodine, and 4% reported less discomfort than with iodine. Both techniques were equivalent for imaging of the iliac arteries, but CO₂ performed poorly in the arteries below the knee ($p < .001$).

CONCLUSION. CO₂ angiography with electronic injection proved to be less comfortable than iodinated angiography. CO₂ arteriography is equivalent to iodinated arteriography for imaging the iliac arteries but imaging performance progressively degrades in the more distal arteries of the legs.

Carbon dioxide (CO₂) is a highly soluble natural gas (20 times more soluble than oxygen [1]) that is rapidly eliminated in the lungs. It is effective as an intravascular contrast medium to provide images in digital subtraction angiography (DSA) [2]. It is nonallergenic and nonnephrotoxic [3, 4]. These qualities are important when we consider that the morbidity of contrast media is 5% and the mortality is 0.006% [5], with no significant difference between ionic and nonionic products [6]. In patients with renal impairment and diabetes mellitus, the nephrotoxicity of conventional contrast medium is increased [7], and the recommended maximum dose of iodine should not exceed 80 g [8].

In 1982, Hawkins [2] first used the technique for imaging the aorta and lower limb arteries. He used manual injections that are known to lead frequently to bubble fragmentation [9]. Since the advent of dedicated CO₂ injectors, Seeger et al. [10] published a retrospective study of 128 patients in which 91% of the CO₂

images were good and 95% were concordant with the iodinated images. As far as we know, no prospective study of the tolerance and value of CO₂ angiography has been done. The aim of this study was to perform such a prospective study for lower limb arteriography by performing DSA with electronic injection of CO₂ and DSA with iodinated contrast material.

Subjects and Methods

Patients

After ethics committee approval, in a 6-month period, 30 patients who were aware of the aim of the study, the risks, and the study procedure were examined after informed consent was obtained: 10 women and 20 men who were 30–90 years old (mean age, 67 years) underwent both CO₂ and iodinated DSA of the lower limbs. Sixteen patients suffered from claudication and nine suffered from pain at rest. One had a distal aortic thrombosis, and postoperative arterial graft control was necessary for four patients suffering from claudication. All the patients were required to meet all inclusion criteria

Received February 27, 1997; accepted after revision February 24, 1998.

¹Radiology Department, Hôpital Sud, 16 Blvd. de Bulgarie, 35000 Rennes, France. Address correspondence to Y. Rolland.

²Vascular Surgery Department, Hôpital Sud, 35000 Rennes, France.

³Statistical Department, Hôpital Pontchaillou, Rue H. LeGuillon, 35, Rennes, France.

AJR 1998;171:333–337

0361–803X/98/1712–333

© American Roentgen Ray Society

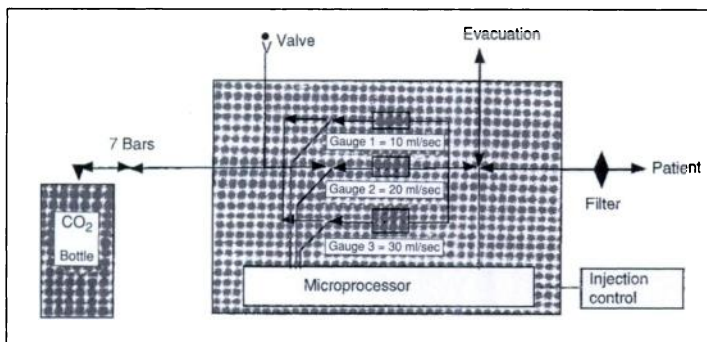


Fig. 1.—Drawing shows principle of carbon dioxide (CO₂) injector. Microprocessor controls opening of gauged valves to deliver exact amount of CO₂ for patient's blood pressure.

(general condition, need for lower limb angiography) and none of the exclusion criteria (having lung disorders, cardiac problems, or an aortic aneurysm).

Materials

All angiograms were obtained using an Integris C 2000 imaging system (Philips, Eindhoven, the Netherlands) and were printed with a laser imager (3M, Cergy Pontoise, France). An injector (Medrad, Pittsburgh, PA) was used for iodinated contrast material and a dedicated injector was used for CO₂. This dedicated CO₂ injector is a prototype made by Compagnie Française des Produits Oxygénés (CFPO, Paris, France) after a patented model [11]. This machine consists of two parts: a section with high pressure (101.5 psi) connected to a CO₂ bottle and one with low pressure connected to the catheter (Fig. 1). These two sections were connected by three gauged valves that allow the delivery of a given amount of CO₂ with each injection. The opening of these valves was controlled by a microprocessor. Available injection volumes and flow rates were 10, 50, 75, 100 ml, and 10, 20, 30, 40 ml/sec, respectively. The pressure of the injected gas was always matched

to the patient's blood pressure. A disposable cartridge of gas was set on the rear side of the injector.

Examination Technique

Injections were performed via a 4-French pigtail catheter in the distal aorta. The femoral approach was used in 23 of 30 patients and the humeral approach in the remaining seven patients. Iodine or CO₂ was injected randomly as the first contrast agent: 13 patients received the CO₂ first; 17, the iodine first.

Iodinated DSA

To evaluate lower limb arteries, we used a bolus-chasing method [12]. This digital technique allowed the viewing of the entire supply of the lower limbs with one injection. We used ioxaglate of sodium and meglumine (320 mg l/ml); 100 ml was injected at a flow rate of 8 ml/sec. Acquisitions were done during continuous movement of the patients under the imaging intensifier. Real-time images enabled manual control of the table speed to match the speed of the contrast material within the vessel. Subtracted images of the pelvis and the ankles were possible (early

and late masks) [13]. The feet were placed with the heels together and in external rotation.

CO₂ DSA

Precautionary measures were taken against neurologic side effects. The head was positioned low, and pneumatic pelvic compression was used. With the legs raised 20° to increase image quality, the C-arm of the imager was tilted to keep the vessels under exploration parallel to the image intensifier. The kilovoltage was set to approximately 60 kV, with an acquisition rate of three images per second. DSA images were displayed with an inverted gray scale. For each acquisition, 75 ml of CO₂ was injected at a flow rate of 20 ml/sec. The amount of CO₂ balanced image quality with comfort. Five DSA series were necessary to cover the lower limbs. We evaluated the amount of injected gas for each patient.

Clinical Evaluation and Image Analysis

One of two radiologists checked the clinical status of the patients with respect to their tolerance of the contrast media before and after both injections. This radiologist also reported the sensations of each patient for both contrast media using a scale of 0–4 as follows: no sensation, 0; sensation but no pain, 1; disagreeable sensation, 2; tolerable pain, 3; and intense pain, 4.

Four observers who were unaware of the patients' clinical status independently evaluated the images obtained with the two contrast media injections for image quality. Evaluations were done at five levels (pelvis, thigh, knee, leg, ankle). The result was 1 when the vessel was seen and the wall and collateral vessels were nicely delineated; if those conditions were not met, the result was 0.

Statistical Tests

We evaluated the difference in comfort between iodinated contrast media (considered to be the reference) and the CO₂. We calculated in all 30 patients the differences in tolerance scores, the mean, and the SD. We used the Student's *t* test to compare means.

We also evaluated the differences in image quality using iodine as the standard. One frame was printed for iodine and one for CO₂ for each anatomic level. For each patient, five levels were studied with two contrast media (iodine and CO₂), giving 10 ratings or scores per examination and 40 for four readers. The total data set of scores consisted of five anatomic levels, two types of contrast media, 30 patients, and four readers (five levels × two contrast media × 30 patients × four readers = 1200 observations or scores).

To evaluate the coherence of the results among the four readers, calculations of mean, variance, and SD were done. Bartlett's test of equality of variances was used to compare the variances between readers.

For a global analysis, we used the Student's *t* test. We tested the average score differences against the null hypothesis of zero (no difference between scores) to discover a significant difference between the iodine and the CO₂. We performed a stratified analysis to discover if the difference was homogeneous using Bartlett's test.

| TABLE 1 Level of Tolerance and Comfort in 30 Patients Imaged Using Iodine and Carbon Dioxide (CO ₂) | |
|--|---------------------|
| Score Difference Between Iodine and CO ₂ | No. of Patients (%) |
| -1 | 2 (6.7) |
| 0 | 16 (53.3) |
| 1 | 6 (20.0) |
| 2 | 4 (13.3) |
| 3 | 2 (6.7) |

Note.—Patients were evaluated using Student's *t* test (mean, -0.6; SD, 1.04). Negative values mean greater tolerance and less pain with CO₂, positive values mean the studies using iodine had improved tolerance and less pain, and a null difference means the tolerance and comfort with the two contrast agents were equal. CO₂ injection was scored as less comfortable than iodine for 12 of 30 patients. This difference was statistically significant (*p* < .01).

| TABLE 2 Global Analysis of Image Quality of 600 Images Using Iodine and Carbon Dioxide (CO ₂) as Contrast Media | |
|--|-------------------|
| Score Difference Between Iodine and CO ₂ | No. of Images (%) |
| -2 | 7 (1.2) |
| -1 | 15 (2.5) |
| 0 | 366 (61.0) |
| 1 | 112 (18.7) |
| 2 | 100 (16.7) |

Note.—Image quality was evaluated using Student's *t* test (mean, 0.47; SD, 0.84). Negative values mean CO₂ was rated as giving higher image quality, positive values mean the images from iodine were rated as higher image quality, and a null difference means the image quality of the two contrast agents was equal. Equal image quality was obtained in 61% of images.

Lower Limb Angiography

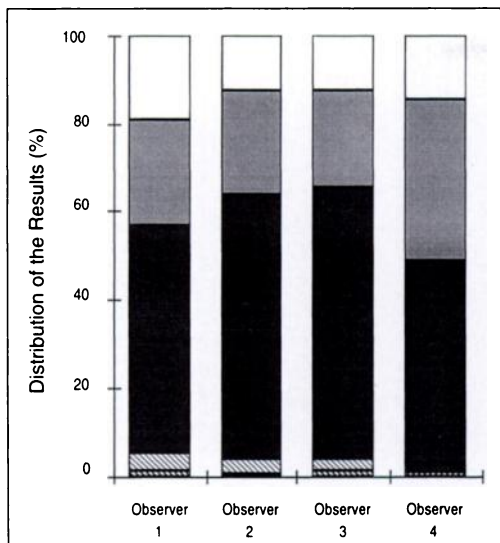


Fig. 2.—Bar graph shows image quality scores of four observers. Observers 2 and 3 were close in their comparisons of the two contrast media. Tall dark areas indicate equal image quality for iodine and carbon dioxide (CO₂), areas above dark area indicate decreasing performance of CO₂, and areas beneath dark area indicate increasing performance of CO₂.

In Tables 1 and 2, negative differences (–2, –1) mean a superiority of CO₂, whereas positive values (1, 2, 3) mean the images obtained using iodine were superior; a null difference means the performances of the two contrast agents were equal.

Results

Tolerance and Comfort

After an injection of an average of 330 ml (maximum, 550 ml), no dyspnea or general reaction was noted with CO₂. Four cases of urticaria were noted with iodine. Concerning comfort during the examination, gaseous injections were more uncomfortable than were iodine injections ($p < .01$). CO₂ was more disagreeable in 12 (40%) of 30 patients, similar sensations were described in 16 (53%) of 30 patients, and iodinated contrast material was more disagreeable in two (7%) of 30 patients (Table 1). Smarting sensations were felt after CO₂ injection by nine of 30 patients, and we had to interrupt one examination because of intense pain in the patient's toes.

Image Quality

Results of the four observers were analyzed globally because no significant difference existed between the average score of the four observers calculated with Bartlett's test (Fig. 2). In 49% of studied anatomic levels, good concordance existed among the four observers. For the remaining 51%, good concordance existed between three observers in most cases (78%).

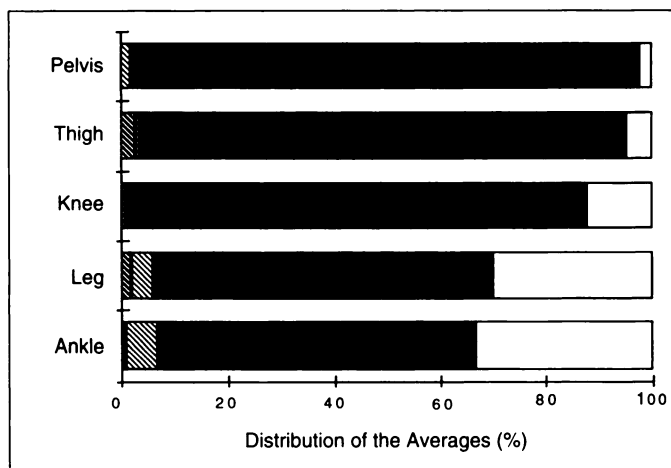


Fig. 3.—Bar graph shows stratified analysis of examination quality according to anatomic level. For pelvis, image quality is same (*long dark areas*) for iodine and carbon dioxide (CO₂); for thigh and knee, performance of CO₂ is decreasing (*areas to right of dark area*). Distally, good image quality is obtained using CO₂ in only one half of cases. Areas to left of dark area indicate performance of CO₂ is improving.

With the global analysis, using the Student's *t* test, CO₂ was less informative than iodine ($p < .01$). The performance of iodine was judged to be superior in 212 (35%) of 600 scored differences, the imaging quality was identical in 366 (61%) of 600 scored differences, and CO₂ angiography was superior in 22 (4%) of 600 scored differences (Table 2).

The relative image quality between the two methods varied significantly by anatomic level. Comparing variances in image quality by anatomic level with Bartlett's test resulted in a high significant difference ($p < .001$) (Fig. 3). Imaging quality was comparable for the pelvis in 112 arteries (93%) of 120 and for the thigh in 89 arteries (74%) of 120. Distally, the same quality was achieved in only one half of cases. Iodinated DSA was superior in 52 arteries (43%) of 120 at the level of the knees, 64 arteries (53%) of 120 at the level of the legs, and 63 arteries (53%) of 120 at the level of the ankles.

Discussion

CO₂ Tolerance

In this series of 30 examinations, we did not see any general reactions with CO₂, whereas four cutaneous reactions occurred with iodine. After an injection of an average of 330 ml, we did not record any ventilation abnormality. We did not note any neurologic anomaly, but precautions were taken in the absence of consensus on side effects of the injection in the supraaortic trunk [14, 15].

Concerning patient tolerance, CO₂ DSA is less comfortable than is iodinated DSA. These observations may be affected by the negative psychologic effect of the injection of gas in vessels, especially for patients (eight of 30) who had already had conventional angiography performed with iodine. The surprise, and the comparison with the known sensations of the iodine, could lead to the tingling sensations' being described as "disagreeable" during the first injection. Patients' sensations improved during later injections. The disagreeable sensations were linked to the quantity injected: In three patients, the diminution of quantities from 75 to 50 ml reduced patient discomfort without altering the quality of images. As described by Fermand et al. [13], small quantities of CO₂ (15–60 ml at a flow rate of 10–15 ml/sec) can even be better tolerated than the iodine.

Bendib et al. [16] demonstrated this excellent tolerance in 1600 CO₂ investigations. Those investigators injected 200 ml of CO₂ eight times in a peripheral vein with a 5-min period between the injections without any problem. Murray and Hawkins [17] studied more than 800 cases and reported a single case of severe diarrhea in a patient with an aortic aneurysm from which the inferior mesenteric artery emerged. Weaver et al. [9] observed a single case of dyspnea associated with tachycardia but the patient was known to suffer from chronic respiratory insufficiency. Miller et al. [18] remains the only study that describes patient nausea, lumbar pains, and sensations of heat.

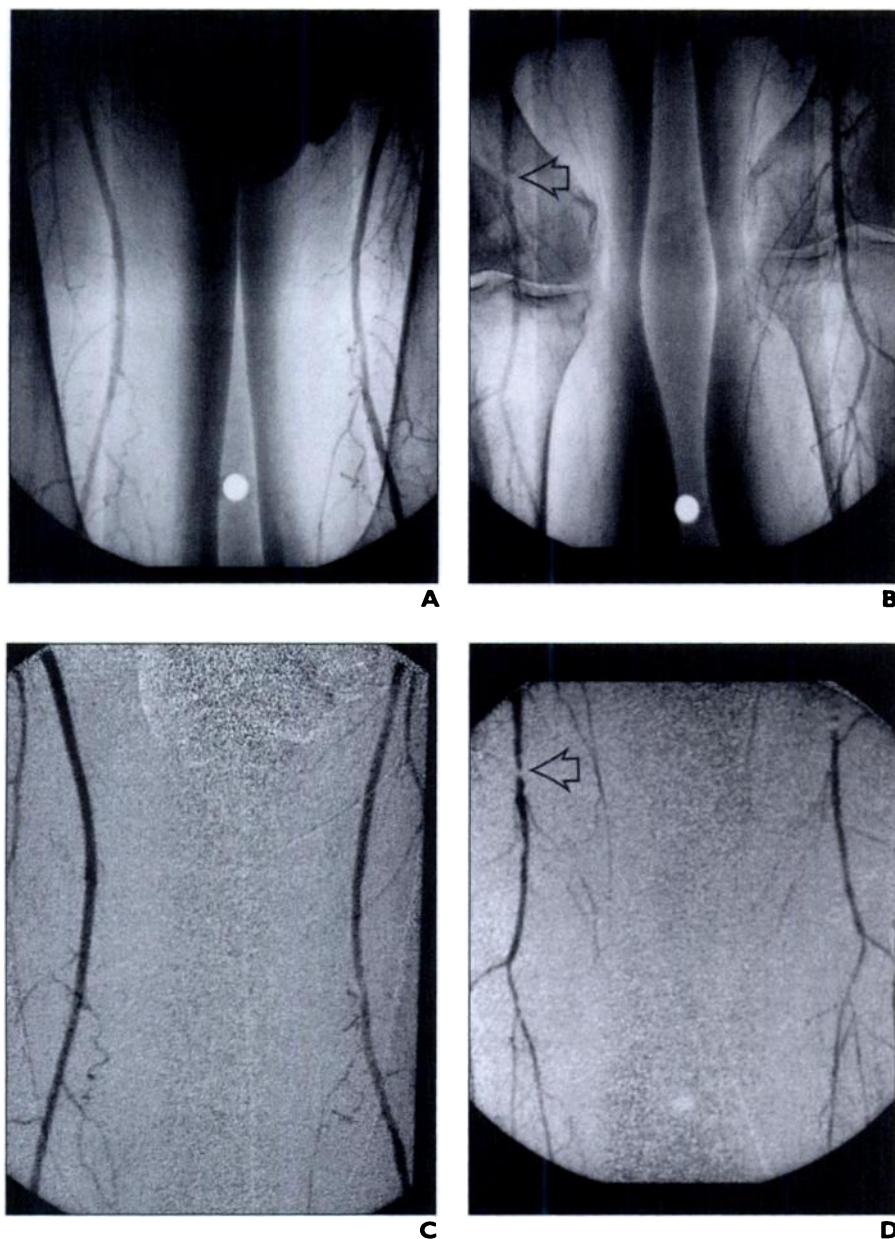


Fig. 4.—67-year-old man with right leg claudication. **A–D**, Angiograms obtained with iodinated contrast agents (**A** and **B**) and with carbon dioxide (**C** and **D**) reveal superficial and popliteal arteries. Note that both contrast media clearly show right distal superficial artery stenosis (arrows, **B** and **D**).

Image Quality

In our series, a good image quality was achieved in most cases for iliofemoral arteries, and CO₂ injection was as informative as iodine was (Fig. 4). We had fragmentation in iliac arteries in two patients because of aneurysmal vessels. The fragmentation was due to a trapping phenomenon and incomplete filling of the vessel. König and Krasny [19] demonstrated that when the diameter of the artery exceeds 12 mm, the filling proportion decreases rap-

idly, leading to image quality deterioration. This fact led us to exclude the abdominal aorta from our study.

Concerning the popliteal artery and distal runoff, we had good image quality in one half of the images with excellent correlation among observers concerning the number of distal vessels depicted at the ankle level. For the remaining half, the results were not reliable; the vessel was poorly depicted or not seen at all. Kerns and Hawkins [20] described this side ef-

fect and explained it was due to gas dissolution and occurred especially with the slow flow of small vessels. In our series, poor vessel depiction was due to gas fragmentation that occurred in six patients inferior to a severe proximal stenosis (Fig. 5). We had a good view of the proximal contralateral vessels in three of six patients, probably because of preferential flow on the nondiseased side. To overcome this phenomenon, we recommend selective injection, which could be performed using gas buoyancy and elevating the diseased side or with direct iliac injection.

In our series, CO₂ used with DSA was as informative as iodine for depicting iliac and femoral arteries. Distally, the image quality could be improved using stacking software that was not routinely available in our angiographic suite.

CO₂ is a well-known contrast material, yet it is not widely used because of the difficulty in obtaining a large bubble of gas. To avoid a bubble fragmentation, a dedicated injector is necessary to inject the minimal flow rate injection (20 ml/sec) proposed by König and Krasny [19]. With 75 ml of gas, we could get large bubbles and a good image quality. Increasing the amount or the flow rate leads only to retrograde injection without added quality. Decreasing the parameters leads to bubble fragmentation. Because of gas buoyancy [20], CO₂ can be trapped in the iliac vessels, especially if they are tortuous. This trapping does not result in a poor clinical outcome but it does result in a decrease in image quality. The filling of the distal vessels is spontaneously suboptimal when the legs are horizontal. The legs must be raised to improve the image quality.

Study Limitations

We had a methodologic problem that was due to the bolus-chasing method we use routinely with iodine injection. We compared CO₂ DSA images with nonsubtracted images of the femoral, popliteal, and proximal parts of the leg arteries. We could obtain iodinated DSA images of the pelvis and ankles. Because of this difference in acquisition, readers could identify the type of contrast media used. To overcome this problem, our statistician instructed the four observers to report the two contrast media injections independently.

The lack of stacking software [21] in our angiography suite might be responsible for an underestimation of the CO₂ image quality for the distal runoff. We could stack the images of some patients on a workstation with improved image quality, but no hard copies could be ob-

Lower Limb Angiography

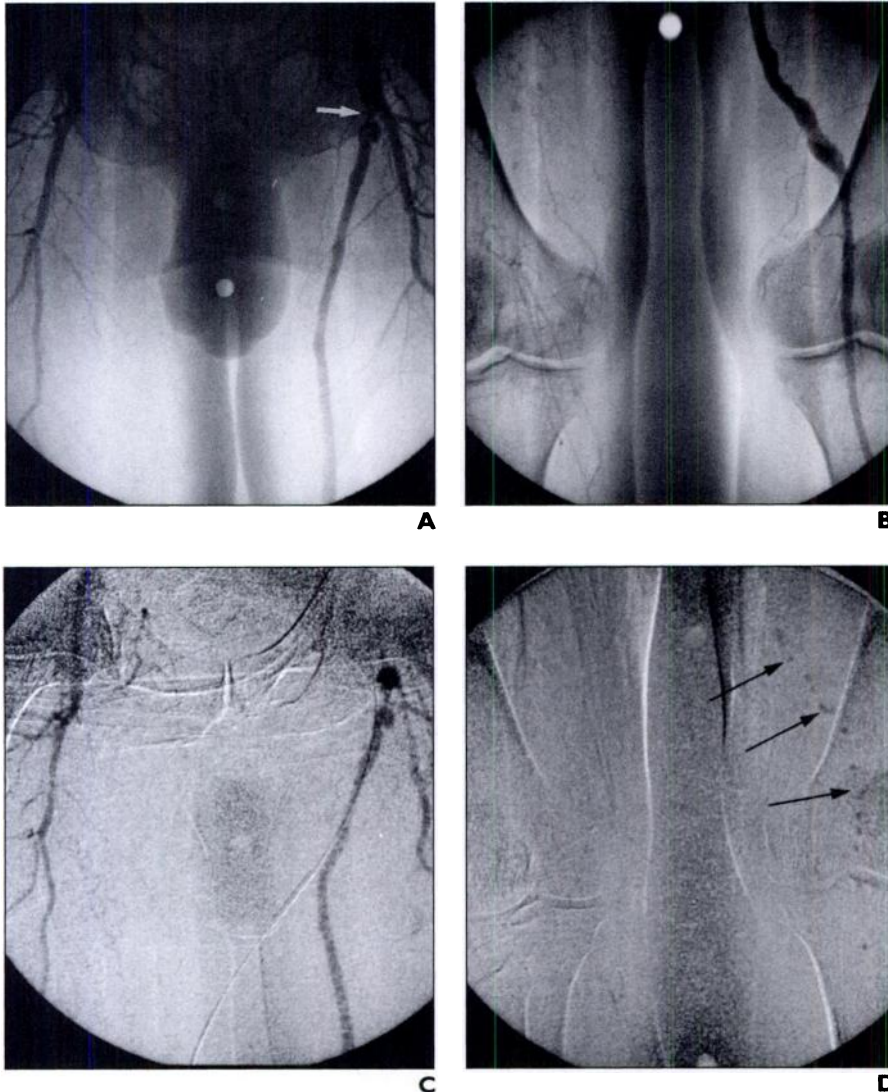


Fig. 5.—72-year-old man with recurrence of left lower limb ischemia. **A** and **B**, Angiograms obtained with iodinated contrast agent clearly show left proximal graft stenosis (arrow, **A**). **C** and **D**, Angiograms obtained with carbon dioxide. Angiogram (**C**) obtained 3 min after **B** also shows distal part of graft and popliteal artery. However, note bubble fragmentation (arrows, **D**).

tained. We decided not to use the stacked images to keep the results homogeneous.

Conclusion

In our series, CO₂ DSA with electronic injection was well tolerated with no related dyspnea or general reaction. With large volumes (75 ml), CO₂ was less comfortable than iodine was. We thus could achieve a good image quality when depicting proximal arteries. For infrapopliteal arteries, a good quality was available in 50% of cases. For patients with renal impairment, CO₂ could be used as a first choice to reduce the amount of iodine-based contrast medium. Fragmentation-related artifacts could be improved using stacking software.

tation-related artifacts could be improved using stacking software.

Acknowledgments

We are grateful for the support of A. Watkinson (Royal Free Hospital, London) in the preparation of this paper.

References

1. Oppenheimer MJ, Durant DM, Stauffer HM, Stewart GH, Lynch PR, Berrera F. In vivo visualization of intracardiac structure with gaseous carbon dioxide: cardiovascular respiratory effects and associated changes in blood chemistry. *Am J Physiol* **1956**;186:325–334
2. Hawkins IF Jr. Carbon dioxide digital subtraction

- arteriography. *AJR* **1982**;139:19–24
3. Bettmann MA, D'Agostino R, Juravsky LI, Jeffery RF, Tottle A, Goudey CP. Carbon dioxide as an angiographic contrast agent: a prospective randomized trial. *Invest Radiol* **1994**;29:S45–S46
4. Hawkins IF Jr, Mladinich CR, Storm B, et al. Short-term effects of selective renal arterial carbon dioxide administration on the dog kidney. *J Vasc Interv Radiol* **1994**;5:149–154
5. Shehadi WH, Toniolo G. Adverse reactions to contrast media. *Radiology* **1980**;137:299–302
6. Schwab SJ, Hlatky MA, Morris KG, et al. Contrast nephrotoxicity: a randomized controlled trial of a nonionic and an ionic radiographic contrast agent. *N Engl J Med* **1989**;320:149–153
7. Parfrey PS, Griffiths SM, Barnett BJ, et al. Contrast material induced renal failure in patients with diabetes mellitus, renal insufficiency or both. *N Engl J Med* **1989**;320:143–148
8. Lang EK, Foreman J, Schlegel JU, Leslie C, List A, McCormick P. The incidence of contrast medium induced acute tubular necrosis following arteriography. *Radiology* **1981**;138:203–206
9. Weaver FA, Pentecost MJ, Yellin AE, Davis S, Finck E, Teitelbaum G. Clinical applications of carbon dioxide/digital subtraction arteriography. *J Vasc Surg* **1991**;13:266–273
10. Seeger JM, Self S, Harward TRS, Flynn TC, Hawkins IF Jr. Carbon dioxide gas as an arterial contrast agent. *Ann Surg* **1993**;217:688–698
11. Briend R, Willemot JM, Muntlak H. Device and injection process of a gas. U. S. patent 5,427,104. Washington, DC: U. S. Patent Office, **1995**
12. Podeur L, Rolland Y, Lucas A, et al. Digital distal lower limb angiography: a comparison of selective iliac injection with vasodilators and bolus chasing technique. *Eur J Radiol* **1995**;5:140–144
13. Fermand M, Marzelle J, Cormier F, Cormier JM. Aorto-artériographie des membres inférieurs au gaz carbonique. *Presse Med* **1994**;23:19–22
14. Shifrin EG, Plich MB, Verstandig AG, Gomori M. Cerebral angiography with gaseous carbon dioxide (CO₂). *J Cardiovasc Surg* **1990**;31:603–606
15. Coffey R, Quisling RG, Mickle JP, Hawkins IF Jr, Ballinger WB. The cerebrovascular effects of intraarterial CO₂ in quantities required for diagnostic imaging. *Radiology* **1984**;151:405–410
16. Bendib M, Toumi M, Boudjellab A. Carbon dioxide angiography in cardiology. *Ann Radiol* **1977**;20:673–686
17. Murray KK, Hawkins IF Jr. Angiography of lower extremity in atherosclerotic vascular disease. *Surg Clin North Am* **1992**;4:767–789
18. Miller FJ, Mineau DE, Koeller PR, et al. Clinical intra-arterial digital subtraction imaging: use of small volumes of iodinated contrast material or carbon dioxide. *Radiology* **1983**;148:273–278
19. König T, Krasny T. Gas angiography: measurement of vascular gas filling and evaluation of parameters influencing gas injection using a circulatory system model. *Biomed Tech* **1991**;36:266–270
20. Kerns SR, Hawkins IF Jr. Carbon dioxide digital subtraction angiography: expanding applications and technical evolution. *AJR* **1995**;164:735–741
21. Kerns SR, Hawkins IF Jr, Sabatelli FW. Current status of carbon dioxide angiography. *Radiol Clin North Am* **1995**;33:15–29