

# *In Vivo* Visualization of Intracardiac Structures With Gaseous Carbon Dioxide

## Cardiovascular-Respiratory Effects and Associated Changes in Blood Chemistry<sup>1</sup>

M. J. OPPENHEIMER, T. M. DURANT, H. M. STAUFFER, G. H. STEWART III,  
P. R. LYNCH AND FRANK BARRERA<sup>2</sup>

WITH THE TECHNICAL ASSISTANCE OF Donna Donelan and Rosemary De Meo

*From the Departments of Physiology, Medicine, Radiology and Medical Physics, Temple University School of Medicine and Hospital, Philadelphia, Pennsylvania*

### ABSTRACT

Carbon dioxide gas was injected *a)* intravenously, *b)* into the left heart, *c)* into the peripheral end of the carotid artery. Resulting cardiovascular and respiratory changes were observed by cinefluorography and by measurements of pressure pulses in various locations. Blood and respiratory gas changes were also observed. All changes were minimal (seconds duration) when the gas was introduced on the right or left side of the circulation. Injection into the peripheral carotid produced no untoward effects. The gas gave good visualization of valves and great vessels. Body position was not an important factor in mortality and morbidity when carbon dioxide was the gas used for contrast visualization by a cinefluorography x-ray technique. Carbon dioxide is a safe contrast medium to use for *in vivo* study of intracardiac structures. The gas has been used successfully by intravenous injection in human cases.

WHEN AIR is introduced into the veins of dogs in doses of 7.5 ml/kg the position which the animals occupy relative to the horizon at the time of injection determines the number of survivals. In the supine position one out of three dogs will survive 7.5 ml of air/kg intravenously, in the left side down position two out of three survive, while in the right side down almost all die (1). During the course of these studies x-ray films were made at frequent intervals. Many of these plates revealed excellent details of valves, septa, other intracardiac structures and great vessels when air was present in the heart (2) and its adjacent tributaries.

The possibility of employing air as an intravenous contrast medium was considered. However, the alarming cardiovascular-re-

spiratory symptoms which result (1, 2) would preclude the use of such a material as air. It was suggested that carbon dioxide which is at least 20 times as soluble in serum at 38°C (3, 4) might persist as a gas long enough to permit visualization of intracardiac structures and vessels, yet would return to solution quickly enough to avoid most of the systemic hypotension, pulmonary hypertension, apparent bradycardia and alternating bouts of apnea and hyperpnea which resulted (1, 2) when air was the gas in question for use as an intravenous injection medium.

Therefore, it was considered important to determine whether carbon dioxide was safe as an intravenous contrast medium for the *in vivo* roentgenologic study of intracardiac structures. The dynamic changes in circulation and respiration and the chemical changes in blood as the result of intravenous gaseous carbon dioxide have not been previously studied. Studies of the effects of CO<sub>2</sub> gas when introduced into the left side are also

Received for publication January 12, 1956.

<sup>1</sup> Supported by Public Health Service Grant No. H-1883.

<sup>2</sup> Present address: Soledad 204, Havana, Cuba.

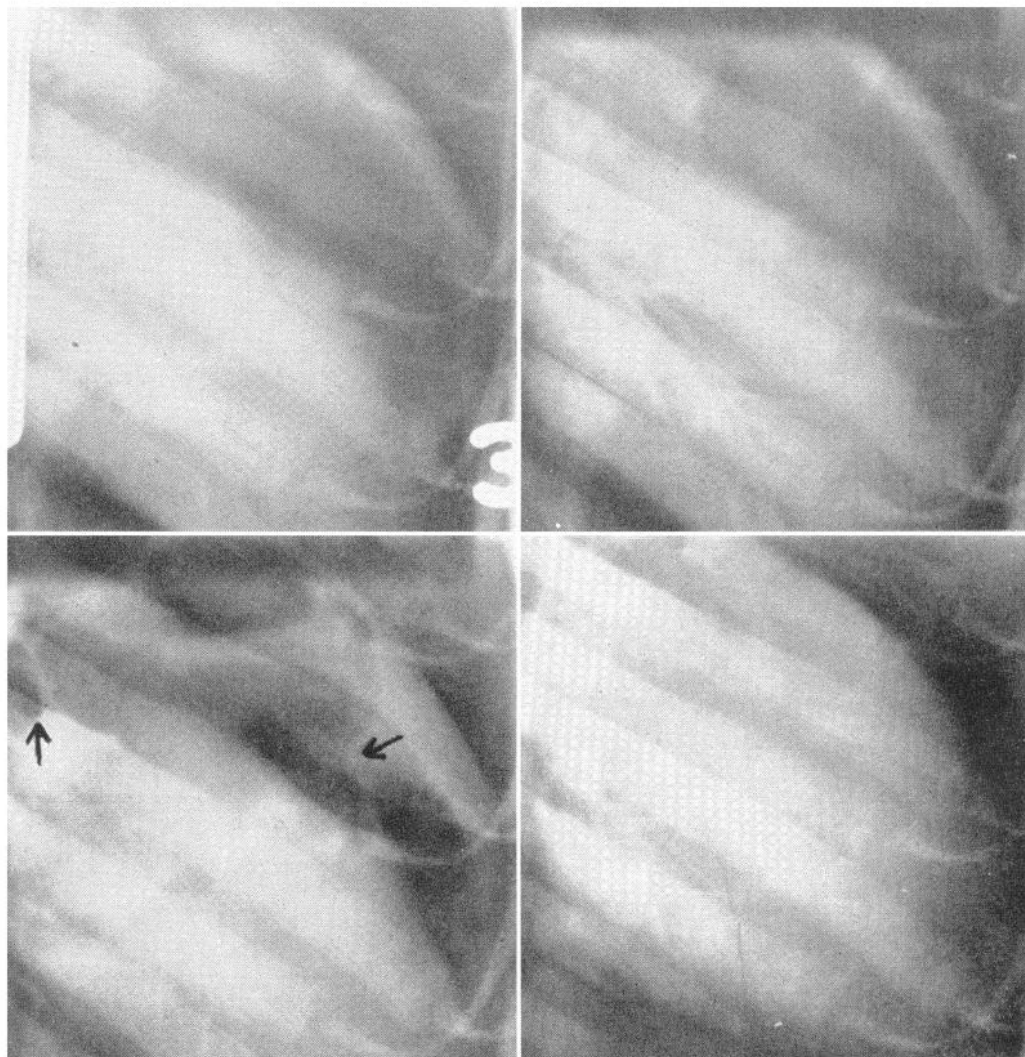


FIG. 1. Spot films taken during and after intravenous  $\text{CO}_2$  injection. *Upper left*: beginning of injection; *upper right*: end of injection; *lower left*: 5 sec. later; *lower right*: 5 sec. after lower left, all gas has disappeared. *Arrows* in lower left picture indicate (at *left*) bifurcation of main pulmonary artery filled with gas and (at *right*) the atrioventricular valve.

important because clinically one needs to know what would ensue if gas passed from right to left heart via a shunt. The present report presents data to elucidate these points.

#### METHODS

The test objects were mongrel dogs of 5–18 kg under Nembutal anesthesia (35 mg/kg). Injections of carbon dioxide and other gases in doses of 7.5 ml/kg were made within a period of 1–3 seconds into a femoral vein or via a catheter into the left ventricle. Animals were either supine or in the left or right side down position at the time of injection. The behavior of gases during their transit through the heart and great vessels was

observed and recorded by a cinefluorographic technique (5) which makes use of an image amplifier and a 16-mm motion picture camera. This method has been fully described elsewhere (6). In the fluorographic field of the image amplifier a mercury manometer recorded blood pressure, movements of the diaphragm and ribs indicated respiration, a synchronous motor timer gave one-fifth second intervals. All these parameters could be correlated with intracardiac events and those within the adjacent great vessels while gases were present. It was possible at a later time to study the film in slow motion since photography was carried out at 64 frames/sec. but the film was projected at 16 frames/sec. A dynamic concept was thus obtained. Conventional spot x-ray films were taken also.

During and after intravenous injection of carbon dioxide or other gases samples of pulmonary alveolar gas were obtained by means of a catheter placed in the trachea just above its bifurcation. Analysis of this gas for CO<sub>2</sub> was carried out either continuously by the Liston-Becker intra-red analyzer unit of an auto-anestheton<sup>3</sup> or by spot end-expiratory samples determined by micro-Scholander technique (7). The time of sampling was correlated with gas in heart and great vessels by reference to the timer in the movies checked against time in the protocols. Simultaneous arterial blood samples were analyzed for CO<sub>2</sub> and oxygen according to Van Slyke and Neill (8). The pH was also determined in a few selected cases. Where there was a residual gas bubble in the left heart samples of this were removed on several occasions via catheter and analyzed for CO<sub>2</sub> and O<sub>2</sub>. Conventional electrocardiograms were recorded.

Many experiments were carried out to study the cardiovascular-respiratory phenomena in more detail. During these tests recording was on a conventional kymograph or on a polybeam optical recording system. Records of pressure were made from various appropriate places in the cardiovascular and respiratory systems using techniques previously described (1, 2).

#### RESULTS

**Intravenous CO<sub>2</sub> Gas.** *Visualized by cine-fluorography.* In the supine position with a horizontal x-ray beam CO<sub>2</sub> (7.5 ml/kg) may be seen to enter the atrium and ventricle within the period of injection into a femoral vein. Both chambers are distended and gas is moved backward into and forward from the inferior vena cava during the cardiac cycle. The outline of the distended atrium is especially clear during ventricular systole. The descent of the atrioventricular groove illustrates the piston effect of the ventricle. The tricuspid valve can be clearly visualized when both chambers contain gas. Increments of gas are trapped on the pulmonary artery side of the pulmonary valve, serve to outline it and are delivered piece-meal into the pulmonary artery below. This vessel is briefly visualized during each right ventricular systole. Within 15-30 seconds the gas has largely become dissolved or been delivered during systole. During this process there is almost no formation of fluid levels. Considerable backward and forward movement of gas between atrium and ventricle helps with its mixing and solution. Systemic arterial blood pressure falls during the inflow of gas into the right heart and while it resides there. A period of hypotension while the gas volume is large is followed by an abrupt rise in pressure when the

TABLE I. COMPARISON OF EFFECTS OF GASEOUS CO<sub>2</sub> GIVEN AS INTRAVENOUS INJECTIONS WITH ANIMAL IN VARIOUS ANATOMIC POSITIONS

	Ab-normal EKG	Hyper-pnea	Sys-temic Hypo-tension*	Rt. Vt. Dias. P Elevation	Rt. Vt. Sys. P Elevation
Supine	> 15	> 15	> 15	15	> 15
Right	5	8	6	0	> 15
Left	15	> 15	15	0	—†
					> 15

Values are average duration, in seconds.

\* Return to a steady state within approximately 10% of control values considered as recovery.

† Lowered for 5 sec. then elevated.

right ventricle recovers from its initial distension and begins to forcibly deliver blood and gas into the pulmonary artery as the gas volume decreases when it begins to go into solution. The period of large initial gas volume which is synchronous with hypotension is also observed to be the period of hyperpnea followed occasionally by brief apnea. During this same period of large gas volume the electrocardiogram is briefly altered. The changes include a decrease in the size of QRS and a small deviation of the S-T segment.

Results are similar in the left and right side down position. However, in each case the duration of hypotension and hyperpnea is less than when the dogs are supine. These briefer disturbances in circulation were observed to coincide with a shorter transit time required for the gas to pass through the cardiac chambers. The average time required in the right side down position was only 5 seconds while about 15 were required in the left decubitus. In all, 82 tests with intravascular gaseous CO<sub>2</sub> were carried out in 43 dogs. Of all the animals tested only one dog was lost with CO<sub>2</sub> and this after the third injection. Position of the dog made no difference as to survival when CO<sub>2</sub> was the gas injected.

As has been pointed out (9) single frames of the movies do not make enlargements of as good quality as conventional x-ray films. Therefore, only the latter are shown here. Figure 1 shows four spot x-rays taken at a) the beginning and b) end of an intravenous injection of CO<sub>2</sub> gas, c) 5 and d) 10 seconds following the end of the intravenous injection of CO<sub>2</sub> gas. The animal was lying on its right

<sup>3</sup> Manufactured by Lee-Morris Co., Belmar, N. J.

TABLE 2. CHANGES IN ARTERIAL BLOOD AND ALVEOLAR GASES 30 SEC. AFTER INTRAVENOUS CO<sub>2</sub> GAS

Date 1955	Whole Blood O <sub>2</sub> Content, Vol. %	Whole Blood CO <sub>2</sub> Content, Vol. %	pH Units	Alveolar O <sub>2</sub> %	Alveolar CO <sub>2</sub> %
8/25	+0.4	+7.0			
8/23	-1.7	+5.0			
8/22	+2.8	+4.1			
8/19	-0.8	+5.2			
8/18	+2.0	+9.9			
8/16 (A.M.)	+1.1	+2.6			
8/16 (P.M.)	-1.4	+6.4			
8/15	-1.0	-1.3			
9/2	+0.9	+1.3	+0.07		
9/8	-3.4	+3.0			
9/9	+2.8	+3.1	0.00		
9/13	+0.6	+2.0	+0.01		
9/14	+2.5	+3.0			
9/16	-3.2	+3.7			
11/7	+0.4	+2.2			
11/16	+1.2	-1.7			
11/28	-1.3	+1.4			
11/23	+0.2	-2.4		-2.24(S)	+2.49(S)
12/5	-0.09	+2.7	-0.05	2.8(S)	-1.54(S), (LB) + 2.2,
12/6					-2.8
12/12					-2.01(S)
12/14	+1.8	+0.2		+2.8(S) +2.7(LB)	
Average	-0.3	+2.87	+0.008		

S = Scholander. LB = Liston-Becker.

side and a vertical x-ray beam was used. The gas has disappeared within 10 seconds

Animals survived as many as eight intravenous injections of carbon dioxide gas at 15-minute intervals. Such dogs were often killed by air in positions in which they had survived several injections of CO<sub>2</sub>. Effects on circulation and respiration and varying percentages of survival depending on anatomic position were the same as in a previous study when air was the gas which was used (1).

Minimal doses of 0.5 ml/kg CO<sub>2</sub> were sufficient to outline the pulmonary conus successfully. This could be repeated at will if the period of hyperpnea following a previous dose were avoided by waiting sufficient time.

*Cardiovascular-respiratory effects (table 1) and associated changes in blood chemistry (table 2).* Most of the changes observed had durations of the order of seconds (fig. 2). All dogs were compared during the first 15 seconds after gas injection since this is the period of significant changes. Systemic blood pressure returned most rapidly to within approximately 10% of control values in the right

lateral decubitus after intravenous CO<sub>2</sub> in which position it required 5 seconds to do so. In the left side down position the average time required to attain within 10% of control levels following the short bout of hypotension due to CO<sub>2</sub> injection was 15 seconds. When the animal was supine recovery of blood pressure to within 10% of control values required periods greater than 15 seconds but not longer than 1 minute.

Hyperpnea during and after injection of gaseous CO<sub>2</sub> was always shortest in the right side down position (fig. 2), although a polypnea might last 2 minutes. In these animals the increased depth of breathing usually lasted for only a few breaths. The duration of the polypnea often lasted for 1-2 minutes in the other positions but was not very marked in any event.

Simultaneously recorded electrocardiograms were abnormal for the length of time corresponding to the presence of gas in the cardiac chambers and the duration of systemic hypotension. The chief change was a reduction in height of QRS. However, a few extrasystoles occurred during the presence of gas in the heart. Sometimes there was a brief ST segment deviation with a change in the direction of T.

Right ventricular systolic pressure became elevated in all three positions studied. However, in the left lateral decubitus this parameter fell for a period of 5 seconds before it became elevated. Right ventricular diastolic pressures were significantly elevated only in the supine position. It should be noted that elevations in right ventricular systolic pressure persisted for periods up to 3-5 minutes in all positions.

Fifteen to thirty seconds after the termination of the CO<sub>2</sub> injection arterial samples were taken for CO<sub>2</sub> and oxygen analyses. They showed surprisingly little change (table 2). The average reduction in O<sub>2</sub> content was only 0.3 vol. % with extremes of +2.8 and -3.4 vol. %. Carbon dioxide whole blood content was observed to be increased an average of 2.9 vol. %. The extremes were somewhat wider, +7.0 to -2.4 vol. %. However, 15 of the 20 cases studied were between +4.1% and -2.4%. Within 2 minutes control values were always attained. The pH showed only an average increase of 0.008 u

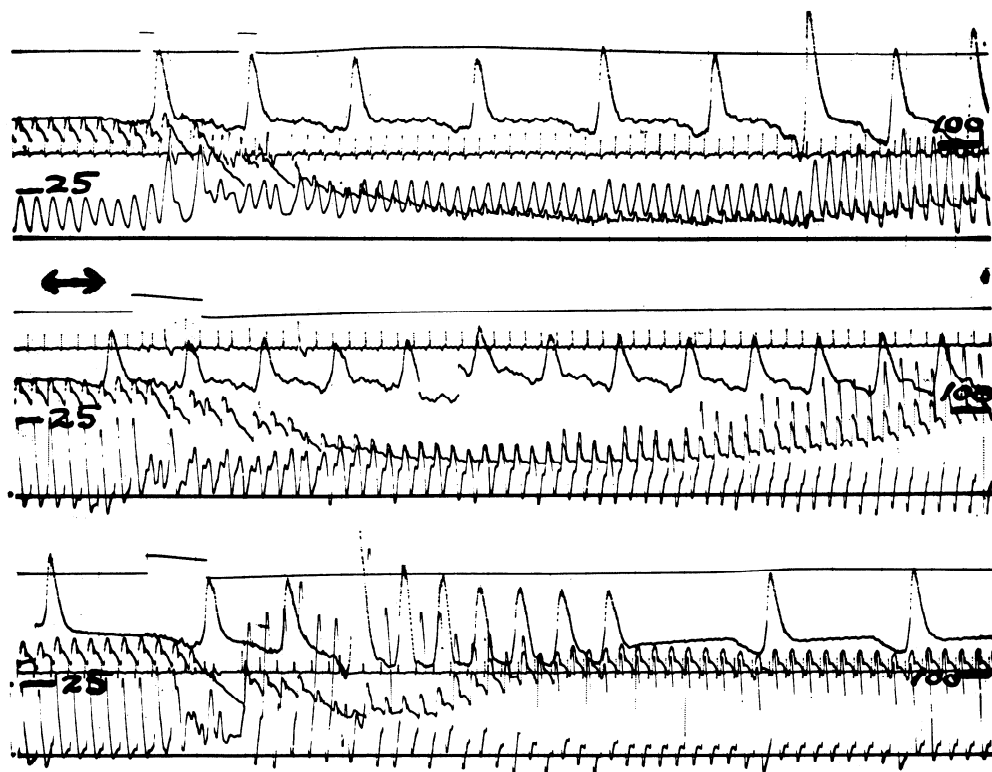


FIG. 2. Effects of intravenous carbon dioxide gas. *Upper*: from above downward: signal, two interruptions in signal line indicate beginning and end of injection; intratracheal pressures; carotid blood pressure; lead I of electrocardiogram; right ventricular pressures. Dog's position is supine. Calibration at left (mm Hg) for right ventricle; at right (mm Hg) for arterial blood pressure. Time as in *middle*. *Middle*: from above downward: signal, upward movement of line during period of injection; lead I of electrocardiogram; intratracheal pressures; carotid blood pressure; right ventricular pressures. Calibrations as in *upper record*. *Double ended arrow* = 1 sec. in all records. Dog on left side. *Lower*: from above downward: signal, upward movement of line during period of injection; intratracheal pressure carotid blood pressure; lead I of electrocardiogram; right ventricular pressures. Calibrations as in *upper record*. Time as in *middle*. Dog on right side.

in the four cases studied. End expiratory alveolar air samples were obtained by monitoring tracheal air pressures. Then 1-cc increments of gas were withdrawn via a catheter whose tip was just above the tracheal bifurcation (personal communication from Mr. A. Bechtel). This gave an average sample over 8-10 breaths to provide a large enough volume for the Scholander analysis. Sampling was difficult during the hyperpnea after CO<sub>2</sub>. Results by this technique gave changes in either direction (table 2). This difficulty was solved by use of a Liston-Becker infrared CO<sub>2</sub> meter contained in an auto-anestheton device. This gave a continuous breath to breath analysis (fig. 3) of CO<sub>2</sub> concentration and showed why average changes over several breaths might go in either direction. During

approximately the first 15 seconds after intravenous CO<sub>2</sub> the alveolar CO<sub>2</sub> is elevated (to 7.5% in the typical experiment shown in fig. 3) and after that it is lowered for a much longer period (to 3.5% in the same experiment). Despite this, apnea following hyperpnea was unusual. There was often an oscillation in alveolar CO<sub>2</sub> concentration which was periodic with the cardiac cycle, especially during expiration (first cycle of respiration, fig. 3).

**Carbon Dioxide Gas Placed in the Left Ventricle.** Control experiments (5) were carried out at the beginning of these tests and in the post-mortem state to localize catheter tips used to introduce the carbon dioxide gas into the left ventricle. Injections of 70% diodrast were used for this purpose and were




FIG. 3. Changes in alveolar  $\text{CO}_2$  due to injection of intravenous carbon dioxide gas. 3A and 3B are continuous. From above downward: Liston-Becker infrared analyzer record of alveolar carbon dioxide concentration, straight line indicates 5.3%  $\text{CO}_2$ ; aVr of electrocardiogram; femoral blood pressure; right ventricular pressure with zero base line. Carbon dioxide gas injected intravenously during break in base line for ventricular pressure (indicated by arrow). Time as in fig. 2. Calibration for arterial pressure at left for A and for right ventricle at left on B. Calibration at right on both A and B for alveolar carbon dioxide.

observed or photographed by the image-amplifier technique. This made it possible to determine that catheters were properly placed and had not moved during the experiment. Flow into the aorta under these circumstances was observed to be distinctly turbulent.

*Visualized by cinefluorography.* In all three anatomic positions gas entered the left ventricle and clearly visualized the aortic valves. The leaflets could be seen opening and closing as gas and blood entered the aorta during each heart cycle. As the ventricle became distended with gas the valves remained open. Gas also entered the atrium when ventricular distension became maximum and the atrio-ventricular valve dilated and permitted carbon dioxide to enter that chamber. At this time when gas existed on both sides of the mitral valve the actions of this structure were clearly visible. Gas could now be seen moving backward and forward in pulmonary veins during the cardiac cycle.

In one supine animal with a probe patent foramen ovale (confirmed at autopsy) gas was seen to enter the right side of the heart and collect in the right ventricle (5). This occurred only when carbon dioxide gas introduced into the left ventricle had been able to enter the left atrium via the dilated mitral valve. If only enough gas was introduced to fill the left ventricle without entering the left atrium no gas collected in the right heart.

Good mixing and a rapid reduction in the volume of the gas introduced into the ventricle was observed. As the gas volume be-

came less, the aortic valves again began to open and close with each cardiac cycle. There was however, especially in the supine position a residual bubble in the ventricle with clear cut fluid level. The bubble existed above the level of the aortic outflow tract. This bubble was asymptomatic as judged from electrocardiograms, blood pressure, ventricular pressures and respiration. Aspiration of several of these bubbles via the catheter which was in place showed the volume to be less than 10 cc (fig. 4). Chemical analyses at 30 seconds to 1 minute after injection showed these bubbles to contain as high as 10.7–19.4% oxygen and 3.6–29.9%  $\text{CO}_2$ . It should be pointed out that it was not possible to obtain gas samples in this situation which were entirely free of blood foam. Such residual bubbles gradually became smaller and disappeared during 30 minutes.

Changes in blood pressure and respiration were minor and of short duration following introduction of  $\text{CO}_2$  gas into the left ventricle. A few extrasystoles were observed. These were produced mostly during the period of injection. Briefest effects on circulation and respiration were obtained in the right side down position.

*Cardiovascular-respiratory effects (fig. 5).* Systemic blood pressure depression was not marked regardless of the animal's position during injection of the gas. Longest durations were in the left side down position. Respiration was hardly affected at all. Left ventricular diastolic pressures were unchanged. Left

ventricular systolic pressures were briefly decreased in all positions. The duration of depression was longer than 15 seconds only in the left side down position. This is also the position in which a brief mechanical alternans is of longest duration. At this time observation of the peripheral pulse demonstrates a bradycardia but it can clearly be seen that for a few seconds only the larger beats of the alternans produce a peripheral pulse (1). Changes in the electrocardiogram are seen to consist of only a few extrasystoles except in the left side down position where QRS is changed for more than 15 seconds. Air injected into the left ventricle killed all dogs so treated.

**Carbon Dioxide Gas Injected Into the Peripheral End of a Carotid Artery (Fig. 6).** When the full dose of 7.5 ml/kg of carbon dioxide gas was delivered into the headward end of the carotid artery disturbances in respiration, electrocardiograms, blood pressure and heart rate were minimal. Injection here required 15–30 seconds because of the small vascular volume available. However, injections were made as rapidly as possible.

**Use of Carbon Dioxide Gas in Human Cases.** Up to the time this manuscript was submitted three injections of carbon dioxide gas have been made in two hydrancephalic infants (multiple porencephalic cysts) without

untoward effects.<sup>4</sup> Conventional x-ray films made at 1-second intervals produced results not unlike the results herein reported. One baby showed a brief apnea of less than 30 seconds with bradycardia. Recoveries and subsequent courses were uneventful in both cases.

**Use of Oxygen as an Intravenous Contrast Medium.** Ten dogs received intravenous oxygen in doses of 7.5 ml/kg. The results were no better than with air since body position made a marked difference in morbidity and mortality. Animals which recovered did so only after marked and prolonged cardiovascular-respiratory changes over many minutes.

**At Post-Mortem.** No pathological changes in the heart were demonstrated which could be attributed to CO<sub>2</sub> gas which had been injected.

#### DISCUSSION

Teschendorf (10) pointed out that for diagnostic use a gas should persist long enough for visualization of body cavities and then return quickly to solution. He suggested nitrous oxide and carbon dioxide for this purpose but considered the latter somewhat irritating. The intravascular use of gaseous carbon dioxide has been useful in our hands to outline intracardiac structures. In 82 injections there was only one fatality and that on the third exhibition of the gas in this dog.

Anatomic position makes very little difference in the cardiovascular-respiratory responses to injections of CO<sub>2</sub> gas and the durations of effects are in almost every instance of the order of seconds. The only common exceptions to this is the right ventricular systolic pressure which may be elevated for several minutes and the polypnea which lasts a similar length of time. This is probably due to the fact that gas which has been delivered from the ventricle has lodged in the fine pulmonary vessels and elevated the pulmonary peripheral resistance and pressure (1). These observations are in marked contrast to those obtained when air is injected. In this case anatomic position is very important for survival and morbidity. Furthermore, those

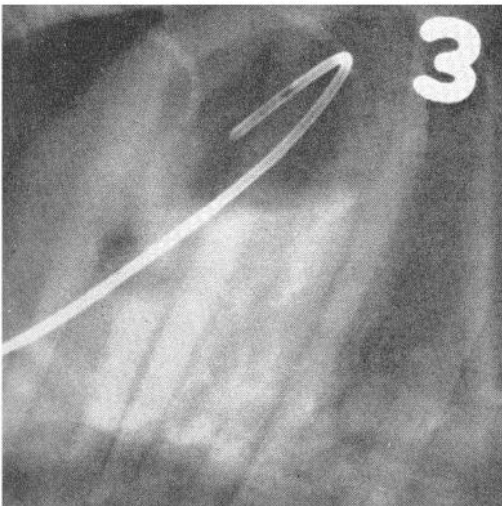


FIG. 4. Bubble in left ventricle after carbon dioxide was introduced via catheter (retrograde via carotid artery). Smaller bubble is seen along course of catheter on aortic side of aortic valve. Animal is supine, sternum at top, ventricular apex in upper right, horizontal x-ray beam.

<sup>4</sup> These cases were obtained at Saint Christopher's Hospital, the Pediatric Department of Temple University Medical Center through the cooperation of Drs. John A. Kirkpatrick and Henry W. Baird.

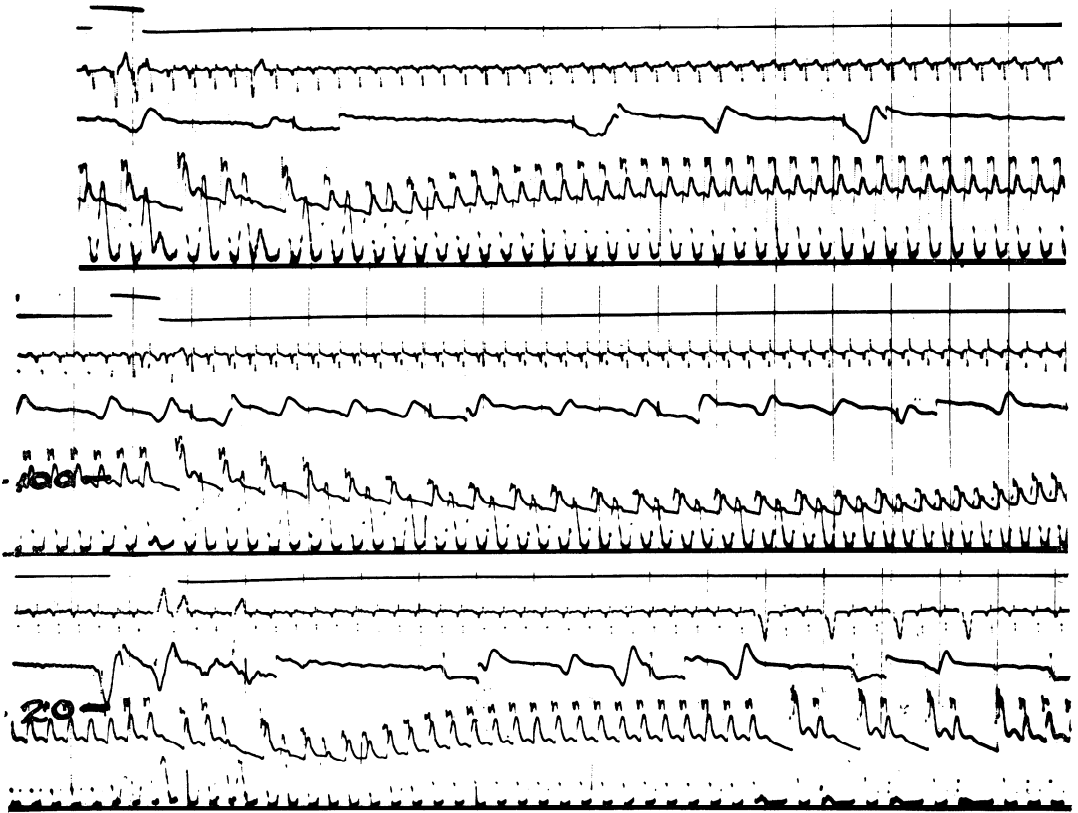


FIG. 5. Effects of carbon dioxide gas introduced into left ventricle by a catheter as shown in fig. 4. From above downward in all three records: signal, break indicates period of injection; aVr of electrocardiogram; intratracheal pressure; femoral blood pressure; right ventricular pressure. Time indicates 1 sec. by faint vertical lines. Calibration at *middle record* for femoral pressure and at *lower* for right ventricle. *Upper*: right side down; *middle*: left side down; *lower*: supine.

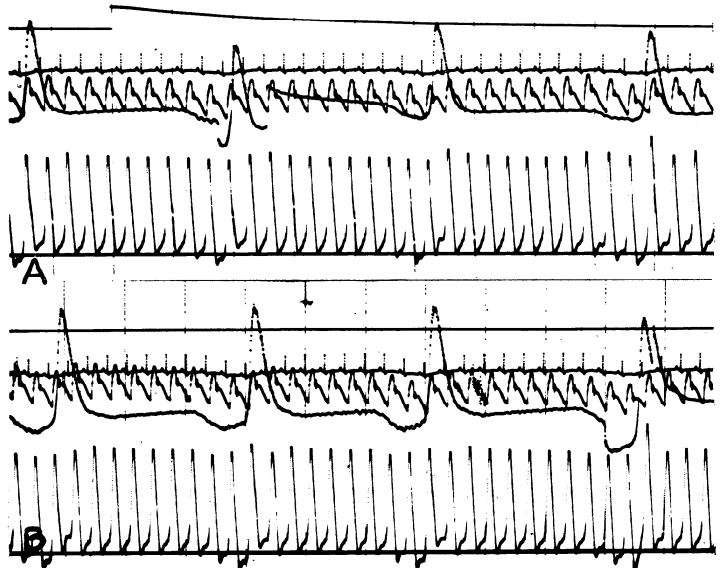
animals which recover do so over many minutes (1, 2).

The right side down position is one in which all animals die with venous air embolism because in this decubitus the pulmonary artery is superior. Air buoyancy lodges the gas there and produces an effective blockade in the outflow tract of this ventricle (1, 2). By comparison, this position seems to be optimal when the more soluble  $\text{CO}_2$  gas is used. In this instance the gas is also carried up into the pulmonary conus but instead of blockade, mixing and high solubility result in the gas being rapidly returned to solution and thus carried away. It should be emphasized however, that the differences in the supine, left and right lateral anatomic positions are not marked when  $\text{CO}_2$  is the gas concerned.

The original thesis of Durant that the left side down position is the best one for survival of venous air embolism (1, 2) because in this

decubitus a continuous column of blood exists from ventricle out into the pulmonary artery is borne out by these experiments. In this position the pulmonary artery is dependent and blood enters it while buoyant air is carried away from the outflow tract up into the right ventricle. Elevated systolic right ventricular pressure may be accepted as a criterion of an increase in pulmonary arterial pressure due to gas delivered there from the ventricle (1, 2, 11). It will be seen that in the left side down position the ventricular systolic pressure actually falls. This would be so because in this position the output of blood from the ventricle continues since there is a continuous column of blood from ventricle into artery although in reduced amount because inflow is reduced since there is gas in the caeve. Also, the stroke volume is necessarily smaller since part of the ventricular volume is occupied by gas which by buoyancy is at first floated up

FIG. 6. Effects of CO<sub>2</sub> gas injected into peripheral end of carotid artery. *A*. From above downward: 1) signal line, CO<sub>2</sub> injection (7.5 ml/kg) begun at upward movement of line, 2) lead I of electrocardiogram, 3) femoral blood pressure, 4) intratracheal pressure changes, 5) right ventricular pressure. *B*. Records same as in 6*A*. First 14 sec. after end of CO<sub>2</sub> injection are shown. Faint vertical lines represent 1-sec. intervals.



away from the dependent pulmonary artery. In a short time turbulence and mixing in the ventricle produce a froth which is delivered into the artery with a consequent elevation of pulmonary artery pressure and resultant elevation in right ventricular systolic pressures. In the supine and right side down position some gas enters the lung field at once and hence the right ventricular systolic pressures rise immediately.

Systemic hypotension after intravenous carbon dioxide was of very short duration. Cinefluorography showed that it corresponded to the period during which gas is present in the right atrium and ventricle. Reflexes from the distended right atrium (12) may play a role in this acute hypotension. However, decreased flow through the lung to the left heart if present, would be also important to decreased left sided output. This mechanical effect is probably minimal since sublethal doses of starch emboli do not lower systemic pressure or decrease the amount of blood going through the lungs (13). The somewhat longer lasting increase in right ventricular systolic pressure is a measure of increased pulmonary pressure. Elevation of perfusion pressure restricted to the pulmonary artery produces polypnea and hypotension (12). This may explain the more persistent increased rate of breathing and a blood pressure which returns to a steady state a little below control values.

The explanation of this persistent increase in pulmonary pressure and resistance after intravenous CO<sub>2</sub> as measured by the relatively long standing elevation in right ventricular pressure may be as follows: a large part of the excess CO<sub>2</sub> is expired in the lungs during the first few breaths as shown by the infrared carbon dioxide analyzer records. There is only .03% CO<sub>2</sub> in inspired air so the record returns to its zero level during each inspiration. The CO<sub>2</sub> can thus diffuse down a steep gradient from pulmonary capillaries to alveolar spaces. Most, but not all, the CO<sub>2</sub> is eliminated in the lungs since concurrent determinations of arterial CO<sub>2</sub> and O<sub>2</sub> show only small deviations from control values. Soon the alveolar CO<sub>2</sub> is actually below control values but the polypnea continues and this points to a reflex origin from lung vessels (12). The small CO<sub>2</sub> bubbles would pass rapidly into solution and their effect disappear if it were not for the fact that nitrogen and oxygen diffuse into them. These gases are less soluble, last longer as bubbles in the lung vessels and account for the more persistent polypnea (12) and return of blood pressure to a steady state a little below control values (12). It was shown that after exercise in relation to air embolism that once CO<sub>2</sub> bubbles were formed in muscle nitrogen flows rapidly into the CO<sub>2</sub> nucleus (14). When bubbles of 50% CO<sub>2</sub> were injected into the blood stream of frogs they tended to loose CO<sub>2</sub> and take up N<sub>2</sub> and O<sub>2</sub>

(15). Moreover, early after injection the bubbles were high in CO<sub>2</sub> in muscles but equilibrated rapidly with the lower CO<sub>2</sub> tensions as they move on to larger vessels. N<sub>2</sub> and O<sub>2</sub> move in as CO<sub>2</sub> is lost (15). This could fit our findings in the left heart bubble as well as explaining longer persistence of bubbles in the lung after intravenous injection. In addition, agitation increases bubble formation (16, 17) and it is possible that this is related to bubble formation in the left heart. Negative pressures may develop as a result of turbulence (18) in the left ventricle. These local decreased pressures are described as vortices with cavitation (17) and would contribute to bubble formation if one were not already present. The necessary turbulence is present in the region of the aortic valves (18).

It is possible that the left lateral decubitus is least favorable as judged by duration of hypotension after left ventricular carbon dioxide injections since the optimal position in arterial gas embolism is midway between left lateral and prone (19). In this latter position the origins of the two coronaries from the aortic sinuses would be dependent and away from gases which are bouyant and stay on top. Thus the left lateral position is not ideal. Neither is the right lateral position the best one as late extrasystoles show. In all three positions tested, however, it should be stressed that disturbances in heart, circulation and respiration are short in duration and of a minor nature.

If a right-to-left shunt existed when CO<sub>2</sub> was given intravenously this would not appear to be especially dangerous since the full dose delivered into the left ventricle produces only brief and minor disturbances in circulation and respiration. In fact, when the full dose of gas is injected into the peripheral end of the carotid artery there were no untoward effects. It is extremely unlikely that any dose of gas delivered into the right heart would find its way entirely into the left side of the circulation and still less probably that all would be carried to the head. When followed

by an image amplifier cinematographic technique the use of CO<sub>2</sub> gas would appear to be valuable to demonstrate shunts between the two sides of the heart. Valvular abnormalities in structure and action could be detected *in vivo*.

#### REFERENCES

1. OPPENHEIMER, M. J., T. M. DURANT AND P. R. LYNCH. *Am. J. Med. Sc.* 225: 362, 1953.
2. DURANT, T. M., M. J. OPPENHEIMER, P. R. LYNCH, G. ASCANIO AND D. WEBBER. *Am. J. Med. Sc.* 227: 509, 1954.
3. VAN SLYKE, D. D., J. SENDROY, JR., A. B. HASTINGS AND J. M. NEILL. *J. Biol. Chem.* 78: 765, 1928.
4. VAN SLYKE, D. D., R. T. DILLON AND R. MARGARIA. *J. Biol. Chem.* 105: 571, 1934.
5. OPPENHEIMER, M. J., T. M. DURANT AND H. M. STAUFFER. 1955 Joint Meetings of the American Physiological Society at Tufts University, Medford, Mass. Paper 118, p. 20.<sup>5</sup>
6. STAUFFER, H. M., M. J. OPPENHEIMER, G. H. STEWART III AND P. R. LYNCH. *J. Appl. Physiol.* 8: 343, 1955.
7. SCHOLANDER, P. F. *J. Biol. Chem.* 167: 235, 1947.
8. VAN SLYKE, D. D. AND J. M. NEILL. *J. Biol. Chem.* 61: 523, 1923.
9. STAUFFER, H. M., T. M. DURANT AND M. J. OPPENHEIMER. *Radiology* 66: 686, 1956.
10. TESCHENDORF, W. *Acta. Radiol.* 36: 297, 1951.
11. HAMILTON, W. F., R. A. WOODBURY AND F. VOGT. *Am. J. Physiol.* 125: 130, 1939.
12. AVIADO, D. M., JR., T. H. LI, W. KALOW, C. F. SCHMIDT, G. L. TURNBULL, G. W. PESKIN, M. E. HESS AND A. J. WEISS. *Am. J. Physiol.* 165: 261, 1951.
13. DUNN, J. S. *Quart. J. Med.* 13: 129, 1920.
14. FULTON, J. F. *Aviation Medicine and Its Preventive Aspects*. London: Oxford, 1948.
15. HARRIS, M., W. E. BERG, D. M. WHITAKER, C. V. TWITTY AND L. R. BLINKS. *J. Gen. Physiol.* 28: 225, 1945.
16. HARVEY, E. N., D. K. BARNES, W. D. MCELROY, A. H. WHITELEY AND D. C. PEASE. *J. Cell. & Comp. Physiol.* 24: 1, 1944.
17. REYNOLDS, O. *Roy. Inst. Proc.* 11: 44, 1887.
18. HARVEY, E. N. *Bull. New York Acad. Med.* 21: 595, 1945.
19. DURANT, T. M., M. J. OPPENHEIMER, M. R., WESTER AND J. H. LONG. *Am. Heart J.* 38: 481, 1949.

<sup>5</sup> This is a 16-mm moving picture concerning CO<sub>2</sub> visualization of intracardiac structures and may be obtained on loan from M. J. Oppenheimer.