

82. Rollins NK, Timmons C, Superina RA, Andrews WS. Hepatic artery thrombosis in children with liver transplants: false-positive findings at Doppler sonography and arteriography in four patients. *AJR* 1992;160:291-294.
83. Wellings RM, Oliff SP, Oliff JFC, Deakin M, Alton H. Duplex Doppler detection of hepatic artery thrombosis following liver transplantation. *Clin Radiol* 1993;47:180-182.
84. Abad J, Hildago E, Cantarero J, et al. Hepatic artery anastomotic stenosis after transplantation: treatment with percutaneous transluminal angioplasty. *Radiology* 1989;171:661-662.
85. Taylor J, Morse S, Weltin G, et al. Liver transplant recipients: portable duplex US with correlative angioplasty. *Radiology* 1986;159:357-363.
86. Wozney P, Zajko AB, Bron KM, et al. Vascular complications after liver transplantation: a 5-year experience. *AJR* 1986;147:657-663.
87. Rossi AR, Pozniak MA, Zarvan NP. Upper inferior vena caval anastomotic stenosis in liver transplant recipients: Doppler US diagnosis. *Radiology* 1993;187:387-389.
88. Harder D, DeMarino G, Sumkin J, et al. Liver transplant rejection: value of the resistive index in Doppler US of hepatic arteries. *Radiology* 1989;173:127-129.
89. Longley D, Skolnick M, Sheahan D. Acute allograft rejection in liver transplant recipients: lack of correlation with loss of hepatic artery diastolic flow. *Radiology* 1988;169:417-420.
90. Kubota K, Billing H, Ericson B-G, Kelter U, Groth CG. Duplex Doppler ultrasonography for monitoring liver transplants. *Acta Radiol* 1990;31(3):279-283.
91. Propeck PA, Scanlan KA. Reversed or absent hepatic arterial diastolic flow in liver transplants shown by duplex sonography: a poor predictor of subsequent hepatic artery thrombosis. *AJR* 1992;159:199-201.
92. Britton PD, Lomas DJ, Coulden RA, Farman P, Revell S. The role of hepatic vein Doppler in diagnosing acute rejection following paediatric liver transplantation. *Clin Radiol* 1992;45:228-232.
93. Sutherland DER, Dunn DL, Goetz FC, et al. A ten-year experience with 290 pancreas transplants at a single institution. *Ann Surg* 1989;210:274-288.
94. Snider J, Hunter D, Kuni C, et al. Pancreas transplantation: radiographic evaluation of vascular complications. *Radiology* 1991;178:749-753.
95. Nghiem DD, Ludrosky L, Young JC. Evaluation of pancreatic circulation by duplex color Doppler flow sonography. *Transplant Proc* 1994;26(2):466.
96. Kubota K, Billing H, Kelter U, Tibell A, Tyden G, Groth CG. Duplex-Doppler ultrasonography for evaluating pancreatic grafts. *Transplant Proc* 1990;22(1):183.
97. Gilbert R, Bru C, Ricart MJ, et al. Pancreatic transplant rejection: evaluation by duplex-Doppler ultrasound with urinary amylase monitoring correlation. *Transplant Proc* 1992;24(1):11.

Part 5. Carbon Dioxide Digital Subtraction Angiography

Irwin Hawkins and Manuel Maynar

Although significant advances in ultrasound, computed tomography (CT), and magnetic resonance imaging (MRI) have occurred in vascular imaging, angiography continues to be the gold standard. Presently, angiography is the imaging modality of choice during the performance of interventional vascular procedures and is still widely used for the majority of nonvascular interventional procedures. Although the newer nonionic contrast agents have a very low complication rate, they are still associated with renal failure and and severe allergic reactions, and they are very expensive (1).

Carbon dioxide (CO₂) as a contrast agent is not associated with renal failure or allergic reactions (2-6). Combined with advances in digital subtraction angiography (DSA) imaging, it is a viable alternative to iodinated contrast agents. It also occasionally provides additional information that cannot be obtained with iodinated contrast material, such as (a) demonstration of collateral arteries (3); (b) arteriovenous shunting in tumors (3,7); (c) opacification of tumors that appear avascular with iodinated contrast; (d) detection of minute bleeding, and (e) demonstration of the portal system with wedged hepatic venography (8).

HISTORY

CO₂ was first injected retroperitoneally in 1914 to demonstrate abdominal structures radiographically (9). In the 1950s, CO₂ was used intravenously for the detection of pericardial effusion (10,11). The patient was placed in the left lateral decubitus position, and 100-200 mL of CO₂ were injected into an antecubital vein. The CO₂ was trapped in the right atrium, permitting detection of the pericardial effusion between the gas density in the right atrium and the gas density of the lung.

Before CO₂ was used in patients, it underwent extensive animal testing, both intraarterially and intravenously (12). Very large volumes of CO₂ could be injected intravascularly with only minimal transient changes in intraarterial blood gas composition. In dogs, up to 100 mL/min (a total of 10,000 mL) of CO₂ could be injected, since the CO₂ was eliminated by the lungs (13). If very large volumes of CO₂ were injected over a short period of time, the CO₂ could totally displace the blood from the right heart, and a "vapor lock" phenomenon could result in the animal's demise. In the 1960s, CO₂ was also used for the evaluation of the hepatic veins (14). In 1971, we started using CO₂ as an arter-

ial contrast agent with a cut film subtraction technique, delivering the CO₂ with a hand syringe (15). Diagnostic images were obtained; however, the photographic subtraction techniques were time-consuming and, in general, produced suboptimal images. In 1980, with the acquisition of a digital subtraction angiography unit that was coupled to a Philips tilting table x-ray unit, this low-density contrast agent could be reliably and expediently imaged (3). Currently, we have used CO₂ in over 100 laboratory animals and over 900 patients with satisfactory diagnostic images obtained in the majority of cases (16). Initially, CO₂ was used only in patients who had severe iodinated contrast allergies. Presently, it is being used in patients with renal failure and is indicated for any patient who requires standard iodinated contrast material for vascular imaging, with the exclusion of the arterial cerebral circulation. Recently, CO₂ has been employed for the detection of minute amounts of arterial bleeding, imaging of the venous system, both peripheral and central, and most recently for the demonstration of the portal vein during transjugular intrahepatic portosystemic shunt (TIPS) procedures (8). CO₂ also provides good visualization of the portal system after a fine needle and guide wire are advanced into the portal vein. Several prototype injectors have been developed, but the commercial version will not be available for some time; it currently awaits Food and Drug Administration (FDA) approval. Recently, we developed an inexpensive, closed,

hand-delivery system, which can be assembled from readily available angiographic fittings.

Over the 5 five years, there has been considerable improvement in DSA equipment. The now readily available 1024 × 1022 × 10-bit systems have improved both contrast and resolution. The most notable advance has been the development of a "stacking" software program, with which very small amounts of CO₂ can be injected, and by the rapid acquisition and addition of these images, the CO₂ can be followed distally. A diagnostic composite image is obtained without the patient being aware of the injection, because of the small amount of gas injected.

UNIQUE PROPERTIES OF CARBON DIOXIDE

In general, the images that are obtained with CO₂ are frequently identical to those obtained with iodinated contrast medium (Fig. 7.5.1). The physical properties of CO₂, however, are very different from those of liquid contrasts. When injected into the vascular system, iodinated contrast material mixes with blood. The density of the image can be improved by increasing the injection rate or the concentration of the iodine. The contrast then must be eliminated from the vascular system by glomerular filtration.

Conversely, CO₂ displaces blood and is imaged by the differential density of the gas compared to the surrounding soft tissues. Unlike iodinated contrast, if the CO₂ totally dis-

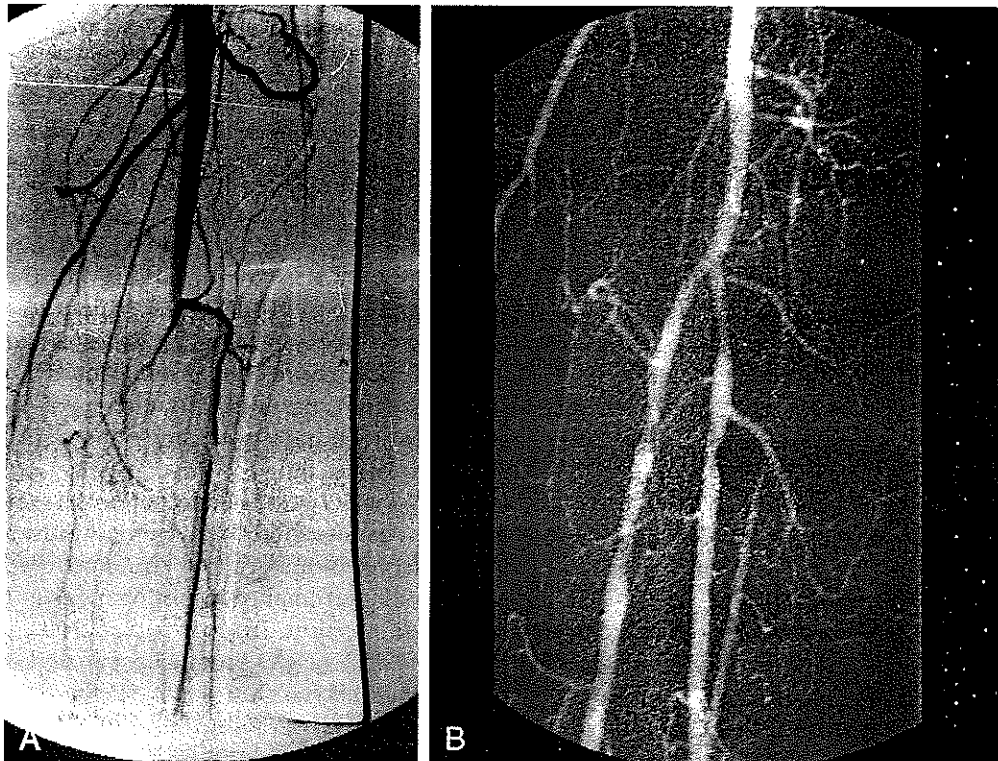


Figure 7.5.1. Comparison of iodinated contrast with CO₂. **A.** Antegrade injection of 5 mL of ionic contrast, demonstrating complete occlusion of the tibioperoneal trunk and severe stenosis of the proximal anterior tibial

artery. **B.** DSA CO₂ image of postfibrinolysis and percutaneous transluminal angioplasty of TP trunk. Note good filling of small vessels and comparable imaging of the major vessels with 10 mL of CO₂.

places the blood, additional CO₂ will simply reflux proximally without improving the image. The image can only be improved by DSA enhancement. Thus, if any patient motion occurs, the image is degraded. The lack of mixing of the blood prevents dilution by blood coming through collaterals, as occurs with iodinated contrast. For example, if cross-pelvic collaterals (hypogastric, etc.) fill the contralateral common femoral artery, the density of the CO₂ is not altered by dilution from the more proximal collateral arteries. The collateral flow may, however, interrupt the CO₂ column and produce short segments. This segmentation can now be overcome with the use of a new software stacking program. The stacking is similar to the maximum opacification in which, rather than recording the peak density of the contrast, the valley of the lowest negative density is recorded, and multiple images are integrated to produce a single composite image of the vascular anatomy (Fig. 7.5.2). This stacking program permits diagnostic imaging with very small injections of CO₂. Theoretically, a single bubble can be injected, and if it is filmed at a very rapid rate, the addition of all of these images will produce a single composite diagnostic image without any physical sensation whatsoever and, thus, no motion. Several x-ray manufacturers currently provide the stacking programs. This software has been available for over 10 years from ADAC. It basically uses the functional image mode with maximum opacification. However, the polarity of the image must be changed to the positive mode before the images can be integrated. Excellent stacked images can be obtained with the Toshiba and General Electric (GE) equipment. Recently, an instantaneous stacking program has been added to a tilting-table C-arm unit (Siemens). Philips will also shortly offer CO₂ stacking software.

Unfortunately, since CO₂ is inherently never as dense as iodinated contrast, it requires meticulous imaging techniques. Patient motion and peristaltic bowel motion markedly degrade the images and make stacking virtually impossible.

The Importance of Buoyancy

The extreme buoyancy of CO₂ offers both advantages and disadvantages. If an inadequate amount of CO₂ is injected into a large luminal structure, only the top portion will be filled; thus, imaging of the diameter may be spuriously reduced. If one uses the analogy of injecting helium in an inverted hollow tree, only the trunk will fill. If the tree is lying on its side, only the nondependent branches will fill. All the branches will fill if the tree is in its normal upright position. In clinical situations, elevating the area of interest above the injection site always improves filling; however, if there is good arterial flow, the lower extremities will fill adequately in the majority of cases, even with the legs in the horizontal position. Since the superficial femoral artery flows downward from the groin to the popliteal area, in patients with poor flow, CO₂ frequently cannot be detected below the knee (Fig. 7.5.3). Elevation

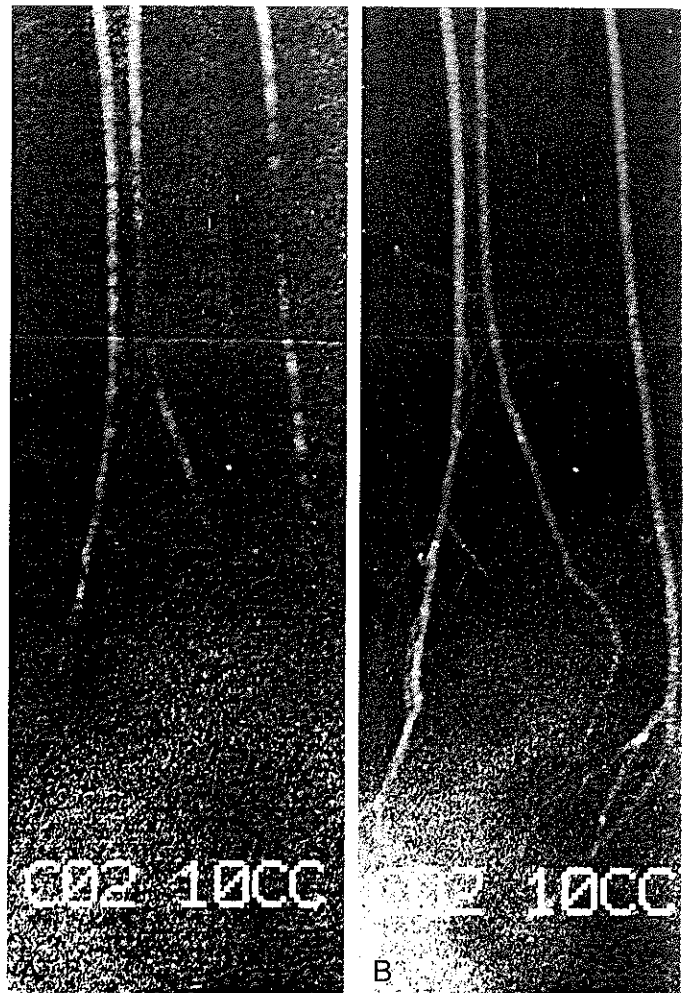


Figure 7.5.2. Lateral view of ankle and foot demonstrating advantages of the stacking software. **A.** Retrograde injection of only 10 mL of CO₂ demonstrates multiple, short segments of CO₂ incompletely filling the anterior tibial, peroneal, and posterior tibial arteries. **B.** Composite (stacking) image showing good opacification of distal arteries, including the lateral and medial plantar arteries. Without stacking, over 50 mL of CO₂ would be required, with the possibility of producing some discomfort and thus motion.

of the feet 15–20 degrees greatly improves the filling of the more distal vessels. In a prospective study, we compared filling of the popliteal artery and the trifurcation with the legs flat and elevated in 30 patients with atherosclerotic vascular disease (15). The majority of these studies were nondiagnostic with the patients flat; all were diagnostic with the feet elevated.

The buoyancy is also important in the abdominal aorta. All the anterior vessels, including the celiac, superior mesenteric artery (SMA), and inferior mesenteric artery (IMA) will fill with very small amounts of CO₂ (10 mL) (Fig. 7.5.4). These vessels are well imaged with cross-table filming. Conversely, the posteriorly positioned lumbar arteries usually are only well imaged when they serve as collaterals. In patients who have marked vascular stasis (such as in a stenotic graft, stasis in large aneurysms, and large vascular tumors),

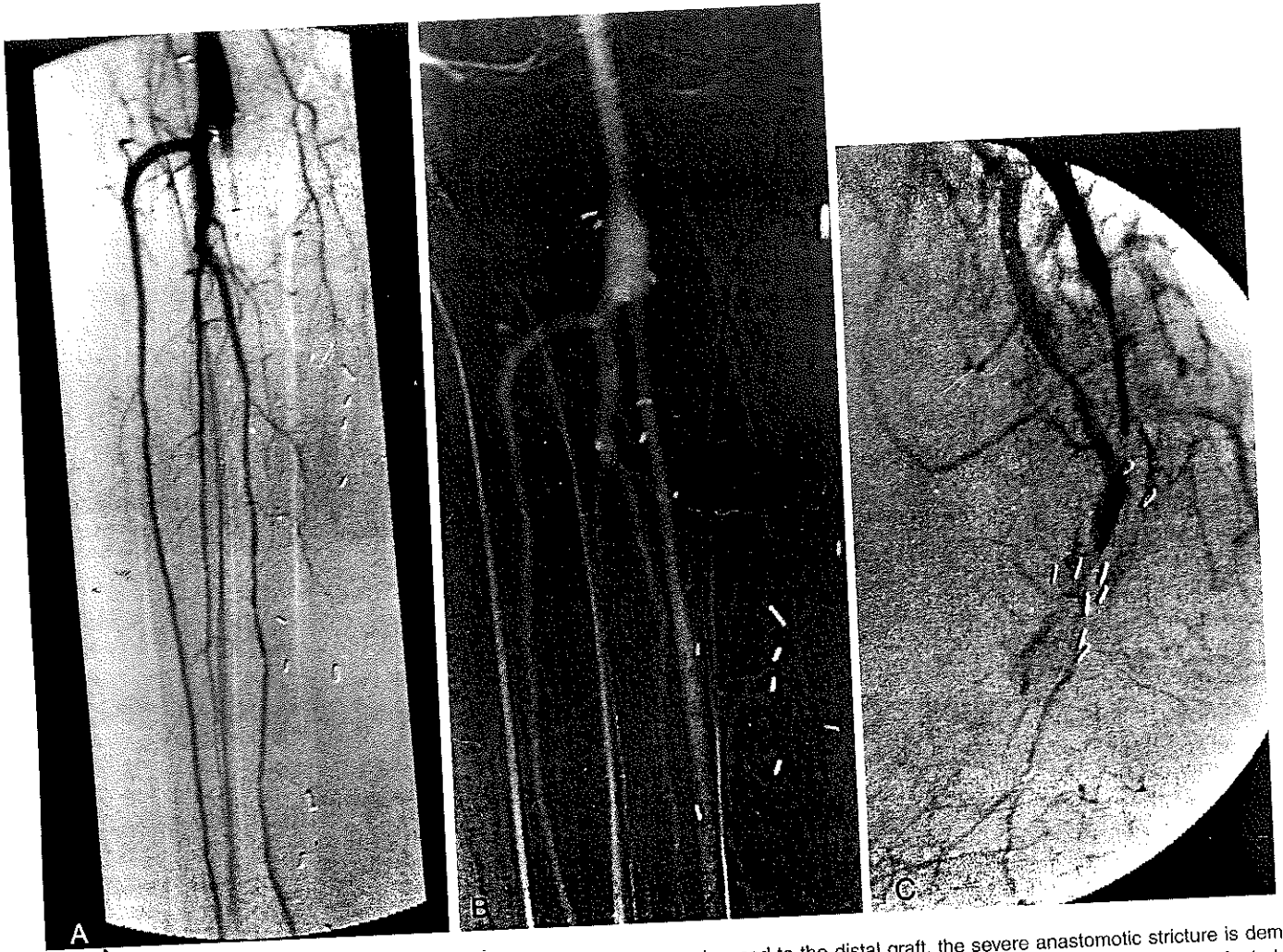


Figure 7.5.3. Importance of elevation. **A.** Apparent total occlusion of a distal posterior tibial vein graft with iodinated contrast. **B.** With the feet elevated, the vein graft is readily filled with CO₂. **C.** With the 3F catheter

advanced to the distal graft, the severe anastomotic stricture is demonstrated. The extreme buoyancy of CO₂ readily fills nondependent structures, even when there is little or no flow present.

the CO₂ fills these structures by displacing this static blood by buoyancy alone (Fig. 7.5.3).

Although the buoyancy can be used to an advantage, the possibility exists that CO₂ could be trapped in any nondependent area (such as nondependent portions of the liver, SMA, IMA, transplanted kidneys; and the feet in an elevated position). When the legs are elevated, the CO₂ will float to the toes. If multiple CO₂ injections are performed rapidly in patients with poor arterial flow, CO₂ may become trapped distally. If CO₂ is injected in small volumes, its marked solubility in blood (20 times that of oxygen) will result in rapid reabsorption of the trapped CO₂ gas, usually in as short a time as 20 seconds to 2 minutes. If large volumes of CO₂ are injected very rapidly (less than once every 30 seconds), the entire vessel will be filled, and there will be very little reabsorption of the CO₂, resulting in a vapor lock phenomenon and possible ischemia. We recommend either waiting 2–5 minutes between injections in these situations or changing the position of the organ to free the CO₂.

We frequently observe trapping of CO₂ in abdominal aneurysms. One complication that definitely could be attributed to trapping was transient severe diarrhea in a patient in whom over 2000 mL of CO₂ were injected within 1 hour into a large abdominal aneurysm. The IMA which arose from this aneurysm was exposed only to CO₂ for a period of time, and since there was no inflow from collaterals into this distribution, this caused a transient ischemic episode.

In studying abdominal aneurysms, we recommend changing positions to release the CO₂ because, in addition to possible ischemia of the IMA, there is also the risk of having the trapped CO₂ replaced by oxygen and nitrogen. This may occur secondary to high partial pressure of CO₂ in the aneurysm, as compared to the high partial pressure of nitrogen and oxygen in the blood. We have seen small amounts of gas in the anterior part of aneurysms on CT examinations in patients who have had CO₂ injected 24 hours prior to the CT examination (16).

Since CO₂ dissolves very rapidly, it is speculated that the retained gas represents oxygen or nitrogen. Fortunately, we

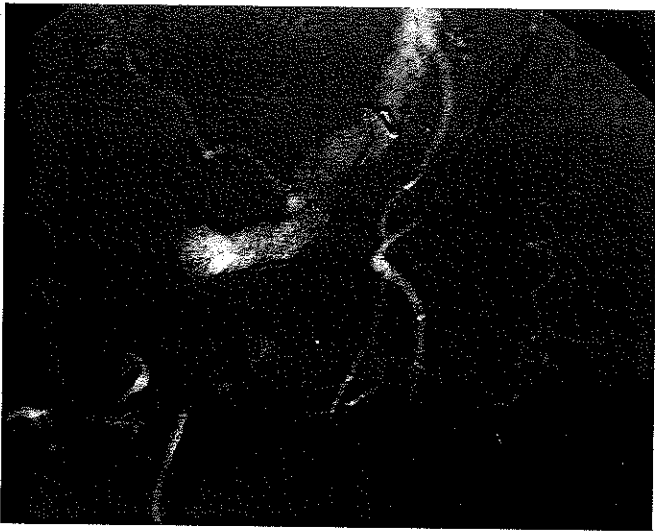


Figure 7.5.4. Ten mL of CO₂ injected in a large abdominal aneurysm with a spiral 4 Fr "halo" catheter. The buoyancy of the CO₂ readily filled the inferior mesenteric artery with a good capillary blush, noted on late films. An anteriorly located accessory right lower pole renal artery is also demonstrated, which was not demonstrated with the iodinated contrast secondary to dilution of the liquid contrast in the large aneurysm.

have not experienced any other complication related to trapping of the CO₂ in abdominal aneurysms.

Low Viscosity

The low viscosity of the CO₂ permits the use of very small catheters. Relatively easy injections can also be performed with the guide wire in place, by using a Touhey-Bourst fitting. We routinely use 3 and 4 French (Fr) catheters; however, the CO₂ can be delivered through catheters as small as 1.5 Fr. We feel that the low viscosity is also a major reason why (a) arteriovenous (AV) shunting in malignant tumors is demonstrated only with CO₂, (b) collateral vessels fill better, and (c) there is improved detection of minute amounts of arterial bleeding.

DELIVERY SYSTEM

Although CO₂ has many advantages over iodinated contrast, it has not become popular because it is extremely difficult to deliver in a consistently safe manner. It is invisible, compressible, and heavier than air. Its invisibility can result in undetected air contamination. It is well known that small amounts of air in the cerebral circulation can result in infarction and possibly death. One must be assured that the CO₂ is pure and that there are no leaks in the system. We have found that several of the medical grade CO₂ cylinders had been contaminated with water, rust, and particulate material. For several years, we have been using disposable CO₂ cylinders (Altair Gases, Inc., San Francisco, CA) and have used multiple submicron filters to prevent contamination.

New Developments in Carbon Dioxide Delivery

In 1970, we noted that hand delivery of CO₂ resulted in inconsistent images. Experimentally, we found that if 100 mL of CO₂ were delivered over 4 seconds with a plunger moving forward at a rate of 25 mL/sec, only 1–2% of the CO₂ would initially be delivered, with over 95% of the CO₂ being delivered during the last one-half second (basically, an explosive delivery injection rate well over 200 mL/sec). Since the hand delivery of CO₂ was inconsistent, we felt that a mechanical injector might deliver the CO₂ more consistently. Since we had experienced fatalities in animals using the CO₂ directly connected to the cylinder, we elected to flush the syringe and disconnect the cylinder between CO₂ injections (3). This required purging the system with CO₂ after each injection. Since the cylinder is filled by a high-pressure tank, more than 100 mL would be loaded. This required venting the syringe to room air pressure to allow the excess amount of CO₂ to escape. We also found that it was very important to load the correct amount of CO₂ to be injected. When larger amounts were loaded, the CO₂ would simply compress, and only a small amount of CO₂ would be delivered (i.e., if 50 mL are to be delivered, only 50 mL should be loaded).

During the last 10 years, we have developed several dedicated injection systems, which utilized multiple transducers to maintain a constant pressure during delivery. The most important principle learned from developing a dedicated injector was the importance of clearing the saline from the catheter before the bolus of the CO₂ was delivered. This eliminates the problem of explosive CO₂ delivery. The latest version of the injector uses a computer to determine the amount of CO₂ to be delivered in order to completely displace the blood. Multiple high-speed valves and transducers allow the injection of more CO₂ during systole and less during diastole to totally displace blood during the cardiac cycle. The latest injector also uses an automated closed saline system with multiple one-way check valves to prevent reflux of blood into the system. The saline flush is stopped during the CO₂ injection and automatically resumes at the termination of the injection. There is also a transducer attached to the angiographic catheter which provides constant intravascular pressure monitoring and assures accurate delivery during systole and diastole. This injector has been used at the University of Florida, in the Canary Islands, and Australia in over 700 patients with excellent results. The injection flow rates and total volumes are programmed into the computer, and the precise volume of CO₂ is injected. A mass flow meter measures the rates and volumes and displays the actual flow rates and volumes on a liquid crystal screen at the termination of each injection. The injector will be available in most countries outside the United States in mid-1995. Unfortunately, it will not be approved by the FDA until probably 1997.

We have recently attempted to use the principles learned from the development of the dedicated injector for a hand-

held delivery system. We used a liquid contrast reservoir system (Fluid Management System, Angiodynamics; Glenn Falls, NY) with essentially no modifications to deliver CO₂ in a much more controlled manner without the possibility of air contamination. The primary dangers during delivery of CO₂ are air contamination and the delivery of excessive volumes of CO₂.

Plastic Bag Hand-Delivery System

Our animal experience taught us not to connect the CO₂ cylinder to any closed system. However, recently we felt that the addition of a two-way stopcock would prevent any misadventures. Recently, when using a new closed system connected to a CO₂ cylinder, a large volume of CO₂ was delivered inadvertently into the right atrium, which resulted in a near fatality (severe bradycardia and hypotension). Because of the extreme solubility of the CO₂ and the short duration of the delivery, the patient recovered uneventfully. Since this event, we use only the dedicated injector port of a closed system in which a plastic bag serves as a CO₂ reservoir. This system had previously been used as a fluid management system (Angiodynamics, Glenn Falls, NY). A similar system can be easily assembled using a standard 1500-mL plastic IV bag, two connecting tubes, and several two- and three-way stopcocks. The Angiodynamic's fluid management system uses T fittings with two one-way check valves, which obviates the cumbersome turning of the stopcocks.

Hand-Delivery Procedure

Initially, the IV bag is filled and flushed three times with 1500 mL of medical grade CO₂. Since the bag is filled to atmospheric pressure and collapses incrementally when the CO₂ is aspirated, there is no gas compression, and the exact amount of CO₂ that is to be delivered can be loaded. After all of the air has been flushed from the plastic bag and it is filled with CO₂, the bagged CO₂ is used to purge the system and fill either the hand-delivery syringe or a mechanical injector syringe. The first three-way stopcock is used to fill the delivery syringe and inject the CO₂; the second permits use of a 3-mL syringe, which is used to clear the saline from the angiographic catheter before the main bolus of CO₂ is delivered. The two systems are connected with a long connecting tube to increase the distance from the image intensifier, thereby decreasing radiation to the operator. A two-way stopcock is interposed between the 3-mL stopcock system and the catheter. It is closed after the saline is flushed from the catheter to prevent reflux of blood into the system. Immediately before the definitive injection is to be made with either the larger hand-held syringe or a mechanical injector, the two-way stopcock is opened and the injection ensues. If one does not close the two-way stopcock after the injection, blood will reflux into the system and must be cleared before additional injections can be made. The three-way stopcock system is usually reliable; however,

it requires multiple manipulations of stopcocks, and frequently the stopcocks are turned to an incorrect position, which can result in aborted DSA acquisitions.

Since the system is totally closed, that is, all the components are in place and there is no connection to outside air, the system is totally safe. One should be sure that the Luer-lock connectors do not separate; preferably, they should either be taped or glued together.

Fortunately, the fluid management system has all its connections glued together. Rather than using three-way stopcocks, this system uses T connectors equipped with one-way check valves. Using these check valves instead of the three-way stopcocks permits rapid filling and emptying of both the delivery syringe and the 3 mL catheter-purging syringe. The one-way check valves totally prevent reflux into the catheter after the saline has been purged from the catheter. Opening and closing of only one stopcock is required. There is a two-way stopcock placed between the T connector and the 3 mL syringe. Closing the stopcock connected to the 3 mL syringe after it is emptied prevents filling of this syringe during delivery of the larger CO₂ bolus. If the injections are made relatively rapidly, there is no need to use the 3 mL syringe, since the catheter remains filled with air. If there are extended intervals between CO₂ injections, the catheter can be flushed by the addition of a three-way stopcock attached to the angiographic catheter. With the resistance of the fluid in the catheter eliminated, the syringe to inject the CO₂ can be advanced forward with little force, with virtually no compression of the gas nor an explosive delivery.

The injection rates are quite similar to those used with the dedicated injector. For abdominal aortography using the dedicated injector, 140 mL/sec are injected for a total of 70 mL (Fig. 7.5.5). For hand delivery of the CO₂, a 60-mL syringe is

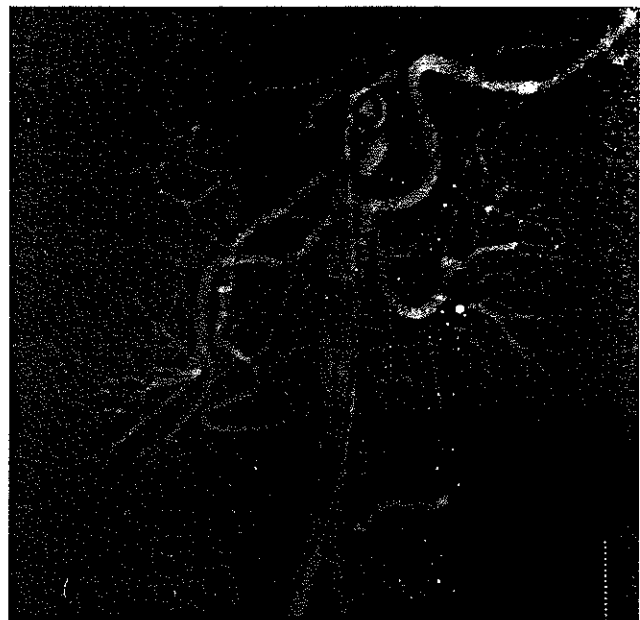

Figure 7.5.5. Aortogram obtained with the dedicated injector (140 mL/sec for a total of 70 mL).

used, and the injection is made in less than one-half second. For pelvic and femoral runoff in both lower extremities, with filming from the pelvis to the trifurcation area, an injection of 40 mL/sec for a total of 60 mL is usually adequate. Occasionally, larger volumes are needed in slow flow states to obtain adequate filling below the trifurcation and the feet. If stacking software is available, smaller volumes are required. If injections into the distal aorta fail to fill the extremity, vascular imaging is always markedly improved if the catheter is advanced over the bifurcation as close as possible to the area of interest. With contralateral, "over-the-hill" common femoral injections, usually 10 mL/sec for a total of 20 mL produces good vascular opacification down to and including the feet. The same is true for an injection with the catheter retracted to the ipsilateral common femoral artery. In over 50% of cases, the intraarterial administration of 100–150 μ g of nitroglycerin also improves the visualization, and frequently will result in less segmentation of the CO₂ (Fig. 7.5.6). If stacking is

not available and segmentation occurs, a longer injection and a vasodilator are recommended.

We attempt, especially with stacking, to inject the smallest amount of CO₂ that will produce good opacification, since with small injections there is no physical sensation of pain whatsoever, resulting in a lower probability of patient motion. In addition, with small volumes sequential injections can be made more rapidly (Fig. 7.5.7).

The CO₂ cylinder should never be connected directly to the delivery system, since even with arterial injection, the gas will flow through the capillary arterial bed into the inferior vena cava and to the heart (Fig. 7.5.8).

Use of Small Catheters

The low viscosity of CO₂ permits very high flow rates through very small catheters. When these catheters are filled exclusively with saline or CO₂, they are difficult to visualize fluoroscopically. At the present time, several companies have developed small catheters with a radiopaque tip or a metallic tip marker.

Experimental studies have shown that the high-velocity jets of CO₂ are markedly less traumatic than those of liquid contrast; however, if an end-hole catheter becomes subintimally placed or wedged under a plaque, there is a potential danger of extensive subintimal dissection. This is exacerbated by the low viscosity of CO₂. (CO₂ was used previously for coronary endarterectomies, and barotrauma from mechanical lung ventilators has resulted in extensive subcutaneous gas dissection.) For this reason, we prefer either the halo catheter (spiral catheter with multiple side holes in the inner curvature) or a standard pigtail catheter. For selective catheterization, a small side hole close to the single end hole will serve as a safety valve if wedging of the tip does occur.

DIAGNOSTIC EFFICACY OF CARBON DIOXIDE DIGITAL SUBTRACTION ANGIOGRAPHY

The physical properties of CO₂ gas are very different from those of a liquid iodinated contrast medium. This mandates excellent technique, including a learning curve for proper interpretation. If there is total displacement of blood from the vessel, evaluation of the area of interest, no motion during image acquisition, and optimal DSA image acquisition, the images are essentially identical to those obtained with iodinated contrast medium. Because of the low density of CO₂, the capillary phase is barely perceptible (17–21). Several publications have described overestimation of the degree of stenosis using CO₂ angiography (4,6). Overestimation occurs mainly in large-diameter vessels where inadequate delivery rates fill only the nondependent portion of the lumen. If the stenosis is located in the nondependent portion, the CO₂ may be further displaced from the lumen, and the degree of stenosis becomes exaggerated. When a lesion is seen, the vessels should be imaged in

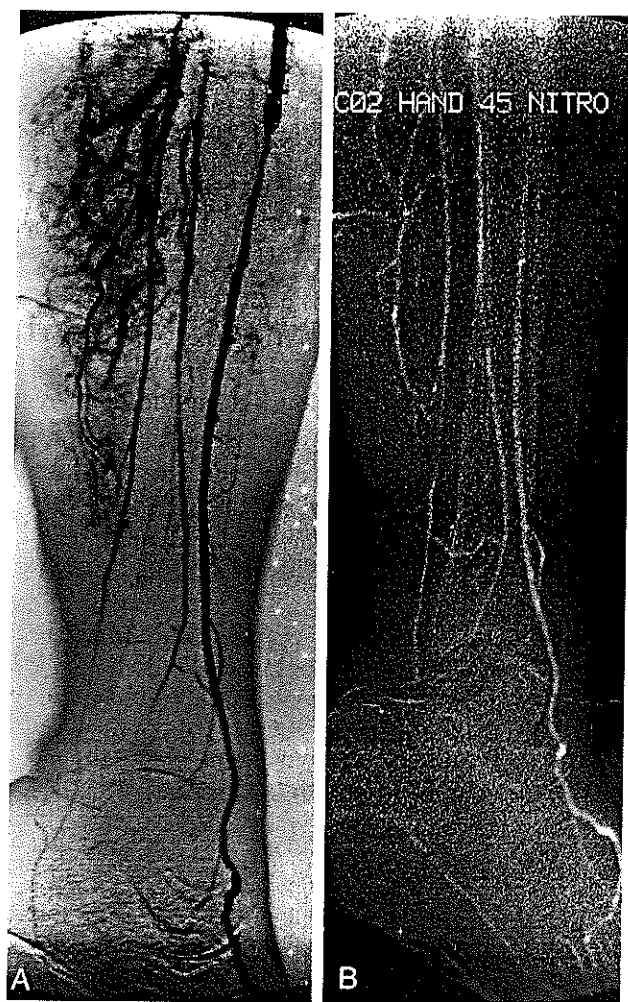


Figure 7.5.6. Comparison of nonionic contrast to CO₂ with intraarterial nitroglycerin. **A.** Large-volume nonionic contrast injection demonstrates good distal arterial filling. Note capillary blush and venous return in the calf secondary to the large amount of contrast. **B.** The intraarterial infusion of the 150 μ g of nitroglycerin followed by the injection of 45 mL of CO₂ produces filling comparable to that obtained with the nonionic contrast.

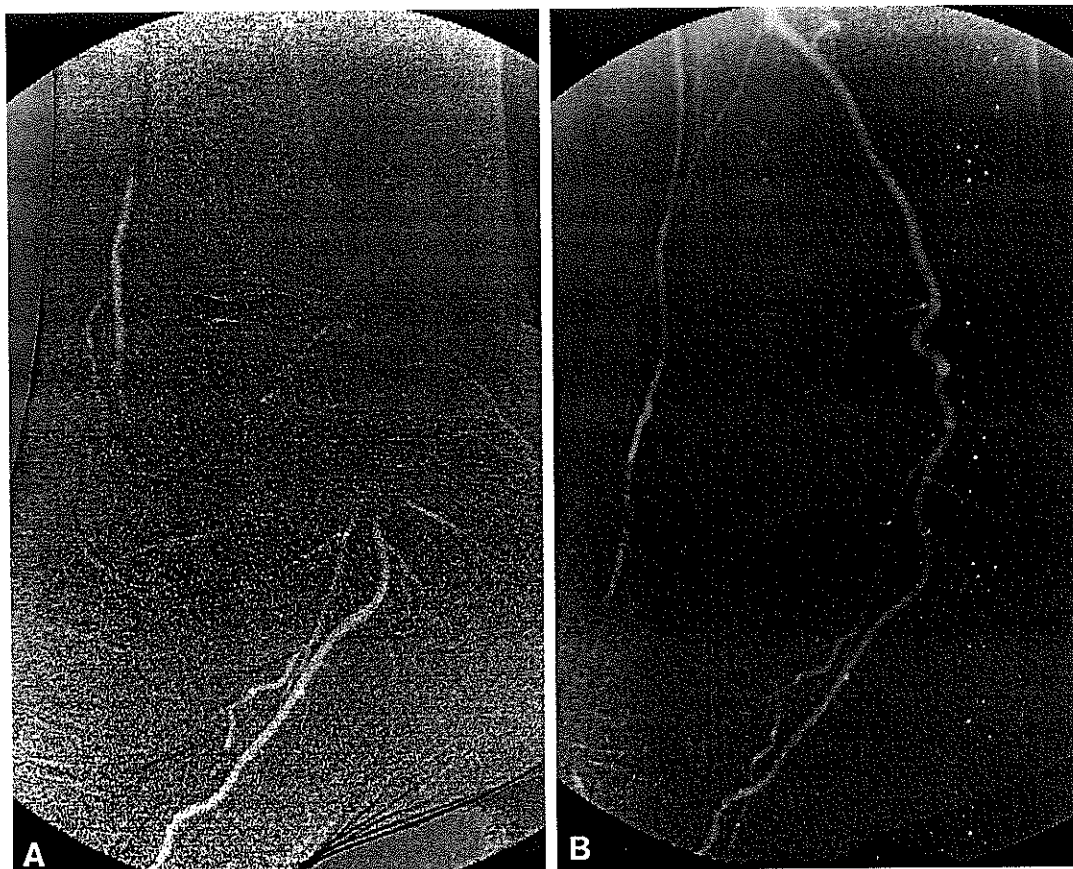

Figure 7.5.7. Value of stacking software. **A.** Only segments of CO_2 fill the distal arteries. **B.** Stacked composite image demonstrates reconsti-

tution of posterior tibial artery via the peroneal artery, with the anterior tibial artery filling late via small collaterals.

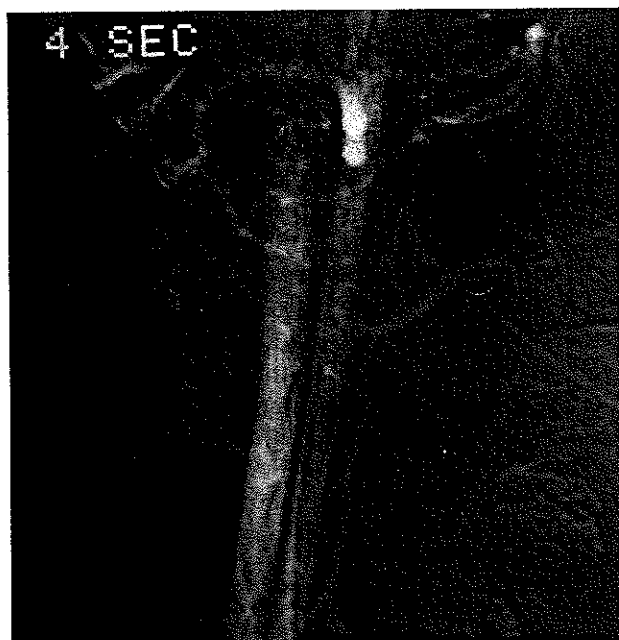


Figure 7.5.8. Canine aortogram (20 mL of CO_2 injected into the aorta) demonstrates filling of the inferior vena cava at 4 seconds. Apparently, either CO_2 flows through the capillary bed or there is rapid AV shunting with large injections of CO_2 . The venous phase is not normally seen with smaller doses of CO_2 in humans.

several projections, the injection rate should be increased, or the catheter tip placed as close as possible to the suspected lesion. As mentioned previously, the buoyancy of CO_2 requires that an attempt should always be made to place the area of interest in a nondependent position.

The left renal artery is occasionally difficult to visualize in older patients because the aorta tends to be rotated in a counterclockwise direction, which results in the left renal artery being posteriorly located. Commonly, elevation of the left side will allow adequate filling of the left renal artery; however, if after two aortic injections the left renal artery is not filled, it is more expedient to exchange the pigtail catheter for a 4 Fr radiopaque shepherd's crook catheter, and selectively catheterize the left renal artery. The left side is then elevated, and a selective injection of 30–40 mL usually provides good filling of the renal artery with reflux into the aorta.

Surprisingly (in small and medium-size vessels), the diagnostic accuracy is similar to that with iodinated contrast medium. In several cases, buoyancy and lack of dilution has resulted in filling far superior to that with iodinated contrast. By elevating the contralateral extremity in a patient with an occluded iliac artery, a small amount of CO_2 can be injected into the ipsilateral common femoral artery area, and the CO_2 will bubble through the external pudendal artery collaterals into the contralateral elevated common femoral artery.

These bubbles will flow all the way and result in a diagnostic study down to the foot. Similar injections with contrast will only fill the ipsilateral extremity, and if the contrast did cross the pelvis, it would be markedly diluted by collateral flow via the inferior epigastric and lumbar arteries, and so forth.

If the CO₂ study fails to demonstrate one area due to patient motion or buoyancy of the gas, or other causes, the injection of small amounts of iodinated contrast can be used

to complete the examination. The reduced volumes of iodinated contrast used will reduce the risk of the procedure, particularly in renal failure patients.

Surgeons at our institution retrospectively studied 128 CO₂ arteriograms in patients whose lesions were verified either at surgery or at the time of balloon angioplasty (5). Most of the patients had concomitant medical illnesses that greatly increased the risk of standard angiography. In 70 patients, the serum creatinine was greater than 1.5 mg/dL. In 91% of cases, the arteriograms were of good to excellent quality. There was diagnostic agreement between the CO₂ and standard contrast angiography in 95% of the cases. The intraoperative and angiographic findings confirmed the correct diagnosis made by CO₂ angiography in 92% of cases. Diagnostic inaccuracies occurred primarily below the trifurcation, mostly in cases where stacking was not used or when the extremities were not elevated.

There was no increase in serum creatinine following CO₂ angiography in any of the patients with renal insufficiency or recent renal transplantation. The results were equally as good in additional studies evaluating reimplanted renal arteries (2) (Fig. 7.5.9).

Detection of Gastrointestinal Bleeding

Recently, the detection of arterial bleeding has become a very important indication for CO₂ angiography. In our experience, CO₂ angiography has allowed the detection of bleeding sites in cases where iodinated contrast medium has failed to demonstrate it, or the bleeding site was much better imaged with the CO₂ than with iodinated contrast (Fig. 7.5.10).

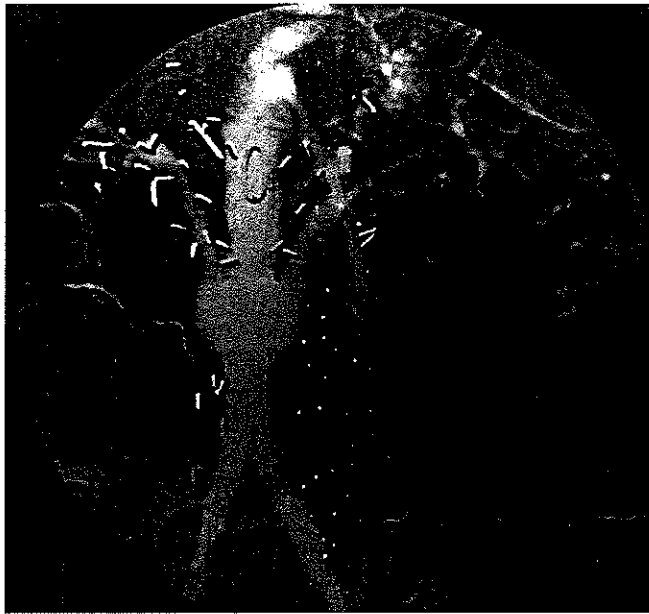


Figure 7.5.9. Good demonstration of bilateral reimplanted renal arteries (140 mL/sec for total of 70 mL).

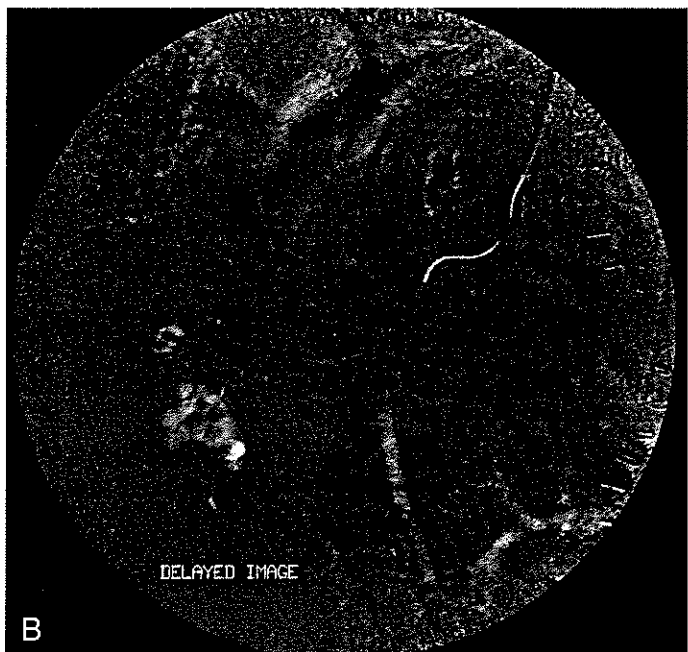
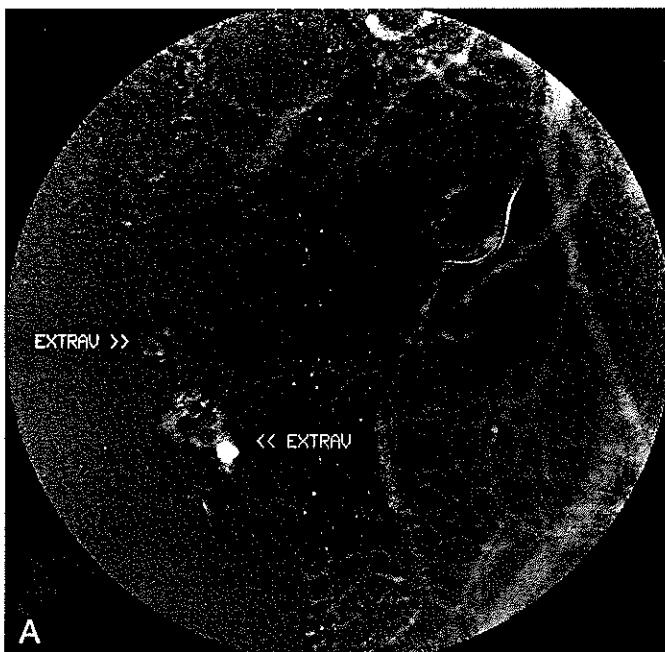


Figure 7.5.10. Detection of GI bleeding. **A.** A 4 Fr shepherd's crook catheter was advanced into the right colic artery; 20 mL of CO₂ injected by hand demonstrated immediate extravasation of CO₂ into the fluid-filled

right colon. **B.** The CO₂ gas that is compressed in the artery, expands approximately four times, making the bleeding site easily detectable.

Hiramatsu presented 42 patients with bleeding in various sites (kidney, pelvis, gastrointestinal tract) in whom CO₂ angiography dramatically demonstrated the bleeding site (22). In the examination of these patients with hemorrhage, CO₂ angiography detected the bleeding site in 15 cases in which the bleeding had not been detected with iodinated contrast. It has been postulated that CO₂ is more sensitive than iodinated contrast because (a) its low viscosity allows CO₂ to flow

easily through the arterial rent, (b) the gas that is compressed in the artery expands 3–4 times at the bleeding site level, and (c) the CO₂ is not diluted by blood at the bleeding site.

Carbon Dioxide for Transjugular Intrahepatic Portosystemic Shunt

Several years ago, we used CO₂ in place of iodinated contrast medium for percutaneous cholangiography. However, when CO₂ was injected into the liver parenchyma with a 22-gauge needle, the portal vein frequently would opacify with CO₂. We and others have used the same principle to demonstrate the portal vein with a CO₂ wedged hepatic venogram (8). As little as 20 mL injected forcefully into a wedged position results in visualization of the portal vein in over 90% of the cases (Fig. 7.5.11). Injections are made in several projections to accurately localize the portal vein. The low viscosity of the gas allows injection of CO₂ via a high-pressure Touhy-Bourst adaptor fitted around the guide wire and the needle with two one-way check valves, to opacify the portal vein (Fig. 7.5.12). If the needle and guide wire have entered a potentially dangerous area (extrahepatic portal vein, hepatic artery, or bile duct) (Fig. 7.5.13), the needle is simply retracted and another pass is made. This eliminates the risk of placing a large catheter into a potentially dangerous area.

The CO₂ can be quickly loaded and injected for the wedge hepatic venogram, between the needle and the guide wire for direct portography both pre- and post-stent placement (Fig. 7.5.14). Since the patient is not positioned in the left lateral decubitus, we prefer to deliver only 20 mL per injection; the injection of less than 50 mL in the portal vein does not provide good visualization.

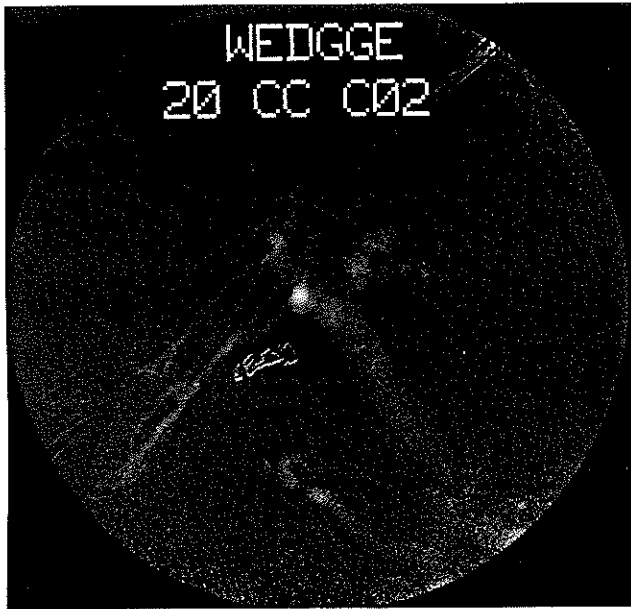


Figure 7.5.11. CO₂ portogram. A 12 Fr catheter is wedged into a distal right hepatic vein, and a forceful injection of 20 mL of CO₂ demonstrates the entire portal system.

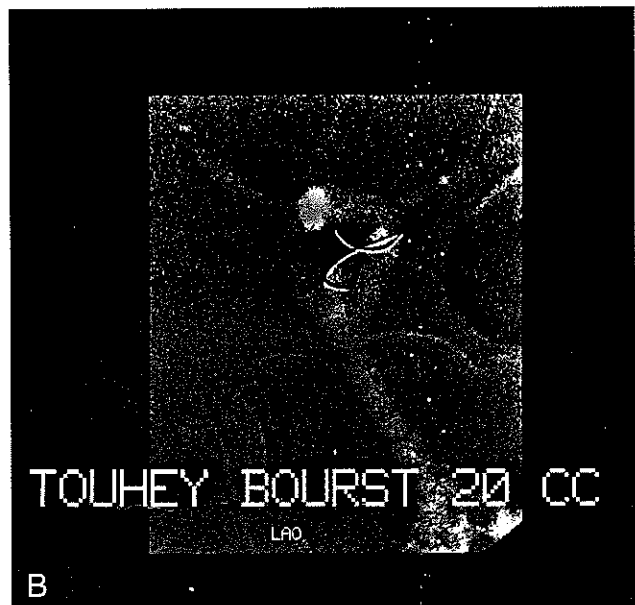
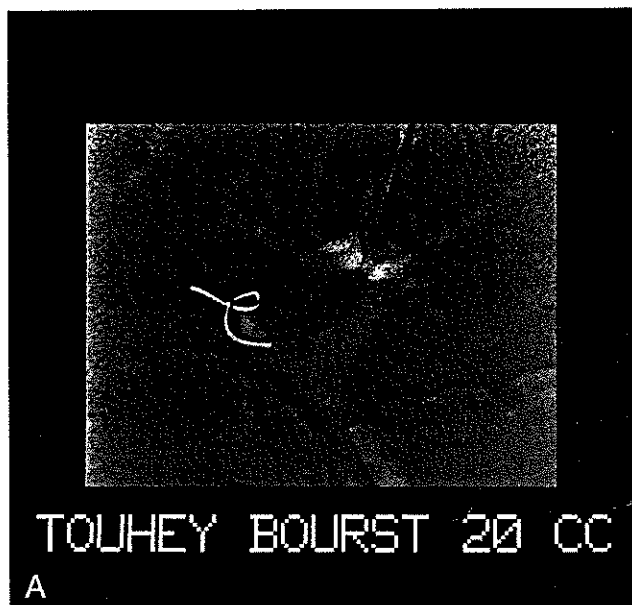


Figure 7.5.12. Portal vein CO₂ injection with Touhey-Bourst fitting. A. Anteroposterior projection after injecting 20 mL, demonstrating the point of entry into the left portal vein just distal to the bifurcation. B. Right an-

terior oblique projection shows the posterior entry of the needle and the guide wire into the left portal vein.

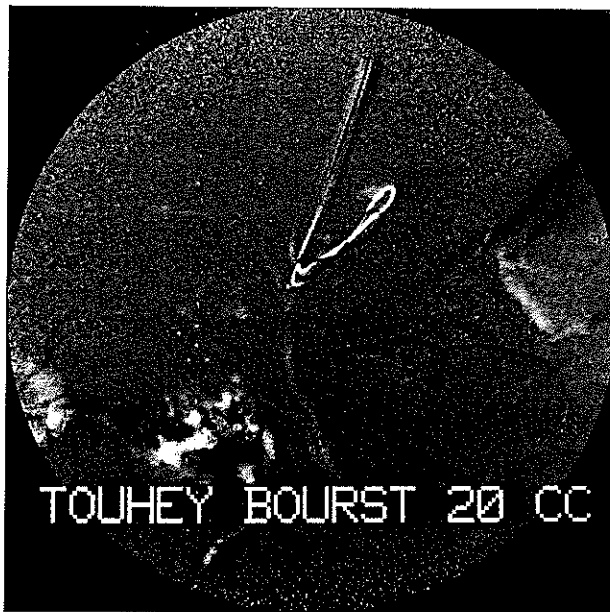


Figure 7.5.13. Fluoroscopy had suggested that the 0.016-inch platinum tip guide wire had entered the left portal vein; however, injection of 20 mL between the needle and the guide wire demonstrates the biliary tree. The guide wire and needle were retracted, and additional passes were made to successfully enter the portal vein.

RENAL TOXICITY

CO₂ has no impact whatsoever on renal function if the injection is made distal to the renal arteries for pelvic and runoff angiography. In venous studies, the kidneys are never exposed to CO₂, since it is eliminated in a single pass by the buffer system and the lungs. During abdominal aortography, the posteriorly located kidneys are exposed to only a small amount of the buoyant CO₂.

We have performed a large number of selective injections in patients with renal failure or transplanted kidneys without a significant increase in serum creatinine. We performed a controlled animal study, injecting large amounts of CO₂ selectively in canines (23). The kidneys were studied pre- and post-CO₂ injections with nuclear medicine imaging ([¹³¹I]orthoiodohippurate and [^{99m}Tc]dimercatosuccinic acid [DMSA]). Both light transmission and scanning electron microscopy were performed on the kidneys 72 hours after injection of CO₂. Initially, there was an overall mean decrease in blood flow of 6% immediately after CO₂ injection; however, this returned to baseline levels in 24 hours.

Histologic examination revealed no changes in the vascular endothelium in the animal cases. However, in one dog in which very large volumes of CO₂ were injected with the kidney in nondependent position, there was minimal histologic evidence of acute tubular necrosis (Fig. 7.5.15).

Since injections were performed every 2 minutes, we feel that there was insufficient time for the trapped CO₂ to dissolve, resulting in ischemic changes. In transplanted kidneys that are positioned anterior to the iliac artery (CO₂ in-

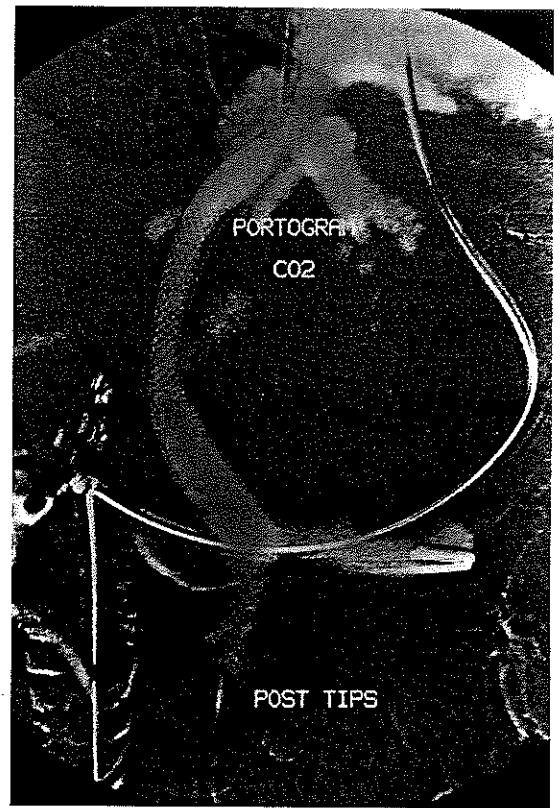


Figure 7.5.14. CO₂ portogram obtained after the stent had been placed in the tract.

jection site), we recommend waiting 3–5 minutes between injections to allow the CO₂ to dissolve.

NEUROTOXICITY

We feel strongly that CO₂ should not be used above the diaphragm or in any situation where reflux could occur into the cerebral circulation. Experimentally, we have injected large amounts of CO₂ into the ascending aorta and carotid arteries of dogs without any ill-effects whatsoever (3). A small amount of air in the same dog always resulted in the animal's demise. Shifrin et al. also experienced no histologic or neurologic deficit in a canine study (24). Our experience with rats, unfortunately, resulted in death or stroke (25). However, this may have been secondary to the use of very large volumes of CO₂ injected in an explosive manner. The rat experience prompted a controlled study of canines in the prone position, which we felt would expose the spinal cord to large volumes of CO₂. No evidence of neurologic injury occurred.

Currently, we will not inject CO₂ into any artery or vein where CO₂ could reflux into the cerebral circulation until CO₂ is proven to be absolutely safe in primates. We would also discourage its use in dialysis shunts if an explosive delivery is used, since CO₂ can reflux into the cerebral circulation. Also, buoyancy becomes an important factor, since CO₂ can flow countercurrent if the head is higher than the injection site.

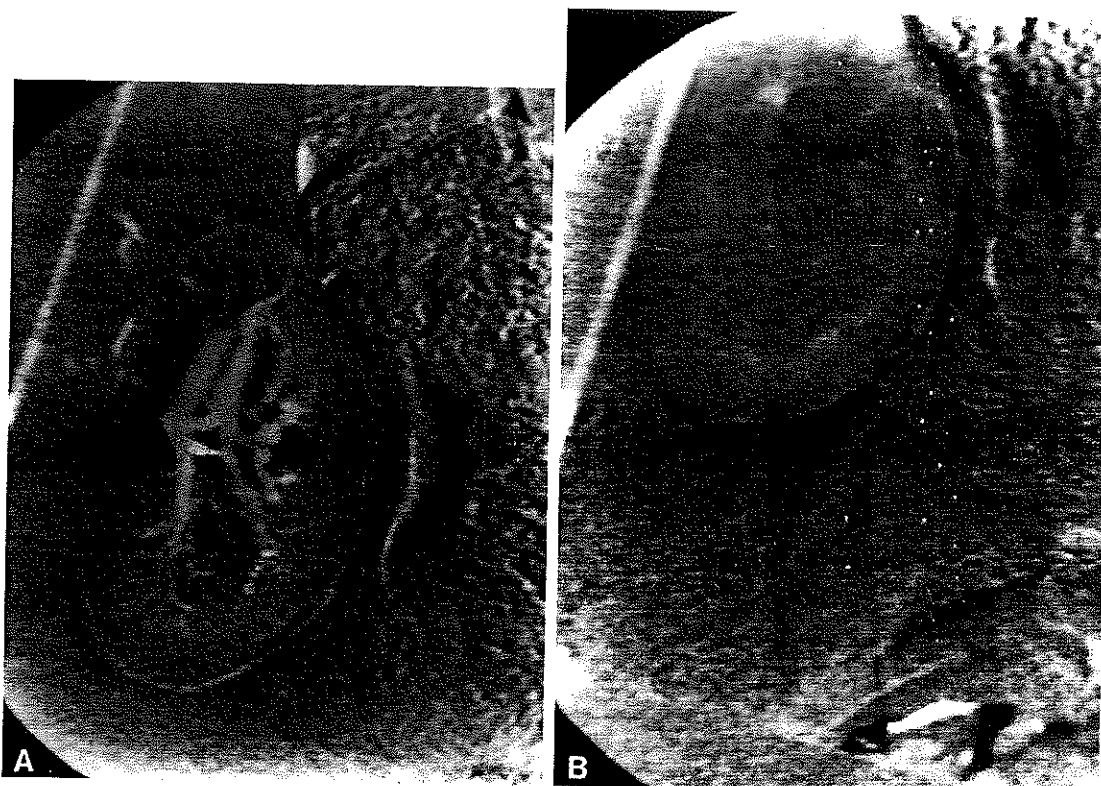


Figure 7.5.15. Large-volume CO₂ injection in a canine kidney. **A.** Arterial phase with the kidney positioned higher than the injection site. **B.** Note: cortical medullary junction. A cortical phase is rarely seen; however, with the kidney in a nondependent position, the capillary filling is

markedly improved. At autopsy, minimal acute tubular necrosis was noted. This is the only animal that sustained any histologic injury. The damage is probably explained by large volumes of CO₂ injected every 2 minutes over a 1-hour period.

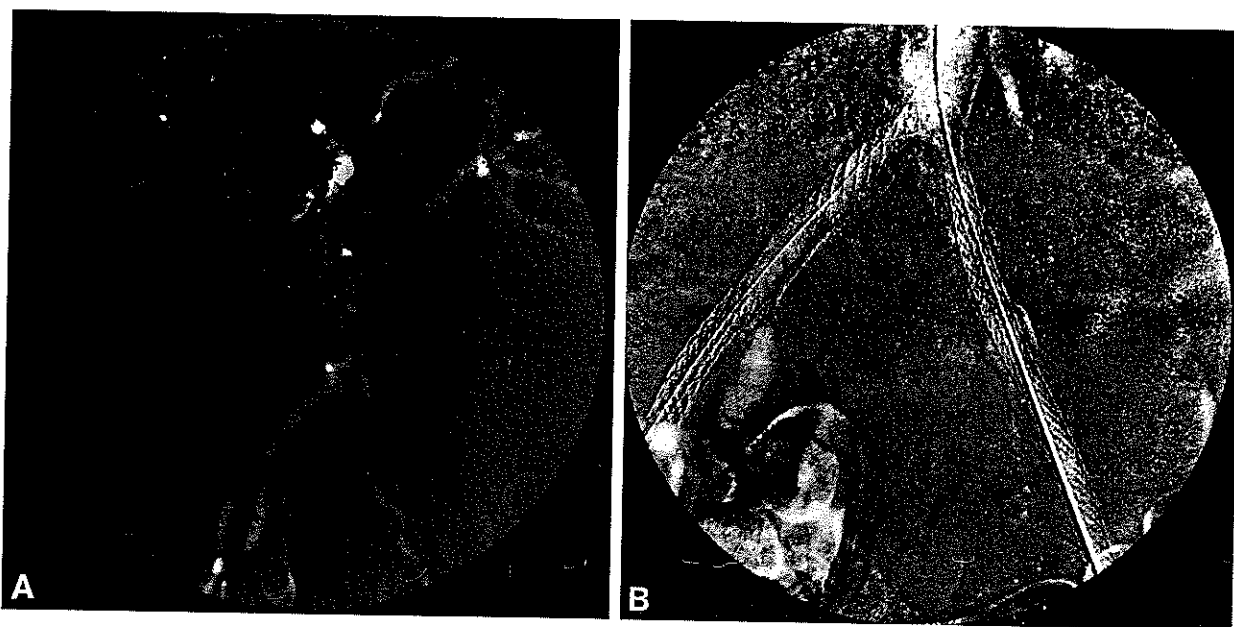


Figure 7.5.16. Angioplasty and iliac stent placement done completely with CO₂ imaging. **A.** CO₂ aortogram demonstrates 20% stenosis of the left renal artery, long segmental irregular stenosis of the left common iliac

artery, and multiple areas of focal stenosis of the right internal and external iliac arteries. **B.** Post-stent placement, showing patency of both iliac arteries. This procedure was performed totally with CO₂.