

CO₂ Digital Angiography: A Safer Contrast Agent for Renal Vascular Imaging?

Irvin F. Hawkins, Jr, MD, Christopher S. Wilcox, MD, PhD, Scott R. Kerns, MD,
and Frank W. Sabatelli, MD

● Although the new nonionic contrast agents are safer than ionic agents, renal insufficiency and even death still occur occasionally. Therefore, we have explored the use of carbon dioxide (CO₂) as an alternative angiographic contrast agent used in combination with digital subtraction angiography. Clinical observations have been made in over 800 patients. The images obtained are of equivalent diagnostic quality compared with those using conventional iodinated contrast agents. Recent advances in imaging, including "stacking," provide images comparable with iodinated contrast. Very small vessels, equivalent to third-order branches of the renal artery, can be imaged satisfactorily with CO₂. Occasional studies with CO₂ yield information not apparent with iodinated contrast agents, including excellent visualization of arteriovenous shunts, collateral circulations, malignant tumors, and minute amounts of arterial bleeding. Many of the advantages and disadvantages of CO₂ derive from its special physical and chemical properties. The advantages include no allergic potentiation and no renal metabolism of CO₂, because CO₂ is cleared by the lungs and does not recirculate. Other advantages include delivery by very small catheters because of the low viscosity of CO₂, minimal discomfort on injection, and very low cost. However, the low-density and compressibility of CO₂ poses some special problems. Imaging requires digital subtraction angiography with electronic enhancement and injections require an experienced investigator and, ideally, a dedicated CO₂ injector. The dedicated CO₂ injector provides calculated, controlled dosing and rates for injection, while excluding the possibility of air contamination. The buoyancy of CO₂ inhibits good filling of dependent vessels. Accordingly, CO₂ does not normally produce good nephrographic images, although proximal renal arteries are normally shown clearly. Experimental studies in dogs, whose renal arteries have been injected repeatedly with very large doses of CO₂, demonstrate only transient changes in renal blood flow and no endothelial cell damage. However, these studies also showed clearly that renal ischemia can occur due to a "vapor lock" phenomenon if the kidney is positioned vertically above the injection site, and recurrent injections are given without time for absorption of the arterially delivered CO₂ boluses. Uncontrolled studies in over 800 patients have confirmed that CO₂ likely has a very low renal toxicity. At the University of Florida, CO₂ is the radiologic contrast agent of choice in patients with renal insufficiency, especially those with diabetes mellitus, and in those with pre-existing allergy to iodinated contrast agents. Further controlled clinical studies are required to define the true clinical utility and safety of CO₂ compared with conventional radiologic contrast agents.

© 1994 by the National Kidney Foundation, Inc.

INDEX WORDS: Angiography; nephrotoxicity; renal insufficiency; carbon dioxide; iodinated contrast agent.

CARBON DIOXIDE (CO₂) was first injected retroperitoneally in 1914, to outline the abdominal structures radiographically.¹ The first intravascular use of CO₂ was in the 1950s, for demonstration of pericardial effusion. CO₂ (100 to 200 mL) was injected into an antecubital vein with the patient in the left lateral decubitus position, thereby trapping the CO₂ in the right atrium.²⁻⁴ The pericardial effusion was imaged between the gas density in the right atrium and the gas density of the lung. Before CO₂ was used in patients, it underwent extensive animal testing, using both intravenous and arterial routes of administration.^{5,6} Even with massive intravascular injections, only minimal and transient changes in arterial blood gas composition were observed. Very large volumes could be injected repeatedly and indefinitely in dogs, if time were allowed be-

tween injections for the CO₂ to be eliminated by the lungs.

We initially used CO₂ as an arterial contrast agent in 1971, using a cut-film subtraction technique. The CO₂ was delivered with a hand syringe. It produced diagnostic images both in the kidney and in the extremities. However, the pho-

From the Division of Angio/Interventional Radiology, the Division of Nephrology, Hypertension, and Transplantation, and the Hypertension Center, University of Florida College of Medicine, Gainesville, FL.

Address reprint requests to Irvin F. Hawkins Jr, MD, Department of Radiology, University of Florida College of Medicine, PO Box 100374, JHMHC, Gainesville, FL 32610-0374.

© 1994 by the National Kidney Foundation, Inc.

0272-6386/94/2404-0023\$3.00/0

tographic subtraction techniques were time-consuming and, in general, produced suboptimal images.

With the advent of digital subtraction angiography (DSA) in 1980, this "low-density contrast agent" became more readily imaged.⁷

PRINCIPLES OF IMAGING WITH CO₂ AND LIQUID CONTRAST AGENTS

In general, the final images that can be obtained with CO₂ DSA are almost identical to those obtained with iodinated contrast. However, the physical properties of the gas are quite different from those of liquid contrast.

Iodinated contrast injected into the vascular system mixes with blood, and is excreted quantitatively over time in the glomerular filtrate. The high atomic number of the iodine atoms inhibit passage of the x-ray beam and produce a "shadow" on the x-ray film. The density of the image is improved by either injecting more iodine (ie, injecting at a higher rate and volume) or increasing the concentration of the iodine in the contrast media. Both of these maneuvers will increase the total dose of the contrast agent administered and will therefore increase the incidence of toxic effects.

The principles of vascular imaging with CO₂ are quite different from those of conventional liquid contrast. Vessels are imaged with CO₂ by totally displacing the blood from the lumen of the vessel. This allows more x-rays to penetrate the vessel, since the density of the gas is lower than that of the surrounding soft tissues. If the blood is totally replaced with CO₂, the addition of more CO₂ will not improve the image. Since there is only a minimal difference in attenuation of the x-ray beam between the gas-filled vessel and the surrounding soft tissue, this density differential must be enhanced using DSA. This ef-

fectively subtracts out the images caused by the bone and soft tissue, leaving only the CO₂ image, which can be further enhanced electronically. Sophisticated software is now available that permits not only electronic enhancement of the contrast agent, but also allows "stacking" of multiple images when only one segment of the vessel is filled.⁸ This produces a single composite image in which the entire artery is visualized. The stacking

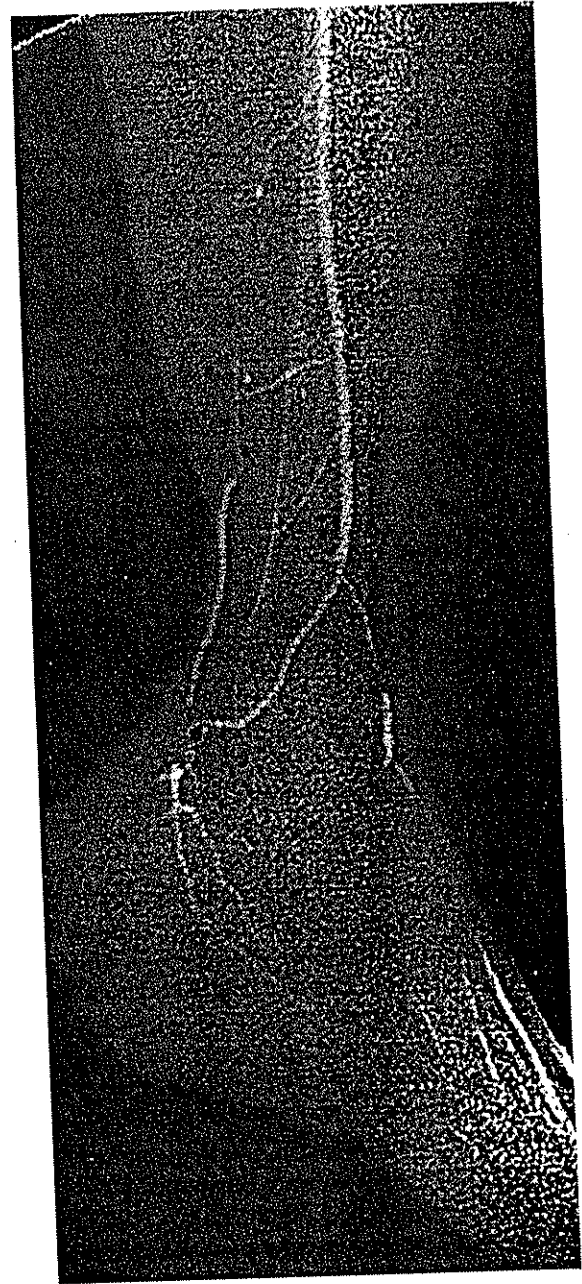


Fig 1. Lower extremity CO₂ arteriogram demonstrating severe atherosclerotic disease with only one vessel run-off (peroneal artery collaterally filling dorsal pedis and lateral and medial plantar arteries). Twenty images were summated (stacked) as small amounts of CO₂ delivered with a 3-Fr catheter positioned in the common femoral artery passed distally through multiple collateral vessels. This composite image correlated with intraoperative findings.

technique permits injection of a smaller volume of CO₂, which traverses the artery as a single large bubble. Since its passage conforms to the interior of the vessel, if multiple images are obtained at a rapid rate, images of this single "bubble," which has displaced the blood, can be assembled to produce a single diagnostic image (Fig 1). This is not possible with iodinated contrast, which simply mixes with blood and is diluted by it.

It is clear from this analysis that the techniques needed to image CO₂ are considerably more stringent than those for iodinated contrast. Digital subtraction angiography requires the patient to be absolutely motionless. Peristaltic bowel gas motion also will degrade the image.

CO₂ images that are comparable to iodinated contrast can be obtained only if (1) high-resolution DSA x-ray equipment is available, (2) no motion occurs, and (3) the blood is completely displaced from the vessel.

PHYSICAL AND CHEMICAL PROPERTIES OF CO₂ THAT ARE RELEVANT TO ITS USE IN ANGIOGRAPHY

The gaseous properties of CO₂ provides a unique contrast agent whose most prominent advantages and disadvantages are summarized in Table 1. These must be thoroughly understood to permit consistent, safe delivery and for correct interpretation of the images.

Low Viscosity

There are several consequences of the extremely low viscosity of CO₂ that are relevant to its use as an imaging agent. First, it permits the delivery of CO₂ via very small catheters (as small as 1.5 Fr), which greatly reduces the risk of procedural complications. Second, the low viscosity allows CO₂ to flow from the artery to the vein without apparent blockage of the capillary bed. We have demonstrated that when large volumes of CO₂ are injected into the aorta of a dog, the CO₂ returns to the inferior vena cava and right heart, and disappears from the pulmonary arteries within a few seconds. Since the lungs eliminate the CO₂ in a single pass, if small volumes are injected (<200 mL/s) and if time is allowed between the injections, CO₂ can be injected in un-

Table 1. Special Properties of Carbon Dioxide Relevant to Its Use in Angiography

Special Property	Consequence
Low viscosity	Only small catheter required for delivery AV shunting seen in malignant tumors with CO ₂ Shunting of agent through AV fistulae Improved visualization of vascular tumors Detection of minute degrees of arterial bleeding Better collateral filling
Buoyancy	Selective filling of nondependent vessels May fail to fill dependent vessels Entrapment of CO ₂ in elevated organs
High solubility	Rapid disappearance from arterial tree
Compressibility	Difficulty in providing controlled injection
Pulmonary clearance	No recirculation Limited exposure of kidney to agent even with direct intra-arterial injection

NOTE. This table provides a summary of the major special physical and chemical properties of CO₂ and their consequences for its use as an angiographic agent. For further discussion, see text.

limited volumes. However, it is very important to stress that if a single very large bolus of CO₂ is injected inadvertently, the CO₂ can displace the blood from the right heart, resulting in a "vapor lock" phenomenon and death. Finally, the low viscosity apparently permits detection of arteriovenous (AV) shunting of the agent through tumors,^{8,9} better collateral filling,⁸ and detection of minute amounts of arterial bleeding, which may not be imaged with the more viscous liquid contrast. We have injected CO₂ selectively in over 20 malignant hypernephromas. The majority demonstrated immediate AV shunting with good opacification of the inferior vena cava, which was not seen with iodinated contrast.

Buoyancy

The buoyancy of CO₂ results in selective filling of nondependent portions of the vascular bed.

For accurate imaging, the blood should be either totally displaced from the vessel or the region of interest placed above the injection site. With the patient lying supine, nondependent branches of the abdominal aorta, such as the celiac axis, superior mesenteric artery, and inferior mesenteric artery, always fill, even with injections of very small amounts of CO₂. In contrast, the lumbar arteries are very difficult to fill since they are more posterior. The origins of the renal arteries usually fill well; however, the more distally renal arteries are more difficult to fill since they are posteriorly located and are below the injection site.

The buoyancy properties of CO₂ can be illustrated by the analogy of injecting helium into a hollow tree. If the tree is in the normal upright position, the helium will float into all its branches. If it is inverted, it will be very difficult to fill the distal branches and if the tree is lying on its side, only the nondependent half of the tree will fill.

The buoyancy properties may explain why the left renal artery occasionally is not seen. This is secondary to the counterclockwise rotation of the aorta that can occur in older patients, which results in a more posterior location of the origin of the left renal artery. This problem can be overcome by rotating the patient in the opposite direction (lateral decubitus position or a semiprone position). The renal artery is then nondependent and will fill readily. It can be imaged by cross-table orientation of the x-ray beam even with a very small amount of CO₂.

Buoyancy also can be a disadvantage if the vector of forces of the buoyancy exceeds the kinetic energy of the venous flow in any end-arterial type organ, such as the kidney, bowel, or elevated lower extremity. This can lead to entrapment of CO₂ in the vascular space of the organ. If repeated injections are made at frequent intervals, there is potential for a "vapor lock," leading to organ ischemia. This phenomenon is unusual because of the high solubility of CO₂ in blood (20 times that of oxygen in blood), which implies that, if the CO₂ did block capillaries, the ischemia should be very short-lived since the CO₂ should dissolve very rapidly. In practice, the injection of CO₂ in areas where it can potentially become trapped should cause only transient isch-

emia, providing due time is allowed between successive CO₂ injections.

Invisibility and Compressibility

The invisible and compressible nature of CO₂ poses unique problems for its reliable and safe delivery into the vascular system. Medical grade CO₂ is available in a highly pure form in high pressure CO₂ cylinders. Most portable cylinders contain over 3 million mL of the gas at atmospheric pressure. Gas is transferred from the high pressure cylinder via a gas regulator. If the regulator malfunctions, an excessive volume of the CO₂ may be loaded into a hand-held syringe or an angiographic injector's cylinder. There is also a danger that CO₂ could be contaminated with room air via loose connecting Luer lock fittings.

A more common problem derives from the ready compressibility of CO₂. When the injection is made with a hand-held syringe or angiographic injector, as the cylinder of the syringe is advanced, the gas will initially be compressed and will not emanate from the tip of the catheter into the vascular system. When the pressure in the syringe exceeds the resistance of the catheter and the arterial pressure, the majority of the gas will be delivered in the last fraction of a second, resulting in an "explosive" type of delivery. Such a high velocity injection will fill the vessels for only a very short time. This problem has led to the requirement for a very high frame rate to image the gas. With standard DSA equipment, this may exceed its capacity to image the vessel. This problem has been reduced by the development of "stacking programs," which summate successive fragments of the CO₂ image to form a composite image (see above).

Clearly, there are problems with reliable and safe delivery of CO₂. Therefore, we have recently developed a device that delivers CO₂ in a controlled, nonexplosive manner. The CO₂ passes through multiple valves, and its passage is monitored by successive pressure sensors. The system is electrocardiogram- and pressure-gated to allow the injection of a higher volume of CO₂ during systole and a lower volume during diastole. This provides a uniform displacement of blood from the vessel. The entire injector system is hermetically sealed to prevent air contamination. It also

incorporates a closed system with a microfilter, which provides sterility of the gas and automatic closed flushing to prevent catheter clotting. This device is not yet commercially available since it is under evaluation by the Food and Drug Agency. However, with practice, CO₂ can be quite reliably delivered by a hand-held syringe or by mechanical injectors, providing care is taken to use a disposable CO₂ cylinder and to guard against severe, explosive-type delivery by moving the syringe cylinder forward at a reduced velocity as the injection terminates, which requires a little practice. This technique has been described previously.^{8,10}

DIAGNOSTIC ACCURACY AND CLINICAL EXPERIENCE OF CO₂ ANGIOGRAPHY

The low-density image of CO₂ is more difficult to image and interpret than iodinated contrast. However, with meticulous technique elevating the area of interest, restraining the patient to prevent motion, and decreasing bowel gas motion with glucagon, diagnostic images can be obtained in more than 90% of the studies. In practice, CO₂ is often selected for high-risk patients, especially those with renal insufficiency. Sometimes even multiple injections of CO₂ do not provide truly diagnostic information. In these circumstances, a single injection of iodinated contrast with DSA or cut film will produce a diagnostic study that has limited the risk of nephrotoxicity by severely curtailing the total dose of iodinated contrast agent used.

CO₂ is most reliable for examination of peripheral vascular disease of the lower extremity, since the images are not degraded by bowel gas motion. Recently, we performed a retrospective study of 128 CO₂ arteriograms obtained from 115 patients.¹¹ Comparison studies with iodinated contrast were available in 98 of these patients. Many patients had concomitant medical illnesses that increases the risk of arteriography. These included renal insufficiency in 70 patients (serum creatinine concentration >1.5 mg/dL), hypertension requiring multiple drugs in 85 patients, diabetes mellitus in 44 patients, severe coronary artery disease in 62 patients, and cerebral vascular disease in 27 patients. In this series, 47 abdominal arteriograms were performed for abdominal

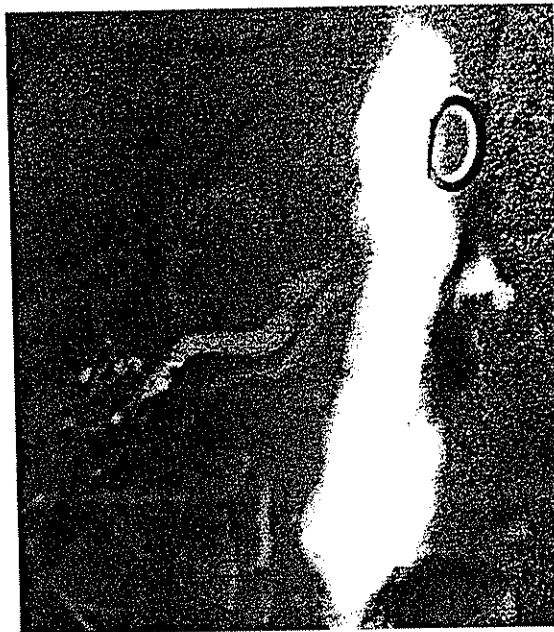

Fig 2. Abdominal CO₂ aortogram demonstrating severe stenosis of a superior right renal artery. Note preferential filming of the right renal artery since the right side of the patient was elevated.

aneurysmal disease, renal artery stenosis (Fig 2), or mesenteric ischemia. Most patients also had an extremity study. The CO₂ arteriograms were rated to be of good or excellent quality in 117 cases (91%). There was diagnostic agreement between the CO₂ and standard contrast studies in 95% of the cases. Subsequent operative findings confirmed the correct diagnosis in 92% of the cases with CO₂. The diagnostic insufficiencies were due to inadequate visualization of the infrapopliteal arteries in seven cases. Although 80 patients presented with renal insufficiency and five with recent renal transplantation, no increase in serum creatinine concentration was detected in any patient in whom only CO₂ was used. Contrast-induced nephrotoxicity was noted in one case in which both CO₂ and iodinated contrast were used together.

Equally good results were found in a second study of high-risk patients. This group had renal artery stenosis and required reimplantation of their renal arteries to address poorly controlled hypertension or deteriorating renal function.¹² All



Fig 3. Reimplanted left renal artery. The anastomosis is widely patent. However, note poor filling of distal vessels secondary to the overlying bowel gas and buoyancy of the CO_2 .

the CO_2 arteriograms were considered diagnostic (Fig 3). There were no complications detected in this study, and the serum creatinine concentration remained stable after the CO_2 arteriograms in these patients.

Preliminary data are also available for 15 patients with renal transplants who were studied with CO_2 angiograms. Again, there was good visualization of the renal arteries, including second- and third-order branches (Fig 4). No elevation in serum creatinine concentration or other complications were detected during follow-up. It is important to stress that these observations were not blinded, controlled studies. Therefore, some minor adverse effects of CO_2 may have escaped detection.

Because of the low density of CO_2 and the nondependent position of the normally oriented kidneys, a nephrogram is not usually visualized. However, the proximal renal artery and up to the third-order branches are usually well seen. Unfortunately, accurate and interlobular arteries are not well imaged because they are usually obscured by overlying bowel gas and minor degrees of motion in the majority of patients. In patients with suspected small vessel disease, such as arteritis, CO_2 can be used to rule out aortic abnormalities and main renal artery stenosis. However, standard cut films and iodinated con-

trast are recommended to image small vessels. By combining techniques, a diagnostic study can be obtained with as little as 10 mL of nonionic contrast.

The ability to use CO_2 in unlimited quantities makes it ideal for complicated interventional procedures, especially in patients with renal insufficiency. We have performed several angioplasties, including two cases of renal artery stenosis, solely with CO_2 .

RENAL TOXICITY OF CO_2 ANGIOGRAPHY

When CO_2 is used for run-off and extremity studies, the injection is made distal to the renal arteries. Therefore, there is no impact whatsoever on renal function, since the CO_2 is eliminated by the lungs in a single pass. Even CO_2 aortography provides only a small CO_2 load to the kidney, since the buoyancy of CO_2 inhibits good filling of the distally and posteriorly placed renal arteries. Indeed, a nephrogram is not usually seen during supine aortography. The experience of the follow-up of patients after CO_2 angiography at our institution encourages us to anticipate a low prevalence of post- CO_2 renal insufficiency. Moreover, we now have clinical experience in over

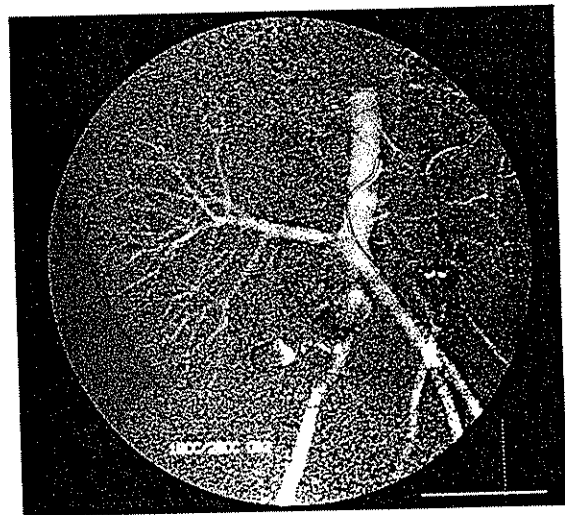


Fig 4. Transplanted kidney showing good filling of peripheral arteries secondary to the more anterior location of the transplanted kidney. Since there may be increased "trapping" in transplanted kidneys, approximately 5 minutes should be allowed between injections to permit reabsorption of the CO_2 .

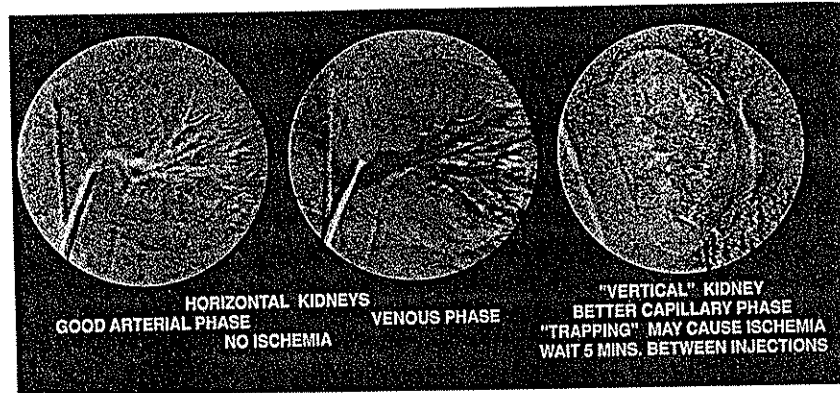


Fig 5. Canine CO₂ renal arteriogram with good arterial and venous phase. Vertically oriented kidney demonstrating parenchymal phase, including cortical medullary junction.

800 patients who have had CO₂ angiography.^{7,8,10-12} We have seen no evidence of clinically significant renal insufficiency that could be attributed to CO₂ injection. Moreover, other centers have not reported renal toxicity secondary to CO₂ angiography.¹³⁻¹⁵

However, these studies of the effects of CO₂ on renal function in patients were not rigorous. Therefore, to assess the renal toxicity of selective intra-arterial CO₂ injections, we undertook a renal toxicity study in which large volumes of CO₂ were injected directly into the renal arteries of 12 dogs.¹⁶ The contralateral kidney was used as a control. Nuclear medicine studies with [¹³¹I]orthiodohippurate (hippuran) and [^{99m}Tc] dimercaptosuccinic acid (DMSA) were performed before, immediately after, and 24 hours after CO₂ was injected. Light transmission and scanning electron microscopy of the kidneys were performed at autopsy 72 hours after the injection of CO₂. Overall, we detected a mean decrease in renal blood flow of 6% immediately after the CO₂ was injected, but no change from baseline by 24 hours. Histologic examination of the renal arterial and capillary endothelium with scanning electron microscopy revealed no changes in any dog. However, changes of acute tubular necrosis were seen in one of the kidneys, and minimal ischemic changes were seen in the parenchyma of two kidneys. All these kidneys were vertically oriented (Fig 5). Indeed, the animal that developed acute tubular necrosis had an especially good-quality nephrogram, because the CO₂ may have been trapped in the kidney. This study was

designed to subject the kidneys to a very large CO₂ dose. The CO₂ was injected repeatedly every 2 minutes, which could lead to a prolonged "vapor lock" phenomenon, preventing blood flow. However, if time is allowed between injections (as is routine clinical practice), the high solubility of the CO₂ should result in only transient renal ischemia. This theory is supported by the preliminary result of an ultrasound study in patients in which the kidney was imaged after injection of CO₂. If the kidney was horizontal, the CO₂ bubbles cleared in approximately 30 seconds. However, if the kidney was vertical, approximately 2 minutes were required to clear CO₂ from the renal cortex (unpublished observations). We conclude from this experience that intrarenal arterial injection of CO₂ appears to be quite safe, providing that time is allowed to clear CO₂ from the circulation between injections. In practice, the patient's position should be changed, or 2 to 5 minutes should elapse between injection to ensure that CO₂ does not get trapped in the kidneys, leading to ischemia.

NEUROTOXICITY

At the University of Florida, we do not use CO₂ in arterial studies above the diaphragm, since a preliminary study in rats suggested that CO₂ may be neurotoxic.¹⁷ We have, however, used CO₂ in the cerebral circulation in over 10 canines without any untoward reactions.¹⁰ Shifrin et al¹⁸ have reported similar results in canines and report absence of untoward reaction in patients.

However, until CO₂ studies are available in primates, we hold that CO₂ is clearly contraindicated in any situation in which the cerebral circulation could be exposed. The report of neurotoxicity in the rat also raises concern about spinal cord toxicity. To explore this possibility, we injected large volumes of CO₂ into the aorta of 10 dogs in the prone position. No neurologic deficit was noted. However, we continue to be reluctant to use CO₂ in the prone position, where it may percolate into spinal arteries, until it has been tested systematically in primates.

RESPIRATORY COMPLICATIONS OF CO₂ ANGIOGRAPHY

Intuitively, it seems that repeated injections of CO₂ should not be used in patients with severe pulmonary compromise. However, we have undertaken CO₂ angiography in 10 patients with severe respiratory failure and have not detected any obvious increase in arterial blood P_{CO₂} levels after the studies. However, these patients who are acidotic with elevated P_{CO₂} values require monitoring of arterial blood gases. In practice, the volume of CO₂ injected is quite small compared with the rates of endogenous CO₂ production.

DISCOMFORT

The vast majority of patients experience no, or minimal, sensation during CO₂ injection with a controlled, dedicated device. With the more explosive delivery from a hand-held syringe, the injection of large amounts of CO₂ can give discomfort similar to that provided by injection of nonionic contrast agents. With the new stacking programs, only very small amounts of CO₂ need to be injected; this usually results in no sensation whatsoever.

OTHER COMPLICATIONS OF CO₂ ANGIOGRAPHY

We have experienced only one significant complication that was attributed to CO₂. This was a patient who developed severe diarrhea after receiving over 2,000 mL of CO₂ injected into a large abdominal aneurysm over a short time. The inferior mesenteric artery arose from this aneurysm, resulting in continual exposure to CO₂

Table 2. Summary of Relative Advantages and Disadvantages of CO₂ Compared With Conventional Iodinated Contrast Renal Angiography

Advantages of CO ₂	
Low cost	
Low viscosity reduces the catheter size requirements	
Apparent absence of nephrotoxicity if "vapor lock" phenomenon is prevented	
No contraindication in patients with iodine allergy	
No recirculation allowing unlimited quantities to be injected	
Enhanced visualization of AV anastomoses and malformations, certain vascular tumors, or bleeding sites	
Minimal discomfort	
Disadvantages of CO ₂	
Inadequate diagnostic visualization in a small percentage of studies	
Potential for "vapor lock" ischemia, if repeated rapid injections are given and the patient is not properly positioned	
Can fail to image dependent renal arteries if the patient is not repositioned	
Distal renal arteries are difficult to image	
It produces a poor nephrogram	
Requires sophisticated DSA programming and preferably a dedicated injector	
May prolong procedure time	
Potential, unexplored danger of neurotoxicity	
Potential danger of air embolization if CO ₂ system is not hermetically sealed	
True benefits and toxicity yet to be rigorously evaluated in blinded, controlled trials	
Presently investigational	

from the trapped gas in the aneurysm. Apparently, the CO₂ that was trapped in the aneurysm, producing a "vapor lock" phenomenon, resulted in mesenteric ischemia. Endoscopy demonstrated the appearance of ischemic colitis. Fortunately, the diarrhea abated after 6 hours and endoscopy 3 days later was normal. We believe that this is the same mechanism that produced ischemia, in kidneys positioned vertically, in the canine study.¹⁶

CONCLUSION AND CURRENT RECOMMENDATIONS

In the past, the use of CO₂ has been extremely helpful in providing diagnostic studies in patients at high risk for nephrotoxicity because of renal insufficiency, as well as in those who have had a prior severe iodinated contrast reaction. CO₂

occasionally provides additional information that could not be obtained with iodinated contrast such as visualizing collateral circulation, demonstrating AV shunting in malignant tumors, and detecting minute amounts of arterial bleeding. Occasional, vascular malignant tumors can be detected with CO₂ that appear totally avascular with iodinated contrast. Also in the past, the delivery and imaging of CO₂ has been very demanding, time-consuming, and clearly not as reliable as iodinated contrast agents. With the development of more sophisticated programs for DSA and a user-friendly delivery system, as well as the use of tilt tables, the studies have become much more reliable and safer for the patient. Table 2 presents a summary of the relative advantages and disadvantages of CO₂ compared with conventional iodinated contrast renal angiography.

The diagnostic accuracy is now similar to studies with conventional iodinated contrast. The apparent lack of renal toxicity warrants this additional effort in patients with renal insufficiency. Unfortunately, the automated delivery systems will not be commercially available for at least 1 year. However, CO₂ can be delivered by hand or with an angiographic injector. One must be familiar with the properties of CO₂ and be prepared to obtain multiple views in several positions for accurate imaging. Frequently, CO₂ alone may not provide all the necessary diagnostic information. However, the addition of a small amount of iodinated contrast medium will result in a diagnostic study with a reduced risk of renal toxicity.

It is important to emphasize that much of the information on CO₂ angiography has been obtained either from nonrigorous clinical studies or from more detailed examinations in relatively small numbers of animals. Therefore, a larger trial involving a more systematic and quantitative analysis of the accuracy, applicability, and toxicity of CO₂ compared with conventional contrast angiography is required before the true role of this presently investigational agent can be confidently stated.

ACKNOWLEDGMENT

Irvin F. Hawkins, MD has developed, in conjunction with Angiodynamics Inc (Glens Falls, NY), a CO₂ injector device

for potential commercial application after approval from the Food and Drug Administration. The authors thank our colleagues in the Departments of Radiology, Surgery, and Medicine for help in developing the CO₂ procedure.

REFERENCES

1. Harvard BM, White RR, Walsh JF: Experimental studies in acute retroperitoneal carbon dioxide insufflation. *J Urol* 8:481-485, 1959
2. Paul RE, Durant TM, Oppenheimer MJ, Stauffer HM: Intravenous carbon dioxide for intracardiac gas contrast in the roentgen diagnosis of pericardial effusion and thickening. *AJR Am J Roentgenol* 78:224-225, 1957
3. Turner A, Meyers HI, Jacobson G, Lo W: Carbon dioxide cineangiography in the diagnosis of pericardial disease. *AJR Am J Roentgenol* 97:342-349, 1966
4. Bendib MBT, Toumi M, Boudjellab A: Carboxyangiographie et carboxyangiographie elargi en cardiologie. *Ann Radiol (Paris)* 20:673-686, 1977
5. Moore RM, Braselton CW: Injections of air and carbon dioxide into a pulmonary vein. *Ann Surg* 112:212-218, 1940
6. Oppenheimer MJ, Durant DM, Stauffer H, Stewart GH, Lynch PR, Barrera F: Cardiovascular-respiratory effects and associated changes in blood chemistry. *Am J Physiol* 186:325-334, 1956
7. Hawkins IF: Carbon dioxide digital subtraction arteriography. *AJR Am J Roentgenol* 139:19-24, 1982
8. Hawkins IF, Akins EW, Seeger JM: Carbon dioxide (CO₂) as a contrast for angiography and angioscopy, in Ahn SS, Moore WS (eds): *Endovascular Surgery* (ed 2). Philadelphia, PA, Saunders, 1991, pp 473-480
9. Takeda T, Ido K, Nishimura G, Hashimoto S, Kyo E, Okawa S, Nakatsuka S, Miura H, Kobayashi S, Tanaka T, Hiramatsu K: Intraarterial digital subtraction angiography with carbon dioxide: Superior detectability of arteriovenous shunting. *Cardiovasc Intervent Radiol* 11:101-107, 1988
10. Hawkins IF, Herrera MA: Carbon dioxide has promise as an arterial contrast agent. *Diagn Imag* 7:82-84, 1985
11. Seeger JM, Self S, Harward TR, Flynn TC, Hawkins IF: Carbon dioxide gas as an arterial contrast agent. *Ann Surg* 217:688-698, 1993
12. Harward TR, Smith S, RVT, Hawkins IF, Seeger JM: Follow-up evaluation after renal artery bypass surgery with use of carbon dioxide arteriography and color-flow duplex scanning. *J Vasc Surg* 18:23-30, 1993
13. Miller FJ, Mineau DE, Koehler PR, Nelson JA, Luers PD, Sherry RA, Lawrence FP, Anderson RE, Kruger RA: Clinical intra-arterial digital subtraction imaging: Use of small volumes of iodinated contrast material or carbon dioxide. *Radiology* 148:273-278, 1983
14. Krasny VR, Hollmann JP, Gunther RW: Erste erfah-

rungen mit CO₂ als gasförmiges Kontrastmittel in der DSA. Fortschr Röntgenstr 146:450-454, 1987

15. Weaver FA, Pentecost MJ, Yellin AE, Davis S, Finck E, Teitelbaum G: Clinical applications of carbon dioxide/digital subtraction arteriography. J Vasc Surg 13:266-273, 1991

✓ 16. Hawkins IF Jr, Mladinich CRJ, Storm B, Croker BP, Wilcox CS, Akins EW, Drake W: Short-term effects of selective renal arterial carbon dioxide administration

on the dog kidney. J. Vasc Interv Radiol 5:149-154, 1994

✓ 17. Coffey R, Quisling RG, Mickle JP, Hawkins IF, Ballinger WB: The cerebrovascular effects of intra-arterial CO₂ on quantities required for diagnostic imaging. Radiology 151:405-410, 1984

✓ 18. Shifrin EG, Pflich MB, Verstandig AG, Gomori M: Cerebral angiography with gaseous carbon dioxide CO₂. J Cardiovasc Surg 31:603-606, 1990