

**CARBON DIOXIDE DIGITAL SUBTRACTION ANGIOGRAPHY
VERSUS IODINATED CONTRAST IMAGING**

Irvin F. Hawkins, MD, James G. Caridi, MD, Karl E. Weingarten, MD

Department of Radiology

University of Florida College of Medicine

Gainesville, Florida

Telephone: (352) 395-0291

FAX: (352) 395-0279

During the last two decades, tremendous advances in surgical and percutaneous interventional procedures have demanded more sophisticated imaging of the vascular anatomy. More detailed diagnostic information is required to plan, monitor, and assess the result of the intervention. The recent economic climate is also demanding the performance of more combined diagnostic and therapeutic procedures in an outpatient setting. Although magnetic resonance angiography, intravascular ultrasound, and angiography are promising vascular imaging modalities, they are currently considered investigational. Iodinated contrast angiography continues to be the primary vascular imaging technique. Very large amounts of contrast are frequently required, however, which can limit the extent of the procedure and add to patient risk. Although the nonionic contrast agents significantly reduce adverse reactions, they continue to be associated with renal failure and death. Carbon dioxide (CO₂) gas used as a vascular contrast agent has not been associated with allergy or renal failure. It is particularly applicable for complex outpatient procedures and intervention because it can be safely delivered via very small catheters in very large volumes. Since the physical properties of CO₂ and iodinated contrast are very different, the ability to optimally use both agents coincidentally may provide additional diagnostic information and expand therapeutic options.

HISTORY

Radiologists first used CO₂ in the late 1920s to visualize retroperitoneal structures. In the 1950s, CO₂ was injected intravenously for the detection of pericardial effusion [1-3]. Before CO₂ was used in the vascular system, it had undergone extensive animal testing with no adverse effects. There were only minimal changes in arterial blood gas parameters (PO₂, PCO₂, pH), which were very short lived even when very large volumes of CO₂ were injected [4]. Subsequently, very large volumes of intracardiac CO₂ have been delivered in thousands of patients, without complications [5]. It was also used by thoracic surgeons for gas endarterectomy of the coronary arteries in the late 1960s.

We initially used CO₂ as an arterial contrast agent in 1971 in patients with allergies to standard ionic contrast material. We injected the gas with a hand syringe and imaged it with standard cut-film subtraction techniques. The gas, however, was difficult to deliver, the images were frequently suboptimal, and the subtraction process was time-consuming.

With the advent of digital subtraction angiography (DSA) at our institution in 1980, we found that this low-density contrast agent could be reliably imaged with this technique [6,7]. The indications were then expanded to basically any patient who required standard iodinated contrast material.

To date, we have used CO₂ in 120 laboratory animals and over 1000 patients with rather remarkable results [6,7,8,9]. Others have reported similar findings [10,11,12]. CO₂ microbubbles have safely been used as an ultrasonic vascular contrast agent for over a decade and have more recently be used to detect hepatic tumors with hepatic artery injections [13]. Recently, we have also been using CO₂ to displace blood from the vascular tree for direct angioscopic viewing [14,15]. We have developed a dedicated injector and delivery system to deliver the gas in a controlled manner, without the danger of room air contamination. The DSA equipment has also been improved, and special software for CO₂ has been developed, which now produces images comparable to iodinated contrast. In a small number of cases, CO₂ provides information that cannot easily be obtained with standard iodinated contrast. Arteriovenous shunting is seen in malignant tumors more often with CO₂, tumors that are avascular with iodinated contrast become vascular with CO₂, collateral arteries are better visualized, and recently CO₂ has been used for the improved detection of arterial bleeding [16].

UNIQUE PROPERTIES OF CARBON DIOXIDE

Liquid iodinated contrast mixes with blood and fills the entire vascular tree if delivered properly. The density and quality of the arterial image can be increased by simply increasing the injection rate, or the concentration of the iodinated contrast agent. The artery is imaged with CO₂ by total displacement of blood from the vessel. DSA and electronic enhancement are used to detect the minimal difference in density between the gas and that of the surrounding soft tissue. If the blood is not totally displaced from the artery, the CO₂ "floats" on the blood and produces an image of only the nondependent portion of the artery, which is usually smaller than the artery's maximum diameter (Chart 1). If blood has been totally displaced from the vessel, the injection of more CO₂ does not improve the imaging, but simply refluxes into another area. The image can be improved only by electronic postprocessing enhancement. The density of CO₂ is always considerably less than iodinated contrast material. Electronic enhancement of large and medium-sized vessels produces images of density comparable with iodinated contrast DSA (Figure 11-1), but the parenchymal phase is much less dense than with iodinated contrast.

DO CARBON DIOXIDE BUBBLES BLOCK CAPILLARIES?

Neurotoxicity of air injected into the cerebral circulation has been attributed to gas bubbles blocking the capillaries with resulting ischemia. Because of the high solubility of CO₂ in blood (20 times greater than oxygen), it was thought that if CO₂ did block capillaries, the bubbles would dissolve very quickly and result in only very transient ischemia. We injected large volumes of CO₂ into the abdominal aorta in ten canines. DSA imaging demonstrated appearance of veins (renal, iliac, femoral) at 8 to 10 seconds as well as a very dense inferior vena cava in all the animals (Figure 11-2). Apparently the gas flowed through the capillaries or shunted via precapillary pathways. This phenomenon is important because if excessive volumes of CO₂ are injected over a short period of time, the CO₂ may be returned to the inferior vena cava and the right heart. This may cause "flooding" of the right heart, resulting in the patient's demise. In two animals several thousand centimeters (cc) of CO₂ were injected intra-arterially, within several seconds, which resulted in death. When moderate amounts of CO₂ were injected (up to 800 cc) CO₂ was noted in the heart, main pulmonary artery, and peripheral pulmonary arteries. The CO₂ would disappear with DSA imaging in 3 to 5 seconds. Also, when CO₂ was injected into the inferior vena cava of rats, it completely disappeared from the lungs within 3 to 5 seconds without opacification of the left heart or aorta. These observations suggest that CO₂ in its gaseous form is eliminated from the pulmonary circulation in a single pass. In patients in which smaller volumes are injected, apparently the gas dissolves in the target area, and very little returns to the venous circulation. Because of the solubility and the elimination of the gas by the lungs, if less than 200 cc are injected, per injection, and time is allowed for the CO₂ to be eliminated, unlimited quantities of the gas may be injected. In one animal 3000 to 4000 cc of CO₂ were injected over several hours, without any untoward effects except in the expected transient hyperventilation after each injection.

BUOYANCY OF CARBON DIOXIDE

The extreme buoyancy of CO₂ offers many advantages and disadvantages. The principles can best be explained by using an analogy of attempting to fill a hollow tree with helium (Figure 11-3). If the tree is inverted, it is very difficult to fill the distal branches. If it is lying on its side, the top branches readily fill, and if it is in the upright position, all the branches will fill. In general, the area of interest should always be positioned above (less dependent) the injection site for optimal filling.

When the flow is normal, however, usually the gas is propelled by the arterial flow to the dependant areas. With the patient in the supine position, arteries that are posteriorly located, such as the lumbar arteries, are very difficult to fill except when they provide large high flow collateral channels. Any anteriorly located arteries (i.e., celiac, superior mesenteric and inferior mesenteric arteries) almost always fill quite well, even when very small amounts of CO₂ are delivered. Excellent opacification of the inferior mesenteric artery can be achieved with only 10 cc of CO₂ injected into the aorta. In large abdominal aortic aneurysms, iodinated contrast material is diluted by blood, resulting in poor opacification. The buoyancy of CO₂ always fills the celiac, superior mesenteric, and inferior mesenteric arteries, even with delivery of very small amounts, because CO₂ displaces blood rather than mixing with it. The renal arteries can be visualized better if they are positioned in a less dependent fashion by rotation of the patient. This is particularly important in older patients, in whom the aorta rotates in a counterclockwise direction, placing the left renal artery posteriorly. For example, placing these patients in a right posterior oblique position usually fills the left renal artery. In young patients with good flow, position is not as critical.

For patients with poor flow, elevation of the lower extremity 10 to 20 degrees greatly improves the filling of more distal vessels. The superficial femoral artery slopes downward from its anterior location in the proximal thigh to its posterior location in the distal thigh. The injected gas tends to flow to the higher (less dependent) portion of the superior femoral artery when the patient is supine. Elevation of the leg helps propel the CO₂ down to the knee and calf.

We prospectively compared filling of the popliteal artery with the legs flat and elevated in 30 patients with atherosclerotic vascular disease. The degree of filling was graded from 0 (no filling below the knee) to 3+ (excellent filling). Elevation resulted in an overall improvement of 1.7 (average of 1 in the flat position, which is nondiagnostic, to a diagnostic rating of 2.6 in the elevated position) (Figure 11-4).

Although we believe that CO₂ does not block capillaries, it appears to be trapped in any inverted U-shaped structure (Figure 11-5). If there is good flow in the area, CO₂ should be pushed from the inverted U into the distal circulation. Also because of the solubility of the gas, it usually dissolved within 1 to 2 minutes. Trapping within this portion of the arterial tree should not result in ischemia if time is allowed for dissolution between injections. If the area of interest (e.g., extremity, transplanted kidney, liver, small bowel) is markedly higher (less dependent) than the injection site or if blood flow is markedly limited, CO₂ could be trapped within the entire structure and remain for a significant time. If the buoyant force of the gas is greater than the force of the returning blood flow, trapping can occur. This potential problem can be avoided if the position of the structure is changed after the injection; that is, the organ is inverted or the patient's feet are lowered so the CO₂ is released to return to the inferior vena cava and eliminated by the pulmonary circulation.

VISCOSITY

The very natural low viscosity of CO₂ (1/400 that of iodinated contrast material) permits delivery through very small catheters. We routinely use 3 or 4F catheters, although CO₂ can be delivered through 1.5F catheters and through very small spaces between outer walls of instruments such as guidewires, lasers, atherectomy devices, angioscopes, and the inner wall of guiding catheters.

We believe also that the low viscosity is important in identification of arteriovenous shunting in malignant tumors [7,17] and collateral vessels, and has recently been shown to improve detection of minute amounts of arterial bleeding (Hiramatsu, Paper presented at Annual Meeting of the Western Angiographic and Intervention Society, Kona, Hawaii, 1992).

DELIVERY OF CARBON DIOXIDE

Carbon dioxide has not been widely accepted by radiologists because it is invisible and very difficult to deliver because of its compressibility. In 1971, we delivered it via a 50 cc syringe, which was filled from a medical grade CO₂ cylinder using a standard oxygen regulator and connecting tubing. Air was purged from the syringe by filling it and emptying it multiple times with a three-way stopcock. The syringe was connected to the angiographic catheter, and the CO₂ was pushed through the catheter. DSA imaging was initiated before the injection of CO₂. We attempted to deliver 50 cc of CO₂ gas within 2 to 3 seconds. Because of the compressibility of the gas, the syringe plunger initially moves forward quite easily, but little CO₂ is delivered. Movement of the plunger becomes increasingly difficult, and the entire 50 cc of the gas is delivered in the last half second of the injection, resulting in an "explosive" delivery.

From our experimental work we found that if the catheter is cleared of saline before the delivery of CO₂, the compression is much less and CO₂ is delivered much more uniformly. With two tandem syringes and two three-way stopcocks, CO₂ can be delivered more consistently (Figure 11-6). Just before filming, the CO₂ in the 3 cc syringe is injected, which displaces the saline from the catheter. Because of the compressibility of the gas, approximately 4 seconds is required to displace the saline from a 65 cm 4F catheter. The stopcock is opened to the 50 cc syringe, the CO₂ for imaging can be delivered very easily. After the 3 cc is injected and the stopcock closed, a moderate amount of pressure should be maintained in the 50 cc syringe for approximately 4 seconds to prevent reflux of blood into the catheter. Unfortunately, this technique is awkward because several stopcocks have to be opened and closed during the procedure. These problems have been overcome by a recently developed, commercially available plastic bag delivery system (AngioDynamic, Glens Falls, NY).

In the early 1980s, we also used a standard angiographic liquid injector which was more reliable because the plunger moves at a predetermined rate. Unfortunately, with the mechanical injector the same compressibility principles apply. Presently, with the availability of a computer controlled injector and a plastic bag reservoir system, we would discourage using an angiographic injector because of the danger of air contamination and possibility of delivery excessive volumes if it is used in a closed system (CO₂ cylinder connected to cylinder). The angiographic injector can safely be used as a closed system if it is connected to a plastic bag CO₂ reservoir.

Care must be taken to ensure that the CO₂ cylinder does not contain water or other contaminants. Water can combine with CO₂ to produce carbonic acid, which could then be injected into the patient. Because we have found water and rust in large amounts in several of the reusable CO₂ cylinders, we now insist on using disposable cylinders (Custom Medical Devices, Gainesville, FL).

The use of either hand injection or mechanical angiographic injection is very time-consuming, and unfortunately, the delivery is unreliable. Occasionally, however, excellent images can be obtained. The possibility of air contamination and delivering CO₂ in an uncontrolled manner are the most significant disadvantages of standard hand and mechanical injectors.

COMPUTER CONTROLLED CARBON DIOXIDE INJECTOR

A new dedicated CO₂ angiographic injector for CO₂ has been developed by the University of Florida and AngioDynamics (Glens Falls, NY) (Figure 11-7). The injector is both electrocardiography- and blood pressure-gated to displace blood during the injection. More CO₂ is delivered during systole and less during diastole. Multiple transducers and high speed valves are used to insure uniform delivery and prevent the possibility of air contamination (Chart 2). There are multiple

submicron filters to insure gas sterility. A mass flow device measures and indicates the flow rates and the actual amount of CO₂ delivered. The system includes an automatic flush system with two one-way valves. Saline is infused through the angiographic catheter at a constant rate, although a higher flow rate can be programmed to intermittently flush the catheter forcefully. After the catheter is connected to the patient, no flushing or manipulation of the stopcock is required. The system includes a pulse oximeter and three-channel pressure monitor for both invasive and noninvasive pressures as well as a recorder for the electrocardiogram.

The injection rate and volume vary with the blood flow and size of the area of interest. For aortograms the rate ranges from 100 to 140 cc/second for a total of 70 cc/second. Pelvic arteriograms require 40 to 60 cc/second for a total of 40 to 60 cc. For bilateral femoral, popliteal, and tibial artery, imaging with the catheter in the distal aorta, similar rates are adequate. More selective injection requires less CO₂ in any given area in the range of 10 to 20 cc/second for a total of 20 to 40 cc. Either antegrade or retrograde injections into the common femoral artery usually improve distal filling. A rate of 10 to 30 cc/second for a total of 20 to 90 cc usually fills the entire distal extremity. With the newer 1024-1024 DSA and new "stacking" software, a total of 10 to 20 cc produces excellent imaging of the pedal arteries if no motion occurs (Figure 11-8).

PLASTIC BAG HAND DELIVERY SYSTEM

Our animal experience taught us not to connect the CO₂ cylinder to any closed system. However, recently we felt that the addition of a two-way stopcock would prevent any misadventures. Recently, when using a new closed system connected to a CO₂ cylinder, a large volume of CO₂ was delivered inadvertently into the right atrium, which resulted in a near fatality (severe bradycardia and hypotension). Because of the extreme solubility of the CO₂ and the short duration of the delivery, the patient recovered uneventfully. Since this event, we use only the dedicated injector or a closed system in which a plastic bag serves as a CO₂ reservoir. This system had previously been used as a fluid management system (AngioDynamics; Glens Falls, NY). A similar system can be easily assembled using a standard 1500 cc plastic I.V. bag, two connecting tubes, and several two- and three-way stopcocks. The AngioDynamic fluid management system uses T fittings with two one-way check valves, which obviates the cumbersome turning of the stopcocks.

Initially, the I.V. bag is filled and flushed three times with 1500 cc of medical grade CO₂. Since the bag is filled to atmospheric pressure and collapses incrementally when the CO₂ is aspirated, there is no gas compression, and the exact amount of CO₂ that is desired to be delivered can be loaded. After all of the air has been flushed from the plastic bag and filled with CO₂, the bagged CO₂ is used to purge the system and fill either the hand delivery syringe or a mechanical injector syringe. The first three-way stopcock is used to fill the delivery syringe and inject the CO₂; the second permits use of a 3 cc syringe which is used to clear the saline from the angiographic catheter before the main bolus of CO₂ is delivered. The two syringe systems are connected with a long connecting tube to increase the distance from the image intensifier; therefore, decreasing radiation to the operator. The key to nonexplosive delivery clearing the catheter of fluid before the bolus of CO₂ is injected. The one-way check valve prevents reflux of blood into the catheter after it is purged with the 3cc syringe. If standard three-way stopcocks are used, any delay in manipulation results in blood reflex into the catheter and thus explosive delivery. After the catheter is purged, CO₂ can very easily be delivered in a controlled manner.

Since the system is totally closed, that is, there is no connection to outside air, the system is totally safe. One should be sure that the luer lock connectors do not separate and preferably should either be taped or glued together.

Fortuitously, the fluid management system has all its connections glued together. Rather than using three-way stopcocks, this system also uses T-connectors equipped with one-way check valves. Using these check valves in place of the three-way stopcocks permits rapid filling and emptying of both the delivery syringe and the 3 cc catheter purging syringe. The one-way check valves totally prevents reflux into the catheter after the saline has been purged from the catheter. Opening and closing of only one stopcock is required. This is a two-way stopcock placed between the T-connector and the 3 cc syringe. Closing this 3 cc stopcock syringe after it is emptied prevents filling of this syringe during delivery of the larger CO₂ bolus. Actually, if the injections are made relatively rapidly there is no need to use the 3 cc syringe since the catheter remains filled with air. If there are extended intervals between CO₂ injections, the catheter can be flushed by the addition of a three-way stopcock attached to the angiographic catheter.

With the resistance of the fluid in the catheter eliminated, the definitive syringe can be advanced forward with a little force with virtually no compression or explosive delivery.

The injection rates are quite similar to those used with the dedicated injector. 140 cc/second are injected for a total of 70 cc; with hand delivery, a 60 cc syringe is used and injection is made in less than one-half of a second. For pelvic and examination of both lower extremities, filming from the pelvis to the trifurcation area, usually 40 cc/second for a total of 60 cc is adequate. Occasionally, larger volumes are needed in slow flow states to obtain adequate filling below the trifurcation and the feet. If "stacking" software is available, smaller volumes are required. If injections into the distal aorta fail to fill the extremity, imaging is always markedly improved if the catheter is advanced over the bifurcation and as close to the area of interest as possible. With contralateral over-the-hill common femoral injections, usually 10 cc/second for a total of 20 cc produce good filling down to and including the feet. The same is true for an injection with the catheter retracted to the ipsilateral common femoral artery. In over 50% of cases, an addition of intra-arterial infusion of 100-150 mg of nitroglycerin also improves the filling, and frequently will result in less segmentation of the CO₂. If "stacking" is not available and segmentation occurs, a longer duration injection and a vasodilator are recommended.

We attempt, especially with "stacking," to inject the smallest amount of CO₂ that will produce good filling since with small injections there is no sensation whatsoever, resulting in a lower probability of patient motion, also, with small volumes the injections can be made more rapidly.

Again, the CO₂ cylinder should never be connected directly to the delivery system since even with arterial injection, the gas flows through the capillary bed into the inferior vena cava and to the heart.

USE OF SMALL CATHETERS

The very low viscosity permits use of very small catheters, which in the past have been very difficult to see fluoroscopically. Very dense soft-tipped catheters and a catheter with a spiral configuration and side-holes along its inner curvature have recently been introduced by AngioDynamics Glens Falls, NY) (Figure 11-9). Although we have injected CO₂ into a gelatin model at a rate of 175 cc/second without damage, we believe that the new halo design prevents intimal damage and dissection if the side-holes become wedged against the vessel wall.

X-RAY EQUIPMENT

The low density of CO₂ requires digital subtraction and electronic enhancement. Although adequate images have been obtained with the first generation Phillips 256-512 equipment, newer 1024-1024 systems provide excellent contrast and resolution approaching that of film-screen combinations. With optimal technique, the imaging of large and medium vessels is comparable to iodinated contrast. Recently, we have found that the kilovoltage has no significant effect on "contrast;" however, adequate penetration and increased number of photons has been extremely important.

Previously, when CO₂ was poorly imaged, we felt that it was inadequately delivered. In actuality, since CO₂ is not diluted as is contrast and will not mix with blood, if the gas produces a low contrast image, the problem is not in delivery, but simply imaging. We have recently found that by increasing the pulse width from 10 milliseconds to 60 milliseconds on the Toshiba DFP60 equipment markedly improved contrast and reduced noise. Also, images obtained with new Phillips DSA equipment has also been improved by increasing the pulse width by 369 milliseconds. If images are not comparable to average iodinated contrast DSA and CO₂ is being used for the first time at your institution, we would strongly recommend imaging CO₂ effectively with a phantom before it is used in patients. A phantom can easily be constructed by placing a 5- or 6-French catheter in a water container or an IV bag. DSA imaging can be obtained repeatedly during the delivery of CO₂. If the CO₂ is poorly imaged, the DSA vendor should be asked to change the exposures parameters to obtain images comparable to iodine.

The addition recently of a "stacking" software program, which integrates a series of images into one composite image, has been extremely helpful. If inadequate amounts of CO₂ are delivered in relatively small vessels or the CO₂ column breaks up secondary to collateral inflow, rapidly obtained images can be "added together," producing a vessel that is completely filled on the final summation image (Figure 11-10). Reducing the injection rate and volume results in essentially no sensation and less probability of motion. The small volumes per injection safely permits more frequent injections.

Recently, we graded 63 cases in which stacking was used. A 0 rating was assigned to vessels not visualized and 3+ to vessels that were well opacified. We compared nonstacked images with stacked images. Basically, only minimal improvement was noted in the abdomen and pelvis mainly because of the more pulsatile nature of these vessels and bowel gas motion artifact. Stacking in the knee, lower leg, and foot was extremely helpful with subtraction when low volumes were injected. In this recent series, the majority of cases demonstrated a average rating of 2.6 to 3 (all the cases being of diagnostic quality). In this small series, the vessels in the feet were seen in all cases with a stacked program, even when as little as 10 cc of CO₂ were injected in the common femoral artery.

Equally as important as stacking is elevation of the extremities or any area of interest. As stated earlier in patients with good flow, the major arteries fill well in the horizontal portion. However, areas of interest lower (more dependent) than the injection site, however, occasionally cannot be opacified. Initially, we used a fluoroscopy-type tilting table which resulted in good filling of even digital vessels in the lower extremity. Over the last six years, we have had second-generation and third-generation DSA equipment, but did not have a tilting table. We have used foam wedges, which results in some minimal motion, and more recently a hinged, ratchet-type Plexiglas (Andio-Dynamics, Glens Falls, NY) device, which permits easy elevation of the extremities. Several companies are manufacturing tilting tables, some which will also rotate in oblique positions. We have recently developed a tilting table which not only tilts the entire patient, but will elevate only the pelvis and legs, thus improving patient comfort.

DIAGNOSTIC ACCURACY

In general, the decreased density of CO₂ is more difficult to image and interpret than iodinated contrast material. In the past, with poor delivery systems and the early DSA units, many times four or five injections were required to obtain a single diagnostic image. Similar to iodinated contrast DSA, the limitation has been bowel peristalsis and patient motion. Inability to deliver the CO₂ consistently also inhibited easy interpretation. Our experience of over 1000 cases has shown basically that images have been of diagnostic quality in over 90% of the cases (Chart 1). In the past, vessels below the knees have also been more difficult to image. Recently, by elevating the feet, injecting low volumes of CO₂, which reduces adverse sensations and patient motion artifact, using stacking software, and injecting vasodilators (Figure 11-11), the vessels to the ankle can almost always be imaged. Similar to iodinated contrast material, the closer the catheter is to the area of interest, the better the filling. Occasionally, both feet can be imaged with an injection in the distal aorta, but if there are occlusions or stenosis, advancing the catheter over the aortic bifurcation and down into the common femoral or lower, obviously improves the filling.

In several patients, we have obtained diagnostic information with CO₂ that cannot be obtained with iodinated contrast material. We have seen arteriovenous shunting in malignant renal, hepatic, and bone and soft tissue tumors (Figures 11-12 and 11-13). Arteriovenous shunting was seen in 54 bone and soft tissue tumors using CO₂, with iodinated contrast material demonstrating arteriovenous shunting in only four of these patients [7]. We and others have also noted arteriovenous shunting in malignant liver tumors [7,17]. Frequently, collateral vessels have filled better with CO₂ than with iodinated contrast material, probably because of the buoyancy and lower viscosity of CO₂. In areas of stasis where iodinated contrast material flows very slowly and is diluted, the vessels may not be seen, but the buoyancy of CO₂ may result in excellent arterial filling (Figure 11-14).

Even with total occlusion of the iliac artery and superficial femoral artery, by elevating the contralateral pelvis and legs the buoyancy of CO₂ fills the distal circulation (Figure 11-15). We initially thought that CO₂ was a potent vasodilator, but recently we have found that nitroglycerin markedly improves filling. The CO₂ seems to flow much more quickly and uniformly, especially below the knee (Figure 11-11).

Our surgeons have recently compared the diagnostic accuracy of both iodinated contrast material and CO₂ to operative findings in 94 patients. In 92% of the cases, CO₂ angiography provided accurate information. Most importantly, 65 of these patients were at a very high risk for standard angiographic procedures, having a severe iodinated contrast material allergy or renal failure. Our surgeons are also routinely requesting CO₂ as a contrast medium to evaluate surgical procedures such as aortobifemoral grafts and reimplanted renal arteries. The use of 3F catheters and the very safe CO₂, provides important information at a very low risk (Figures 11-17 and 11-18).

CARBON DIOXIDE DIGITAL SUBTRACTION ANGIOGRAPHY FOR INTERVENTIONAL PROCEDURES

The safety and ability to use unlimited quantities of CO₂ are ideal for interventional procedures (e.g., embolization, percutaneous transluminal angioplasty). We frequently use CO₂ for renal and iliac superficial angioplasty and for embolization procedures in patient who are at risk with iodinated contrast material. A significant advantage of CO₂ is the ability to inject large volumes of the gas between the catheter and the guidewire using Touhey-Bourst fittings and a 20 cc syringe (Figure 11-19). Because of the low viscosity of CO₂, the entire interventional procedure (percutaneous

transluminal angioplasty in any area) can occasionally be performed without removing the guidewire from the percutaneous transluminal angioplasty balloon catheter.

CARBON DIOXIDE DIGITAL SUBTRACTION ANGIOGRAPHY DETECTION OF GASTROINTESTINAL HEMORRHAGE

Hiramatsu (Paper presented at Annual Meeting of the Western Angiographic and Intervention Society, Kona, Hawaii, 1992) recently presented 42 patients with bleeding in various sites such as gastrointestinal tracts, pelvis, kidneys, in which CO₂ dramatically demonstrated the bleeding site. Of the 42 cases, CO₂ detected 15 cases of bleeding that could not be demonstrated with iodinated contrast material. Of these 15 sites, 12 were embolized with hemodynamic stabilization, two were managed conservatively, and one was surgically corrected. The low viscosity of the gas makes it flow easily through the arterial rent, and when exposed to the lower extravascular pressure it markedly expands. Iodinated contrast conversely may not flow through the small tear due to its high viscosity, and when entering the bleeding site it is usually diluted by extravasated blood.

COMPLICATIONS

In our series, we have had only one complication that was directly related to CO₂ injection. Over 2000 cc of CO₂ were injected into the large abdominal aneurysm in less than one hour. The patient experienced minimal or no discomfort during the examination. After the last examination, however, he developed diarrhea, which persisted for approximately eight hours. Endoscopy at that time suggested ischemia; however, the biopsy was normal. After eight hours the diarrhea abated, and a repeat biopsy three days later was totally normal. The inferior mesenteric artery originated from the most anterior portion of the aneurysm which exposed the inferior mesenteric circulation to CO₂ for at least an hour. The CO₂ was probably trapped in the circulation, resulting in some degree of ischemia. We have also found recently that the CO₂ traps in a aneurysm and remains for an extended period of time. We have obtained computed tomography scans in these patients and noted a small amount of CO₂ 24 hours after injection. The CO₂ is trapped because of its buoyancy and the configuration of the aneurysm. We have speculated that the high partial pressure of nitrogen and oxygen in the blood is high enough to replace the CO₂ trapped in the aneurysm. Both oxygen and nitrogen are much less soluble than CO₂, which probably explains why the gas is seen 24 hours later. We have used CO₂ in a large number of aneurysms without any complications other than the one described. We now suggest, however, that the amount of CO₂ be limited in patients with aneurysms and the patient's position should be changed to free the CO₂. Also, in patients in whom large volumes are used in the lower extremity, the legs should be lowered between injections. Theoretically, the CO₂ could also trap in the feet, as it does in the aneurysm. If time is allowed to lapse between injections, the CO₂ should dissolve and prevent the possibility of ischemia.

CARBON DIOXIDE IN PATIENTS WITH DECREASED PULMONARY FUNCTION

Because CO₂ is eliminated from the lungs, and is also dissolved in the blood, we would recommend that it not be used in patients with abnormal pulmonary function unless blood gases are obtained after each injection. In over ten cases with pulmonary failure in which iodinated contrast material could not be employed because of allergy or renal failure, we have noted normal arterial blood gases after multiple CO₂ injections. We terminated a CQ arteriogram in one patient who demonstrated a slight pH elevation. Also, if the patient is acidotic, blood gases should be obtained and the amount of CO₂ appropriately limited.

NEUROTOXICITY

For arterial imaging, we do not use CO₂ above the diaphragm for any indication because of preliminary studies in rats, which suggested that it may be a neurotoxic. In 1980, we injected the aortic arch, carotid artery, and vertebral artery with very large volumes of CO₂ in ten canines, with the head elevated to 45 degrees without untoward effects. In 20 rats, injection of .5-1.5 cc of CO₂ in the carotid arteries with a tuberculin syringe resulted in neurological deficit and disruption of the blood-brain barrier [17]. Possibly, the relatively large volume or possibly the "explosive" delivery that occurs with the small catheter and the 1 cc syringe may have resulted in the deficit. Also, there is a recent report of 15 canines receiving large amounts of CO₂ without any histological changes or neurologic deficit [18].

To assess potential spinal cord toxicity, we studied ten canines, injecting 200 cc by hand in the abdominal aorta with the animal in the prone position. A neurological examination performed 24 hours after the injection by a veterinarian neurologist failed to demonstrate any deficit. Plich (Personal communication, 1986) has used CO₂ for coronary arteriography and angiography of congenital heart disease with no neurologic complications. Despite these encouraging findings, we believe that the use of CO₂ above the diaphragm is contraindicated in humans until it undergoes extensive testing in primates. Even if CO₂ is indeed innocuous in the cerebral circulation, with a nondedicated delivery system, there is always a possibility of air contamination, which could result in serious complications.

RENAL TOXICITY

Because the CO₂ is apparently eliminated from the lungs in a single pass, injections distal to the renal arteries should have no impact whatsoever on renal function. We made selective renal artery CO₂ injections in over 50 patients without significant change in creatinine. We recently completed a study in 14 canines in which very large doses were injected selectively into one renal artery every 2 minutes for a total of 13 injections. The contralateral kidney was used as a control. Nuclear medicine studies (dimercaptosuccinic acid and I-131 hippuran) were used to measure flow and function before, immediately after, and 24 hours after the CO₂ injections. Light, transmission electron, and scanning electron microscopy were obtained 36 hours after CO₂ was injected. The study showed an immediate decrease in flow by an average of 5%, which returned to normal within 24 hours in all the animals. There was no scanning electron microscopy changes in any of the animals. Both proximal and peripheral renal arteries were imaged in all animals; however, a parenchymal phase including the corticomedullary junction was seen in only one animal. This was one of three animals in which the kidney was vertically positioned above the catheter. Light microscopy of this vertical kidney demonstrated acute tubular necrosis; however, flow and function was normal. Two other animals with the kidney positioned vertically also demonstrated nonsignificant transmission electron microscopy changes. The study showed that no toxicity occurred with very high CO₂ exposure with the kidney in the lateral position. With frequent injections in the vertical position, however, CO₂ may have been trapped and caused ischemia. Although a recent study in 20 high risk transplant patients (unpublished data) demonstrated no increase in postprocedural creatinine, in transplanted kidneys and other areas of interest which are anterior to the injection site, we recommend waiting 3 to 5 minutes between injections or changing position to allow the CO₂ to dissipate.

ANGIOSCOPY: CARBON DIOXIDE DISPLACES BLOOD FOR CLEAR VIEWING

Although cut-film angiography has been the gold standard for vascular imaging, intravascular ultrasound occasionally has demonstrated significant stenoses in arteries that appear relatively normal with angiography. Angiography also cannot determine the cause of the obstruction (e.g., clot, plaque, emboli). Unfortunately, intravascular ultrasound probes are very expensive and presently cannot look forward. Although intravascular ultrasound can image the interior of the vessel, and can "see through" the wall of the vessel, it is not useful for evaluation of total occlusions. Angioscopy, on the other hand, can directly inspect the interior of the vessel and determine the cause of the obstruction [19]. Angioscopy is used during bypass graft surgery with excellent results [20]. It is usually performed with surgical inflow occlusion, and even then, because of collaterals, an average of 500 cc of saline is required to displace the blood during viewing. If angioscopy is used percutaneously, balloon occlusion is required, and large amounts of saline are needed to displace the blood. We have found that the ability to displace the blood totally with CO₂ provides clear angioscopic viewing without the danger of fluid overload [15]. We have been able to visualize large iliac arteries and the aorta with retrograde CO₂ injections. Balloon occlusion is not necessary in the distal circulation. In animal experiments and in patients, the depth of field and the clarity are improved with CO₂ displacement. Inflow from collateral arteries with "clouding" of the field occurs less often with CO₂, and the duration of viewing per injection is longer [15]. We have limited the use of CO₂ primarily in patients in whom large sheaths are placed because the smallest angioscopes with good resolution were 7F outer diameter. These angioscopes have a channel through which saline could be infused. The very low viscosity of the CO₂ permits injection through a very minute channel. CO₂ can be delivered between the inner diameter of the catheter and the outer diameter of the optic fiber using a high-pressure Touhey-Bourst fitting. Recently, very small diameter (< 0.36-inch) fiberoptic scopes, which pass through even 4F catheters, have become available with resolution approaching that of the larger scopes. Again the low viscosity of CO₂ permits its delivery between the fibers and the catheters. Angioscopy can be used to verify and determine the cause of obstructions, and potentially to actually view the area of interest during interventional procedures. The same precautions used with CO₂ DSA should be used with CO₂ angioscopy.

CONCLUSIONS

Over the last five years, there have been many improvements in the delivery system and imaging of CO₂. CO₂'s many advantages versus iodinated contrast (Table 1) include a total lack of allergic response, minimal or no renal toxicity, minimal discomfort, and low viscosity, which permits use of catheters as small as 1.5 French. The low viscosity improves collateral filling, opacification of tumors, facilitates arteriovenous shunting in malignant tumors, and improves the diagnostic accuracy in the evaluation of bleeding sites. One of the most important advantages is that it is very inexpensive. Because CO₂ is eliminated by the lungs, it can be used in virtually unlimited volumes if time is allowed between injections which is ideal for interventional procedures. Occasionally, CO₂ cannot image a particular area because of bowel gas motion or the lesion's dependent location. If CO₂ imaging fails, a very small amount of iodinated contrast material may be used, which reduces the cost of the procedure, and also reduces the risk of renal failure.

We have found that if proper x-ray exposure is obtained, diagnostic images can be obtained with any type of DSA equipment. One should be aware of all the physical properties of CO₂, and be very cautious; either use a dedicated delivery system, use a system which eliminates any possibility of delivering excessive volumes or air contamination.

REFERENCES

1. Paul RE, Durant TM, Oppenheimer MJ, Stauffer HM. Intravenous carbon dioxide intracardiac gas contrast in the roentgen diagnosis of pericardial effusion and thickening. *AJR* 1957; 78:224-225.
2. Scatliff JH, Kummer AJ, Janzen AH. The diagnosis of pericardial effusion with intracardiac carbon dioxide. *Radiology* 1959; 73:871-883.
3. Phillips JH, Burch GE, Kekkinger R. The use of intracardiac carbon dioxide in the diagnosis of pericardial disease. *Am Heart J* 1961; 61:748-755.
4. Oppenheimer MJ, Durant TM, Stauffer HM, Steward GH, Lynch PR, Barreta F. Cardiovascular-respiratory effects and associated changes in blood chemistry. *Am J Physiol* 1956; 186:325-334.
5. Bendib M, Toumi M, Boudjellab A. Carboxyangiographie et carboxyangiographie elargie en cardiologie. *Ann Radiol* 1977; 20:673-686.
6. Hawkins IF. Carbon dioxide digital subtraction arteriography. *AJR* 1982; 139:13-24.
7. Hawkins IF Jr, Herrera MA. Carbon dioxide has promise as arterial contrast agent. *Diagn Imaging* 1985; 82-84.
8. Hawkins IF Jr, Akins EW, Seeger J. Carbon dioxide (CO₂) as a contrast agent for angiography and angioscopy. In: Ahn and Moore eds. *Endovascular surgery*, 2nd ed. Philadelphia: W.B. Saunders 1992; 473-480.
9. Murray KK, Hawkins IF Jr. Angiography of the lower extremity in atherosclerotic vascular disease: current techniques. *Surg Clin N Am* 1992; 72:767-789.
10. Miller FJ, Mineau DE, Koehler PR, et al. Clinical intra-arterial digital subtraction imaging: use of small volumes of iodinated contrast material or carbon dioxide. *Radiology* 1983; 148:273-278.
11. Krasny VR, Hollmann JP, Günther RW. Erste Erfahrungen mit CO₂ als gasförmiges Kontrastmittel in der DSA. *Fortschr. Röntgenstr.* 1987; 146:450-454.
12. Weaver FA, Pentecost MJ, Yellin AE, Davis S, Finck E, Teitelbaum G. Clinical applications of carbon dioxide/digital subtraction arteriography. *J Vasc Surg* 1991; 13:266-273.
13. Kudo M, Tomita S, Tochio H. Sonography with intraarterial infusion of carbon dioxide microbubbles (sonographic angiography): value in differential diagnosis of hepatic tumors. *AJR* 1992; 158:65-74.
14. Silverman SH, Mladinich CRJ, Hawkins IF, Abela JF, Seeger JM. The use of CO₂ gas to displace flowing blood during angioscopy. *J Vasc Surg* 1989; 10:313-317.
15. Mladinich CRJ, Akins EW, Hawkins IF Jr. Feasibility of carbon dioxide (CO₂) as an angioscopic medium: comparison to various methods of saline delivery to improve angioscopic visibility. *Invest Radiol* 1991; 26:874-878.
16. Takeda T, Ido K, Yuasa Y, et al. Intraarterial digital subtraction angiography with carbon dioxide: superior detectability of arteriovenous shunting. *Cardiovasc Intervent Radiol* 1988; 11:101.
17. Coffey R, Quisling RG, Mickle JP, Hawkins IF Jr, Ballinger WB. The cerebrovascular effects of intra-arterial CO₂ on quantities required for diagnostic imaging. *Radiology* 1984; 15:405-410.

18. Shifrin EG, Plich WB, Verstandig AG, Gomori M. Cerebral angiography with gaseous carbon dioxide CO₂. *J Cardiovasc Surg* 1990; 31:603-606.
19. Giacomino PP, Abela GS, Barbeau GR, Seeger JM, Tomaru T, Hawkins IF, Abela JF. Angioscopy: current techniques. *Dynamic Cardiovasc Imag* 1989; 2:178-187.
20. Miller A, Stonebridge P, Jepsen S, et al. Continued experience with intraoperative angioscopy for monitoring infrainguinal bypass grafting. *Surgery* 1991; 109:286-293.

CLINICAL EXPERIENCE

> 1000 PTS

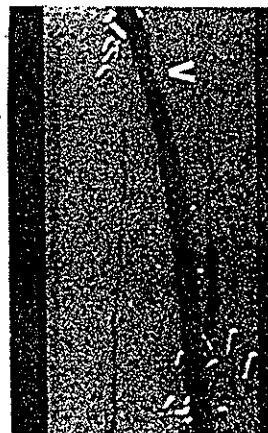

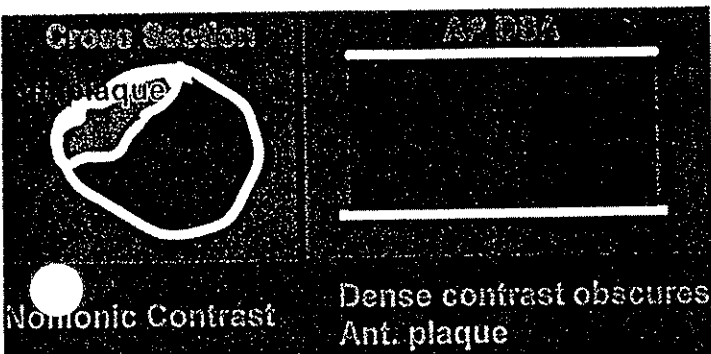
- A & RUNOFF > 700 PTS.
- BONE & SOFT TISSUE TUMORS > 180 PTS.
- RENAL TRANSPLANT & SURGICAL REIMPLANTED KIDNEY > 50 PTS.
- INTERVENTIONAL PROCEDURES > 100 PTS.
- ARTERIAL BLEEDING > 27 PTS.
- TIPS > 50 PTS.

APPROX. 90-95% OF CO₂ STUDIES CONSIDERED DIAGNOSTIC. FAILURES SECONDARY TO MOTION (BOWEL GAS, PT MOVEMENT).

- WHAT ARE DIAGNOSTIC ANGIOGRAPHIC STUDIES?

OCCASIONALLY, BOTH CO₂ AND IODINE ARE NOT ACCURATE.


CO₂ USUALLY MORE ACCURATE THAN IODINE. WITH COMPUTER CONTROLLED INJECTOR, ONLY A FEW STENOSIS WERE "OVERESTIMATED."



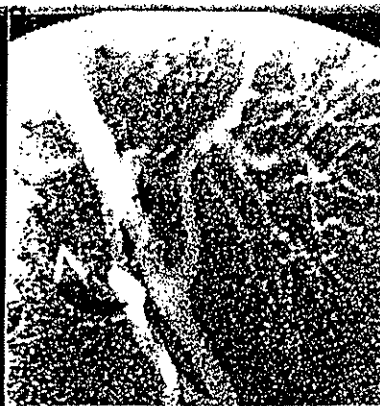10cc NONIONIC. NO STENOSIS SEEN.



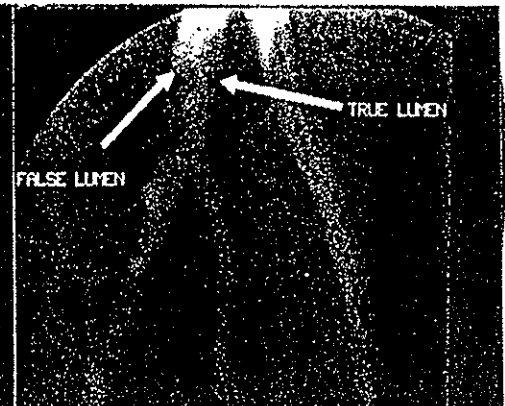
DISTAL FEM-TIB GRAFT STENOSIS EASILY SEEN WITH CO₂.



ABDOMINAL AORTOGRAM
 140cc/sec FOR TOTAL OF 70cc.
 SEVERE RT RENAL ARTERY STENOSIS.



20cc CO₂ - PATENT RENAL TRANSPLANT ANASTOMOSIS.

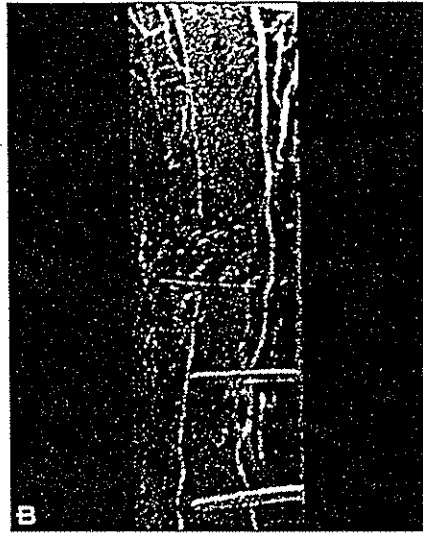


DISSECTED COMMON ILIAC ARTERY SECONDARY TO RENAL TRANSPLANT PTA. Dx NOT MADE WITH NONIONIC CONTRAST.



FIGURE 11-1

Equally good filling of the lower leg in a young patient with a transected anterior tibial artery with both



nonionic (A) and CO₂ (B) contrast with the patient in a horizontal position.

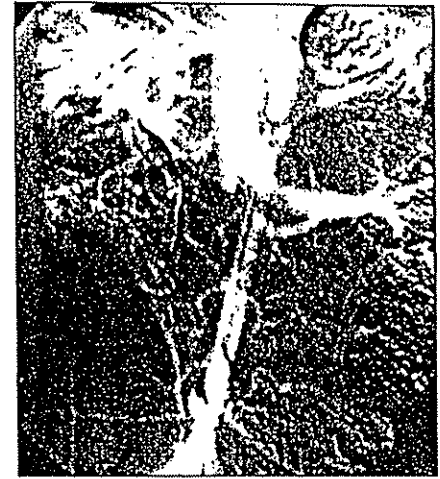

FIGURE 11-2

A canine abdominal aortogram injecting 50 mL CO₂ demonstrates CO₂ filling the aorta, renal veins, and inferior vena cava.

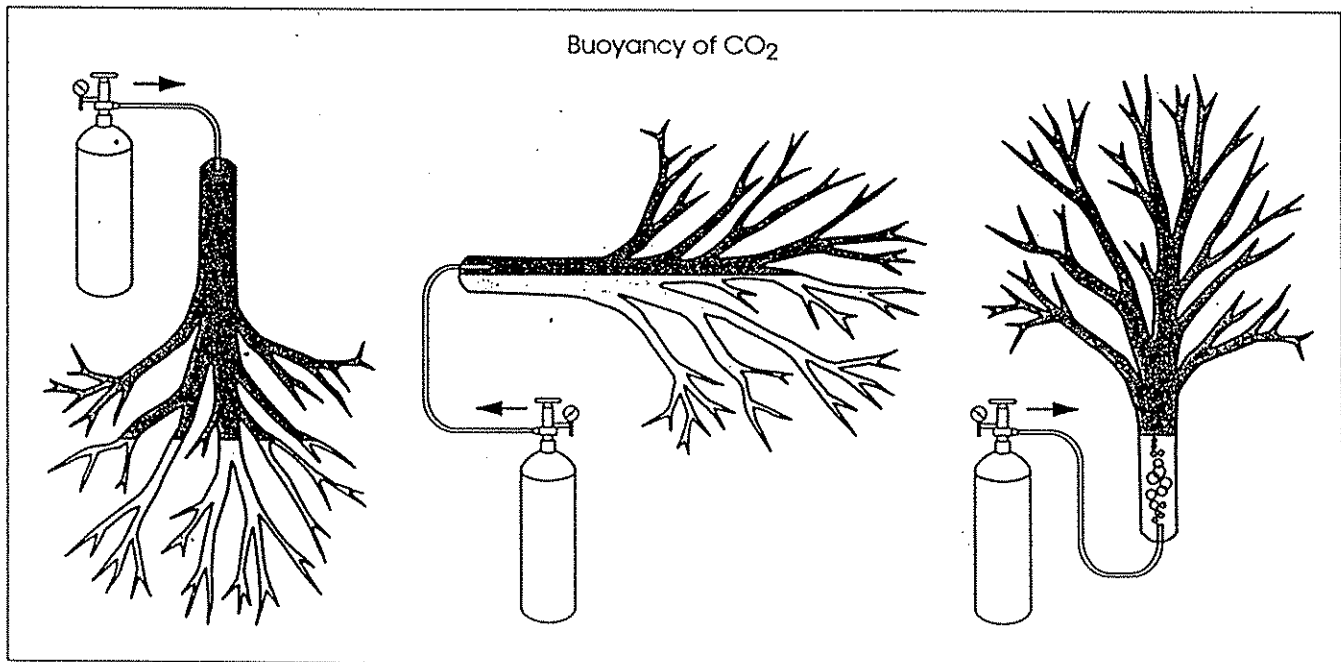


FIGURE 11-3

Analogy of attempting to fill a hollow tree with helium.

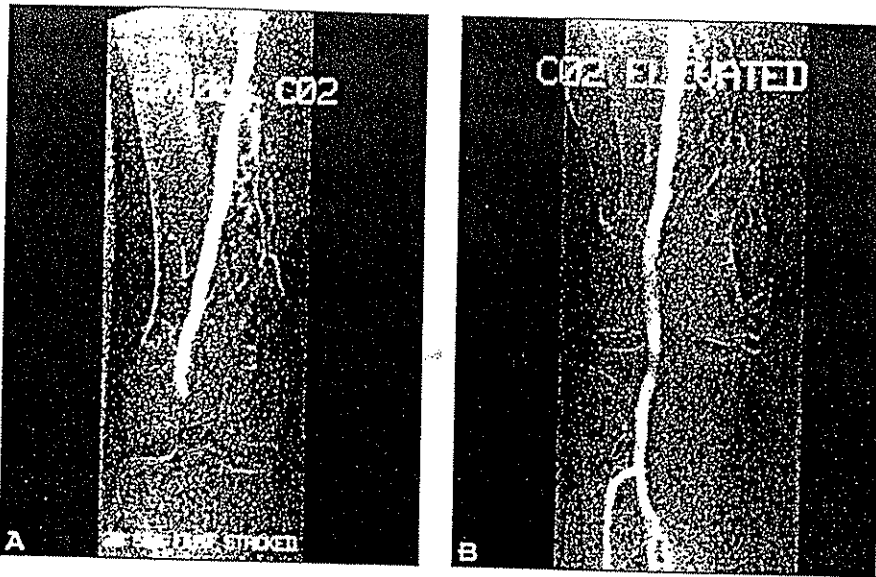


FIGURE 11-4

Comparison views of the knee after 10 mL injection of CO₂ in the flat position. (A) In flat position no filling seen below the knee (0 rating). (B) With feet elevated, good visualization below the knee (3+ rating).

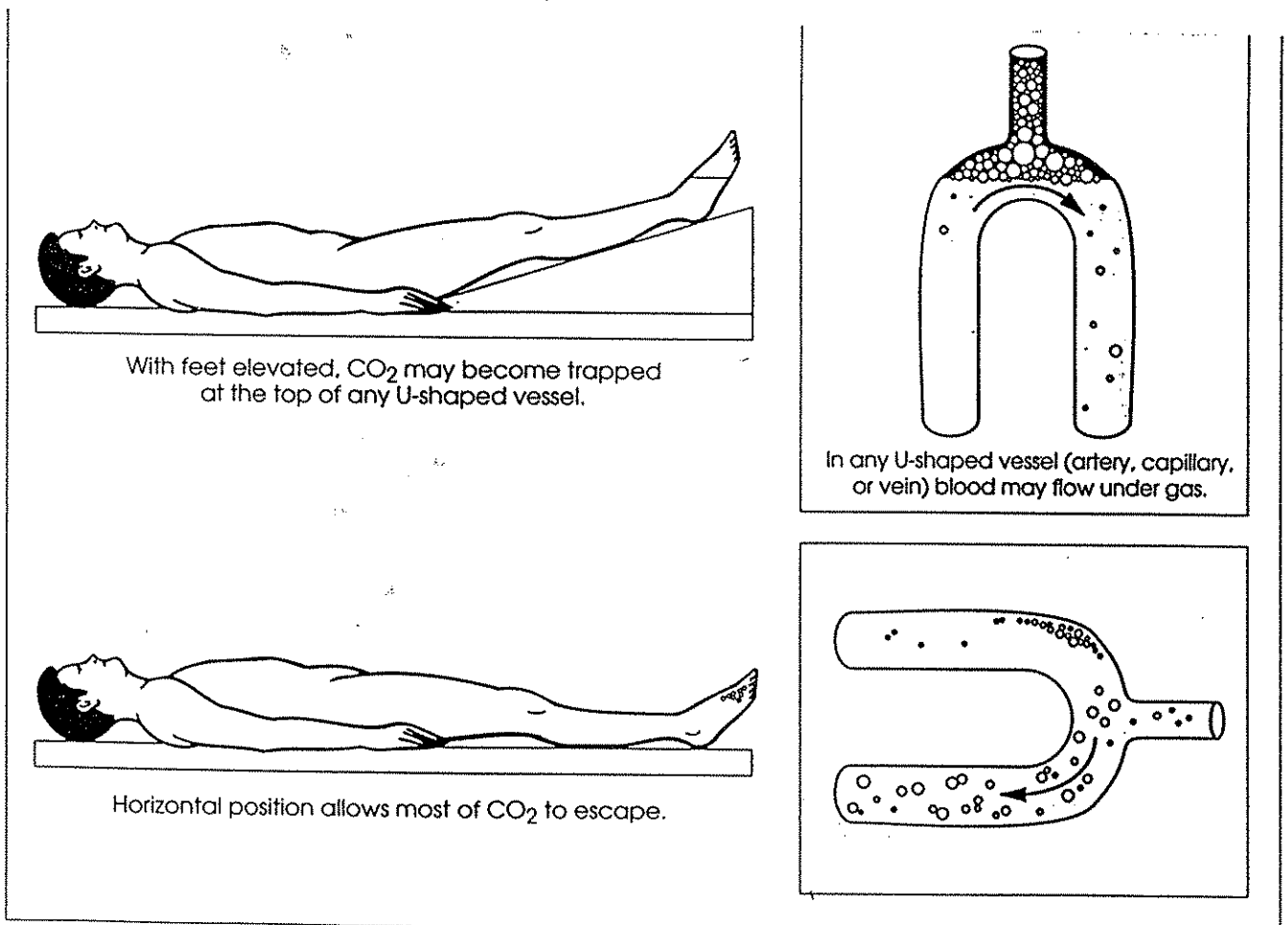


FIGURE 11-5

Hypothetical mechanism for trapping and release of CO₂ in any inverted U-shaped conduit.

COMMERCIAL MODEL


ANGIODYNAMICS, GLENS FALLS, NY

SINGLE UNIT WITH MULTIPLE MODALITIES CONSERVES SPACE

- CO₂ INJECTOR MODULE.
- PATIENT MONITOR (EKG, IBP, NIBP, PULSE OXIMETRY, RESPIRATION).
- OPTIONAL IODINATED CONTRAST INJECTOR MODULE.

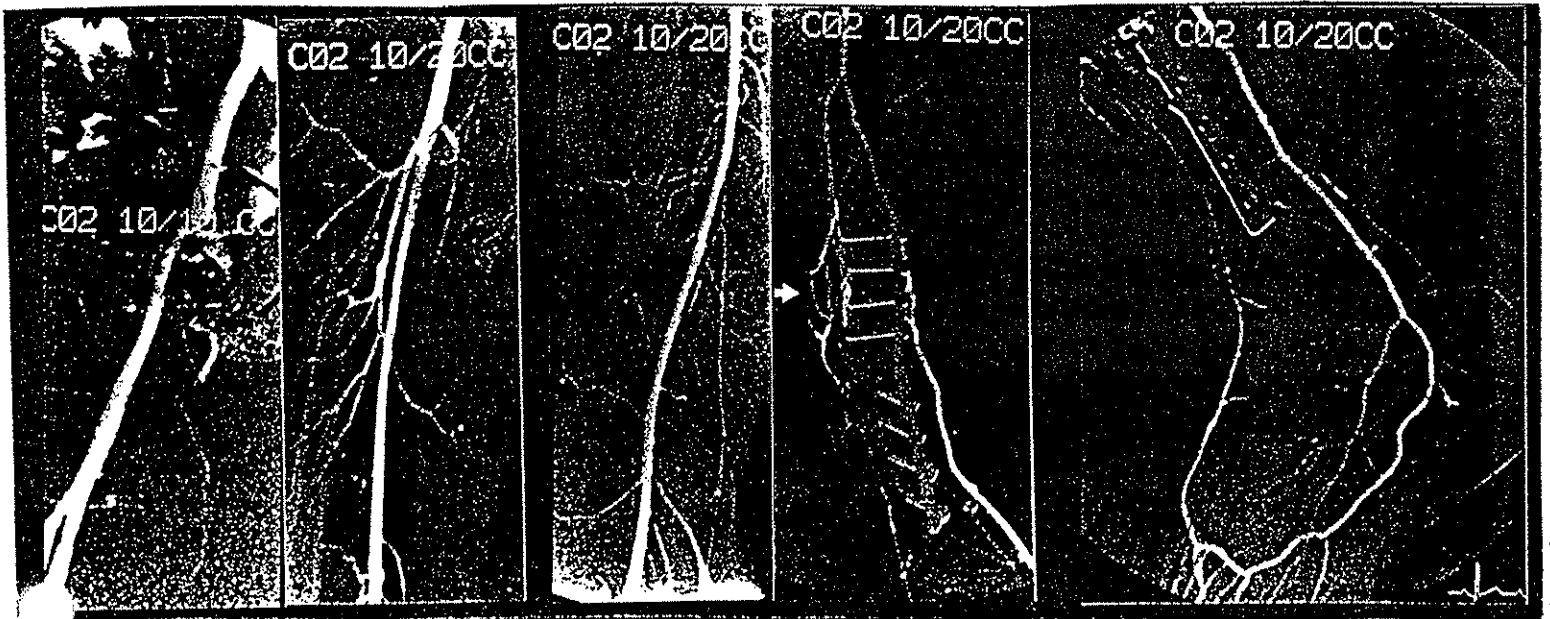
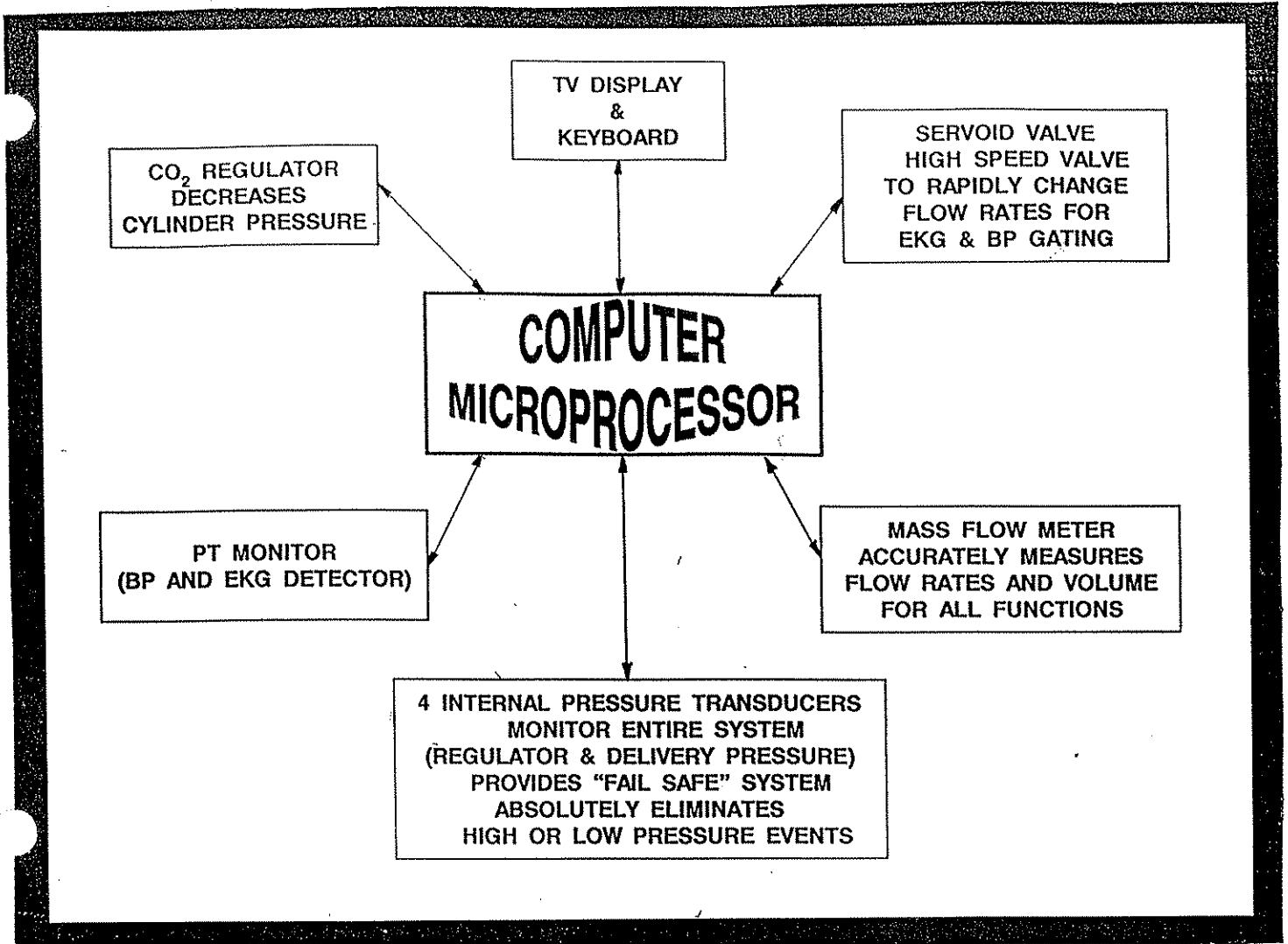
AUTOMATED SALINE FLUSH & BP MONITORING SYSTEM

- SINGLE CONNECTION TO CATHETER.
- CATHETER AUTOMATICALLY FLUSHED WITH SALINE AFTER EACH CO₂ INJECTION (*NO STOPCOCK MANIPULATION*).
- CONSTANT DISPLAY OF ARTERIAL BP AFTER SINGLE CONNECTOR IS ATTACHED TO CATHETER (*NO FLUSHING, etc., REQUIRED*).



INJECTOR'S KEY FUNCTIONS

- PRECISION INJECTION RATES AND VOLUMES - COMPUTER DETERMINES REQUIRED RATE AND FLOW FACTORS FOR EACH DIFFERENT ANGIO CATHETER.
- CLOSED SYSTEM - PREVENTS AIR CONTAMINATION. [ALL CONNECTIONS ARE EQUIPPED WITH O-RINGS TO PREVENT POSSIBLE AIR CONTAMINATION (VENTURI EFFECT)].
- FLUID REMOVED FROM CATHETER TO PROVIDE "NONEXPLOSIVE" DELIVERY - COMPUTER INJECTS EXACT AMOUNT OF CO₂ TO REMOVE SALINE FROM CATHETER PRIOR TO BOLUS DELIVERY.
- AUTOMATIC CONSTANT SALINE FLUSH AFTER EACH INJECTION.
- EKG AND BP GATING TO INJECT MORE CO₂ DURING SYSTOLE AND LESS DURING DIASTOLE (EVEN DISPLACEMENT OF BLOOD).
- INCORPORATED MASS FLOW INDICATOR DISPLAYS RATE AND VOLUME AND TOTAL VOLUME OF CO₂ DELIVERED DURING THE ENTIRE STUDY. (MAXIMUM VOLUME PER PATIENT IS 1000cc.)




PT WITH NON-HEALING WOUND SECONDARY TO LOWER LEG TRAUMA.
GOOD IMAGING FROM PELVIS TO FOOT WITH A.T. AND PERONEAL OCCLUSION.

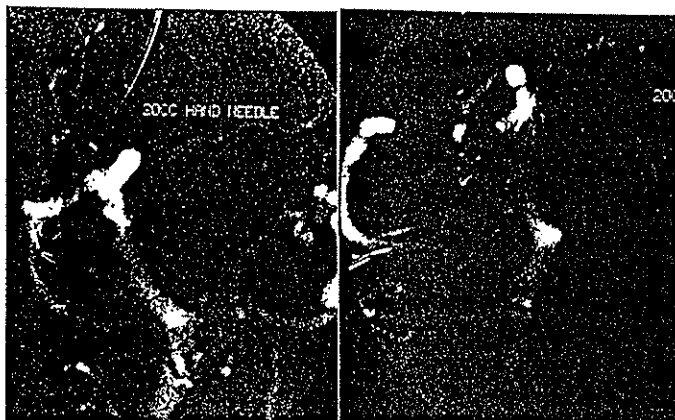
CO₂ WITH FINE NEEDLE TIPS USED SINCE 1991 > 50 PTS

CO₂ USED FOR ENTIRE PROCEDURE:

- ELIMINATES RISK OF RENAL FAILURE.
- WEDGE HEPATIC INJECTION (PORTOGRAM 86% OF 32 PTS).
- FINE NEEDLE IN PARENCHYMA (PORTOGRAM 100% OF 12 PTS).
- INJECTION BETWEEN NEEDLE & GUIDEWIRE FILLS ENTIRE PORTAL VEIN VERIFYING ENTRY SITE BEFORE CATHETER OR STENT IS PLACED.



WEDGED HEPATIC INJECTION WITH 12-F CATHETER
20cc CO₂
10% EXTRAVASATION.



AP RPO
21-GAUGE NEEDLE ADVANCED INTO PARENCHYMA
20cc CO₂ INJECTED.
GOOD PORTOGRAM OBTAINED.
NO EXTRAVASATION.



20cc OF CO₂ INJECTED BETWEEN 21-GAUGE NEEDLE & .018 WIRE.

INTERVENTIONAL PROCEDURES

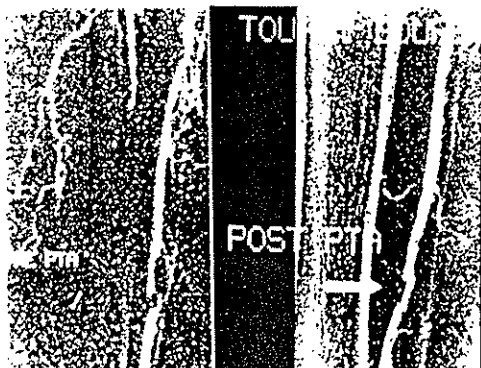
> 120 PTS

EMBOLIZATION
ANGIOPLASTY

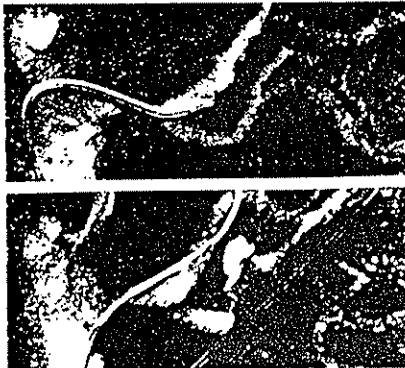
STENTS
NEPHROSTOMIES

FILTER PLACEMENT
VENOUS LINE


- CO₂ HAS NO MAXIMUM TOTAL "DOSE."
(CO₂ ELIMINATED FROM CIRCULATION IN SINGLE PASS.)
- LOW VISCOSITY - ✓ USE VERY SMALL CATHETER.
- ✓ LARGE VOLUME INJECTION BETWEEN CATHETER AND GUIDEWIRE USING TOUHEY BOURST.



OVER THE HILL ANT. TIBIAL PTA USING ONLY CO₂
ALL INJECTIONS MADE BETWEEN 12-F PTA CATHETER AND .018 GUIDE



RENAL PTA WITH 4-F CATHETER CROSSING TIGHT STENOSIS.
ALL SUBSEQUENT INJECTIONS MADE BETWEEN CATHETER



TRANSLUMBAR IVC HICKMAN PLACED ONLY WITH CO₂.

TABLE 1

CO₂ DSA vs. NONIONIC

ALLERGY:	NONE.	LESS THAN IONIC CONTRAST.
IMAGING:	ADEQUATE OPACIFICATION WITH DSA.	DENSER OPACIFICATION WITH DSA.
VASCULAR FILLING:	INCREASED OPACIFICATION OF COLLATERAL VESSELS.	SIMILAR TO IONIC CONTRAST.
	AV SHUNTING FREQUENT- LY SEEN IN TUMORS.	AV SHUNTING SEEN LESS OFTEN.
	TUMOR VESSELS OCCASION- ALLY FILLED ONLY WITH CO ₂ .	DENSER OPACIFICATION OF TUMOR BLUSH WHEN TUMOR SEEN.
TOTAL VOLUME:	UNLIMITED IF DELIVERED IN SMALL QUANTITIES (<100cc/- INJECTION EVERY 2-3 MIN).	LIMITED BY RENAL FUNCTION. ? SAME AS IONIC CONTRAST.
RENAL TOXICITY:		
INJECTIONS DISTAL TO RENAL ARTERIES:	NONE.	? LESS THAN IONICS BUT DEFINITE RENAL TOXICITY IN PTS WITH RENAL FAILURE.
SELECTIVE RENALS:	NONE (50 HIGH RISK PTS, TRANSPLANT AND REIM- PLANTED RENAL ARTERIES, ALL WITH ↑ CREATININE AND MANY WITH DIABETES).	? LESS THAN IONICS BUT DEFINITE RENAL TOXICITY IN PTS WITH RENAL FAILURE.
PAIN:	~ 90% OF PTS EXPERIENCE MINIMAL OR NO SENSATION. ~ 10% HAVE MILD TO MODER- ATE DISCOMFORT.	MAJORITY OF PTS EXPERIENCE DISCOMFORT BUT CONSIDER- ABLY LESS THAN IONICS.
VISCOSITY:	~ <u>1</u> OF NONIONIC CONTRAST. 800 CAN BE USED w/1.5 F CATH. CAN INJECT EASILY BETWEEN CATHETER AND GUIDEWIRE.	VERY VISCOUS (NEED AT LEAST 4 F, HIGH-FLOW CATHS FOR ABDOMINAL ARTERIO- GRAPHY.
ANTICOAGULATION EFFECT:	NONE. CO ₂ WITH CHECK VALVES PREVENTS FLOW OF BLOOD INTO CATHETER.	NONE. HEPANIZED SALINE RAPIDLY MIXES WITH BLOOD REQUIR- ING FREQUENT FLUSHINGS.
COST:	"ESSENTIALLY FREE" \$.0000056/cc.	EXTREMELY EXPENSIVE \$1.00/cc.