

Carbon Dioxide Gas as an Arterial Contrast Agent

James M. Seeger, M.D., Stephen Self, M.D., Timothy R. S. Harward, M.D.,
Timothy C. Flynn, M.D., and Irwin F. Hawkins, Jr., M.D.

*From the Departments of Surgery and Radiology, University of Florida, College of Medicine,
Gainesville, Florida*

Objective

To investigate the clinical utility of CO₂ gas as an arterial contrast agent, the experience with CO₂ arteriography at the University of Florida was reviewed.

Summary Background Data

Preliminary studies have demonstrated the feasibility of CO₂ arteriography and shown that arterial injection of CO₂ gas appears non-toxic (which could limit the risks of contrast induced renal injury and allergic reaction). However, numerous technical problems make CO₂ arteriography a demanding technique and recent studies have suggested that distal lower extremity vessels are difficult to image using CO₂ arteriography, especially when significant arterial occlusive disease is present.

Methods

One hundred twenty-eight CO₂ arteriograms done in 115 patients were reviewed. CO₂ arteriograms were graded as excellent, good, poor, or inadequate by two blinded observers and results of CO₂ studies compared to results of standard contrast studies (done in 98 patients for image comparison). In addition, a therapeutic plan based on the CO₂ arteriograms was compared with the therapy each patient received.

Results

One hundred-seventeen (91%) of the CO₂ arteriograms were of good or excellent quality and agreement between CO₂ studies and standard contrast studies was seen in 93 of 98 cases (95%). Accurate therapeutic plans based on CO₂ studies were possible in 92% of cases with inadequate visualization of infrapopliteal arteries being the major limitation (7 cases). No allergic reactions occurred and only one patient potentially had contrast-induced nephrotoxicity.

Conclusions

CO₂ arteriography provides accurate, clinically useful arterial imaging with minimal risk. Thus, this new technology significantly increases the utility of arteriography in patients with peripheral vascular disease.

Improvements in surgical arterial reconstruction and introduction of endovascular therapy of arterial lesions have significantly lessened the morbidity associated with treatment of peripheral vascular disease. However, arteri-

ography, which is necessary to determine the location, nature, and extent of arterial lesions continues to be associated with small but significant risks of vessel injury, contrast-induced nephrotoxicity, and allergic reactions

Elderly patients presenting with peripheral vascular disease often have co-existing renal, cardiac, and other medical illnesses that increase the risk of these complications. Therefore, in many patients, much of the risk associated with treatment of peripheral vascular disease is due to the risk of arteriography. In addition, in some patients, these risks are such that therapy of peripheral vascular disease must be deferred because arteriography is contraindicated.

Hawkins¹ initially described the use of CO₂ gas for arterial imaging in 20 patients in 1982. Injection of CO₂ gas transiently displaces blood from the artery being studied and arterial imaging is then achieved using digital subtraction techniques (DSA) to detect small differences in density between the gas-filled arterial lumen and the surrounding arterial wall. CO₂ gas does not appear to be nephrotoxic, does not cause allergic reactions and can be delivered through small catheters. Therefore, use of CO₂ gas as a contrast agent for arterial imaging potentially can significantly reduce the risk of arteriography.

Numerous technical problems including the possibility of "explosive" type injection, the buoyancy of the gas, which makes imaging of dependent arteries difficult and the break-up of the gas column as it moves distally makes CO₂ arteriography a demanding technique. In addition, preliminary reports of the clinical use of CO₂ arteriography by other authors^{2,3} have suggested that distal lower extremity vessels are difficult to adequately image, especially when significant arterial occlusive disease is present. Thus, the overall utility of CO₂ arteriography in the management of patients with peripheral vascular disease remains in doubt. To answer this question, patients undergoing CO₂ arteriography at the University of Florida during the last 27 months are reviewed. This review determined whether image quality of arteriograms done using CO₂ gas was sufficient to allow appropriate therapeutic decisions to be made.

MATERIAL AND METHODS

Patients

The use of CO₂ gas as an arterial contrast agent was approved by the Institutional Review Board of the University of Florida and the Subcommittee for Clinical Investigation of the VA Medical Center, Gainesville, Florida, and more than 700 CO₂ arteriograms have been done the last 10 years. One hundred twenty-eight procedures done in 115 patients were reviewed. The mean age

of patients undergoing CO₂ arteriography was 64.3 years (range, 34–83 yr). Concomitant medical illnesses present at the time of arteriography included renal insufficiency (serum creatinine > 1.5 mg/dl) in 70, hypertension requiring therapy with antihypertensive agents in 85, diabetes mellitus in 44, significant coronary artery disease in 62, and significant cerebral vascular disease in 27. Seven of the patients with renal insufficiency were being treated with hemodialysis or peritoneal dialysis at the time of arteriography and five had previously undergone renal transplantation. Fifty-eight of the 115 patients (50.4%) had previously had one or more arterial reconstructive procedures and three had previously undergone cardiac transplantation.

Eighty-one arteriograms were done in 71 patients with symptomatic peripheral arterial occlusive disease (37 studies for severe intermittent claudication, 43 for rest pain or tissue loss, and 1 to assess infrainguinal graft patency). Twenty-four arteriograms were done in 23 patients to evaluate arterial aneurysms (18 abdominal aortic aneurysms, 2 popliteal aneurysms, 4 iliac or femoral pseudoaneurysms). Nineteen renal arteriograms were done in 17 patients with severe hypertension or progressive renal failure potentially due to renal artery stenosis, whereas 4 patients had mesenteric arteriograms done because of symptoms of acute or chronic mesenteric ischemia. Specific reasons for using CO₂ gas as the contrast agent included renal insufficiency in 80 studies in 70 patients, contrast allergy in 22 studies in 20 patients, previous renal transplantation in 5 studies in 5 patients and previous use of a large amount of iodinated contrast in 5 studies in 5 patients. Eleven patients had multiple indications for CO₂ use (12 studies done in 10 patients with both renal insufficiency and contrast allergy, and 1 study done in a patient with renal insufficiency, contrast allergy and a previous renal transplant). The remaining CO₂ arteriograms included in this review were done in 27 patients who did not have specific indications for CO₂ arteriography and were not at increased risk for angiography using standard contrast agents. In twenty-nine of these studies, both iodinated contrast and CO₂ gas were used to allow direct comparison of the two different contrast agents.

Based on results of these arteriograms, ninety subsequent surgical and/or endovascular procedures were done in 82 patients. Thirty-two surgical arterial reconstructions, 15 peripheral endovascular procedures, 6 combined endovascular and surgical reconstructions, and 4 amputations were done in 51 patients with arterial occlusive disease. Thirteen patients had repair of abdominal aortic aneurysms, two repair of popliteal aneurysms, and three repair of iliac or femoral pseudoaneurysms. Four patients had renal artery bypass procedures, seven had renal artery balloon angioplasty (including one who

Address reprint requests to James M. Seeger, M.D., Section of Vascular Surgery, Department of Surgery, Box 100286 JHMHC, Gainesville, FL 32610.

Accepted for publication January 20, 1993.

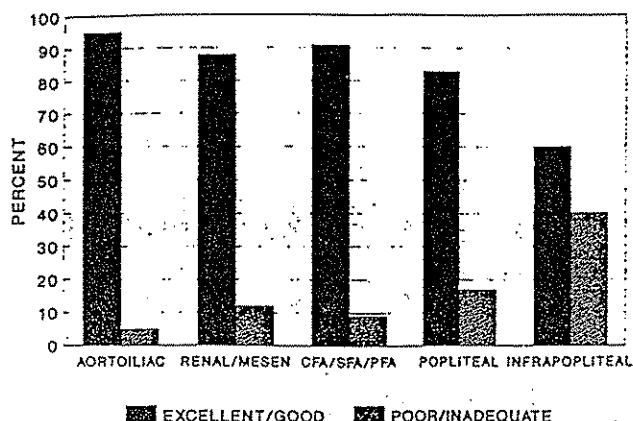
QUALITY OF CO₂ ARTERIOGRAPHIC IMAGES

Figure 1. Percent of CO₂ arteriogram images by location which were graded as either excellent/good or poor/inadequate on blinded review.

also had an iliac artery angioplasty), one had renal artery angioplasty and renal artery bypass surgery, one had a nephrectomy for renal vascular hypertension and/or progressive renal insufficiency. One patient had an aorta to celiac and aorta to superior mesenteric artery bypass for chronic mesenteric insufficiency. Indicated surgical procedures were deferred in nine patients (one of whom had previously had a femoral to tibial artery bypass based on a CO₂ arteriogram) because of severe medical problems that made the risk of the procedures prohibitive. Six patients with diffuse arterial disease who were poor candidates for arterial bypass surgery responded to medical therapy alone and five patients were found on arteriography to be unreconstructable. Eleven patients (including one who had undergone a femoral popliteal bypass based on a CO₂ arteriogram 1 week earlier) were shown by CO₂ arteriography to have no significant arterial disease or bypass graft defects requiring intervention and four patients refused indicated procedures.

Technique of CO₂ Arteriography

After an overnight fast, a bolus of glucagon (0.5 mg) is given to decrease the effects of bowel gas motion. The patient is then positioned supine on a standard arteriographic table and the common femoral or axillary artery is punctured. A 4 Fr arteriographic catheter is introduced and positioned in the appropriate location for the type of study to be done (renal, mesenteric, aortic, infrainguinal). This catheter is then connected to a prototype, dedicated CO₂ gas arterial injector (Angiodynamics, Glen Falls, New York) developed at the University of Florida. This injector is equipped with multiple check valves that ensure a controlled delivery of CO₂ gas volume and prevent "explosive type" delivery of the CO₂

gas. Care is taken to avoid introduction of air during connection of the arteriographic catheter to the CO₂ injector and to ensure that the cylinder from which the CO₂ gas is loaded does not contain water. Water combines with CO₂ gas to produce carbonic acid that could be injected into the patient and water and a large amount of rust have been found in several CO₂ gas cylinders. Because of this, only CO₂ gas from disposable CO₂ cylinders (Medipure Carbon Dioxide, Union Carbide Gases, Linde Division, Danbury, CT) is used.

Fifty to 70 cc of CO₂ gas are delivered at a rate of 140 cc/sec for aortic or renal artery studies while 20–40 cc at 40 cc/sec are used for peripheral arterial studies. Arterial images are then obtained using a 1024 × 1024 pixel DSA system and images are post-processed if needed by compiling multiple digital images into a single composite image using a "stacking" software program (Toshiba America, Tustin, CA). When arterial segments are not adequately imaged in the supine position, the study is repeated with the extremity elevated or with the patient in a Trendelenburg position of 20 to 30 degrees. This is

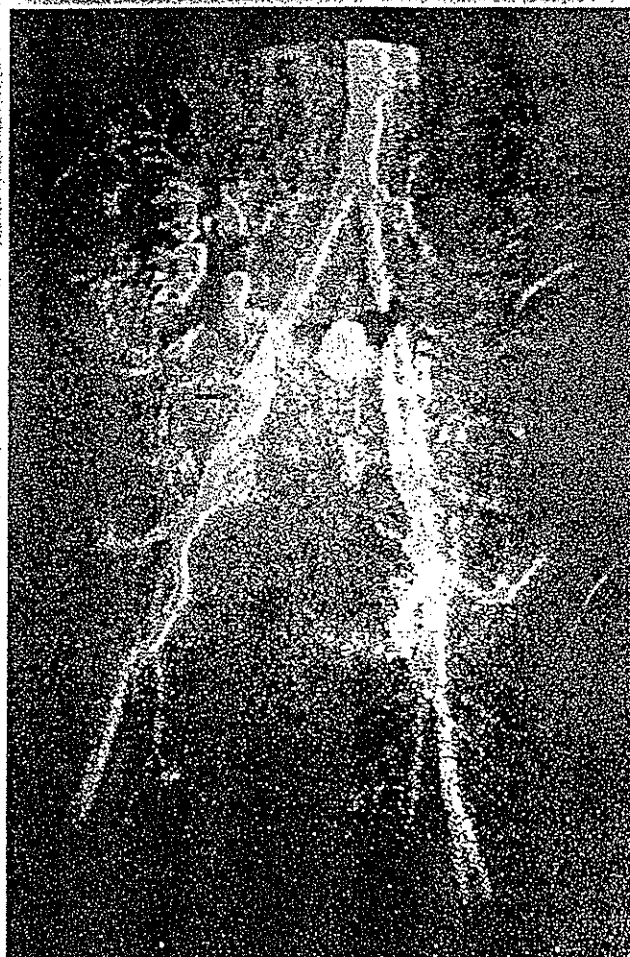


Figure 2. Aortiliac CO₂ arteriogram showing right external iliac artery occlusion (arrow) with common femoral artery reconstitution

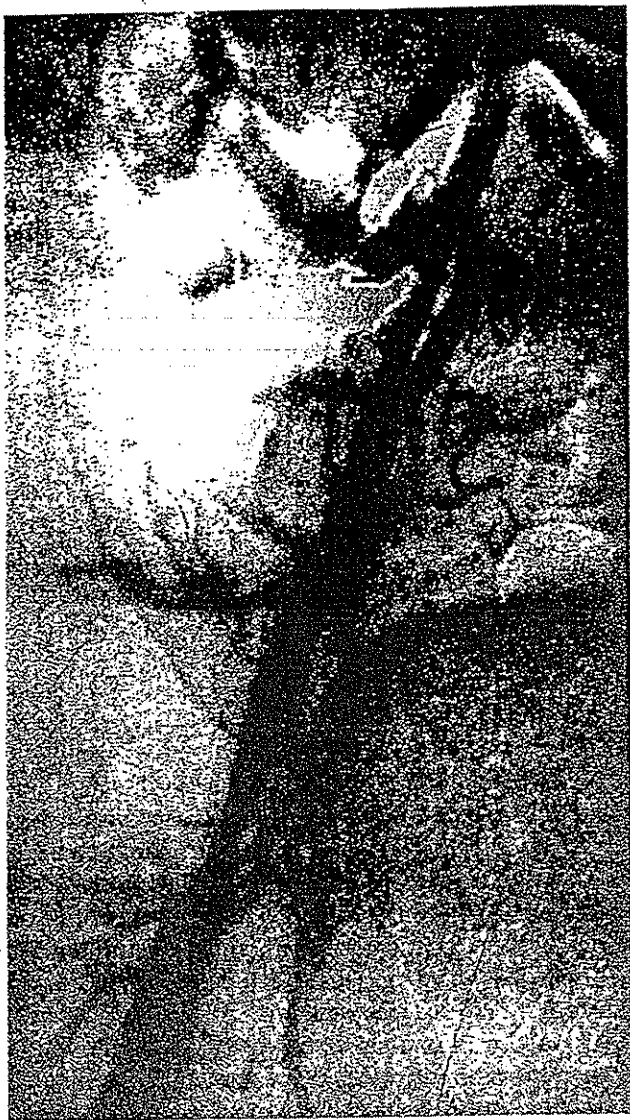

Figure 3. CO₂ arteriogram of the right iliac artery and femoral arteries. An endoluminal stent can be seen in the external iliac artery (arrow)

accomplished by using wedges to elevate the legs or with a specialized tilting arteriographic table. Visualization of renal arteries during CO₂ renal arteriograms is improved by positioning the kidney to be studied above the level of the catheter through which the CO₂ is injected. Injections of CO₂ gas are spaced 2 to 3 minutes apart and the extremities are returned to the horizontal position or the patient to the supine position between injections to improve clearing of the CO₂ from the extremity.

Data Analysis

To determine the accuracy and clinical utility of CO₂ arteriography, CO₂ arteriograms were reviewed in a blinded manner by two vascular surgeons (JMS, TRSH). Images were graded as excellent, good, poor, or inade-

quate with excellent being defined as a complete image of the arterial segment being studied including the first and second order arterial branches and fine detail of the arterial wall, good being an adequate image of the arterial segment involved including the first and second order arterial branches but without visualization of the fine detail of the arterial wall, poor being an adequate image of the arterial segment being studied but without clear imaging of the first or second order arterial branches or the fine detail of the arterial wall and inadequate being defined as an incomplete image of the arterial segment being studied. Image quality and results of arterial imaging using CO₂ arteriograms were compared to results of arteriography using iodinated contrast in those patients who had both studies. Therapeutic plans were then formulated based on the CO₂ arteriograms alone and compared with intraoperative findings, intraoperative pre-bypass arteriography, or subsequent clinical course in those patients in whom arterial reconstructive procedures were not done. Finally, complications directly attributable to CO₂ arteriography and the potential benefit of using CO₂ gas as a contrast agent were determined.

RESULTS

Thirty arteriographic studies were done using CO₂ gas alone while in 61 studies small amounts of dilute iodinated contrast were also used. The amount of iodinated contrast used in these combined CO₂ gas and iodinated contrast studies was 39.5 cc compared with 196.5 cc in the remaining 37 studies in which standard contrast arteriograms were done in addition to CO₂ studies ($p < .05$). In the 70 patients with renal insufficiency, twenty studies were done with CO₂ gas alone and 52 studies were done with CO₂ gas plus a small amount of iodinated contrast. In the 19 patients with contrast allergy, 13 studies were done with CO₂ gas alone and 7 with CO₂ gas plus a small amount of iodinated contrast. In the five patients who had previously undergone renal transplantation, 4 studies were done with CO₂ gas alone and one with CO₂ gas plus a small amount of iodinated contrast. Patients with iodinated contrast allergy were also pretreated with steroids and no contrast hypersensitivity reactions occurred.

One hundred and seventeen of the 128 CO₂ arteriograms (91%) were judged to be of good or excellent quality by the two blinded observers. Only one CO₂ study was found to be completely inadequate. Image quality was best in the aorta, iliac, renal and mesenteric arteries (Figs. 1-4). Image quality declined somewhat in the arteries below the inguinal ligament (Fig. 1); however, 90% or more of images of the common femoral, profunda femoris and superficial femoral arteries were still of good



Figure 4. Left: Renal CO₂ arteriogram showing a severe left renal artery stenosis (arrow). Moderate narrowing can also be seen in the right renal artery. Right: Repeat CO₂ study after success balloon angioplasty of the left renal artery lesion.

or excellent quality (Fig. 5). In contrast, only 83% of popliteal artery images and 60% of infrapopliteal artery images were judged to be good or excellent (Fig. 6). Use of the "stacking program" improved image quality, particularly in the infrapopliteal arteries (Fig. 7). Good or excellent images of infrapopliteal arteries were obtained using CO₂ gas in 69% of infrapopliteal studies in which the "stacking" program was used compared with 47% of studies done without use of this post processing program. In addition, in some patients, use of CO₂ arteriography demonstrated infrapopliteal arterial anatomy better than studies done with standard iodinated contrast agents (Fig. 8).

Agreement between CO₂ arteriograms and arteriograms done using iodinated contrast was seen in 93 of 98 cases (95%). Using iodinated contrast, infrapopliteal arteries were better imaged in four studies and an inferior mesenteric artery stenosis was better demonstrated in one study. Comparison of findings during arterial reconstructive surgery to CO₂ arteriograms revealed more disease than predicted by CO₂ studies (and by iodinated contrast studies) in three patients. In addition, in one patient less disease was found in the aorta than predicted by the CO₂ study, possibly due to inadequate aortic filling by CO₂ gas during a renal arteriogram (Fig. 9).

A therapeutic plan, based on the CO₂ arteriogram alone was possible in 104 of the 128 studies. In eight studies done for occlusive disease, inadequate imaging of the infrapopliteal vessels in seven and of the common femoral artery in one precluded a therapeutic decision. In one additional study done for possible mesenteric arte-

rial disease, motion artifact made digital subtraction arteriography impossible. In the remaining 15 studies, a complete evaluation of the lower extremity arterial tree using CO₂ gas was not done so that a therapeutic decision based on CO₂ arteriography alone could not be derived. These 15 patients all had complete studies using iodinated contrast and CO₂ arteriograms of selected areas of the arterial tree were only done for comparison. Compared with findings at the time of surgery or endovascular procedures and to subsequent clinical follow-up in patients who did not have a reconstructive procedures, therapeutic decisions based on CO₂ arteriography were accurate in all 104 cases in which a therapeutic plan was possible. Thus, accurate therapeutic plans, based on CO₂ studies alone, were possible in 104 of 113 patients (92%) in whom complete CO₂ arteriograms were done.

Complications potentially attributable to CO₂ arteriography were seen in only two patients. One patient with a large abdominal aortic aneurysm and renal insufficiency (serum creatinine 3.5 mg/dl) developed profuse watery diarrhea after a CO₂ arteriogram. He had received 1940 cc of CO₂ gas over a 30-minute period during the study and was thought to have had transient ischemic colitis. The patient recovered from the diarrhea without sequelae and underwent aneurysm repair without further complication. A second patient being evaluated for sepsis and abdominal pain potentially due to acute mesenteric arterial insufficiency suffered a respiratory arrest 30 minutes after an emergency mesenteric CO₂ arteriogram. The patient was severely ill at the time of the arteriogram and subsequently died. Whether the CO₂ arterio-

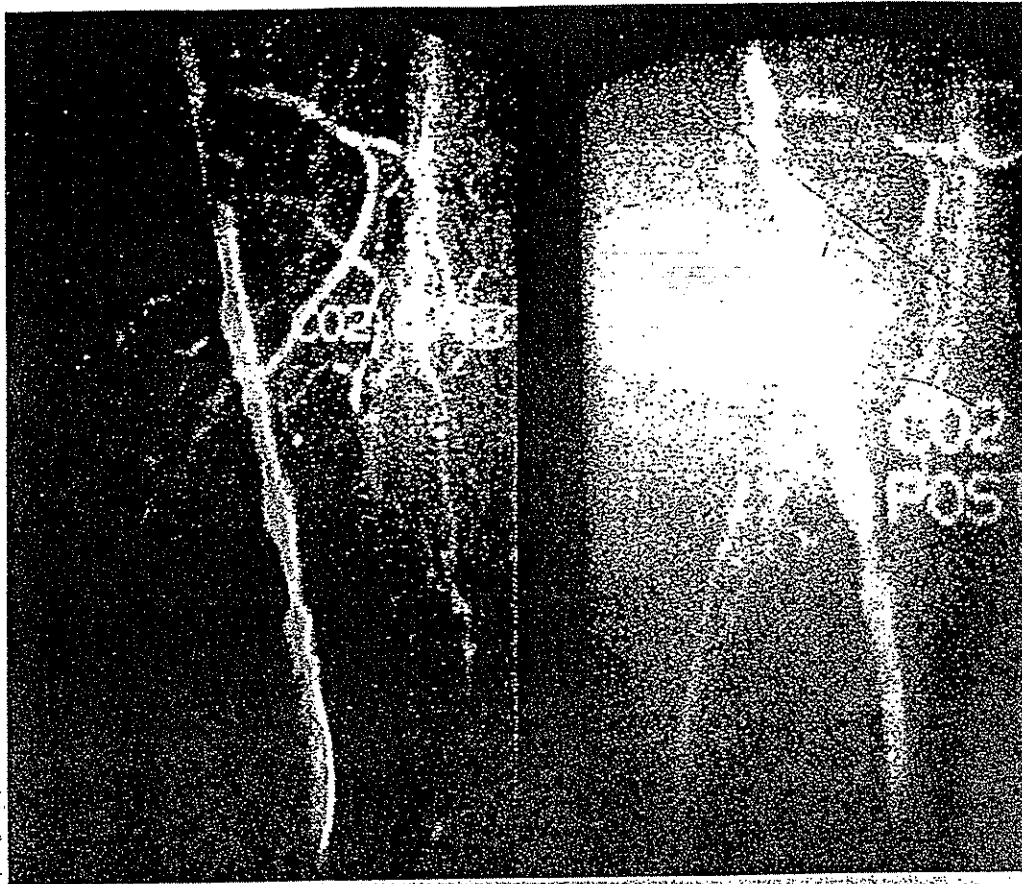

Figure 5. Left: CO₂ arteriogram of severe, focal left superficial femoral artery stenosis (arrow) and significant disease in the remainder of the artery. Second and third order branches of the artery as well as fine luminal detail are easily seen. Right: Repeat CO₂ study after success balloon angioplasty of the focal stenosis.

gram actually contributed to the respiratory arrest is unclear as sufficient time for clearance of the injected CO₂ gas had elapsed before the arrest and arterial blood gases were not done in the interval between the arteriogram and the arrest.

A rise in serum creatinine after arteriography was seen in seven patients, all of whom also received iodinated contrast. Increased renal insufficiency was likely due to complications of renal balloon angioplasty in two of these patients, to worsening nephrotic syndrome in one patient, and to dehydration secondary to diarrhea associated with ischemic colitis in one patient. In two of the other three patients, the increase in serum creatinine was only seen at 2 and 8 weeks after the arteriogram. Thus, no patients had a rise in serum creatinine after arteriography using CO₂ gas alone and only one patient (0.8% overall, 1.3% of those with renal insufficiency) potentially had contrast-induced nephrotoxicity after arteriography using CO₂ gas plus a small amount of iodinated contrast.

Eighty-eight patients in this study could have benefited from the use of CO₂ gas as a contrast agent for

arteriography because they had a relative contraindication to standard arteriography using iodinated contrast. Complications potentially attributable to CO₂ arteriography occurred in two of these patients and one additional patient potentially had contrast-induced nephrotoxicity as described. In addition, therapeutic decisions could not be made based on CO₂ arteriograms alone in seven patients. However, only small amounts of contrast were required to complete the arteriograms in these seven patients. Thus, use of CO₂ gas as an arterial contrast agent likely reduced the risk of arteriography in 78 of the 88 patients (89%) and may have decreased that risk in up to 85 patients (97%).

DISCUSSION

Severe hypersensitivity reactions associated with arteriography using iodinated contrast agents occur in approximately 1 in 1000 studies^{4,5} and death due to contrast hypersensitivity is estimated to occur in between one in 12,000 and one in 75,000 procedures.^{4,6} The incidence of contrast-induced hypersensitivity reactions increases

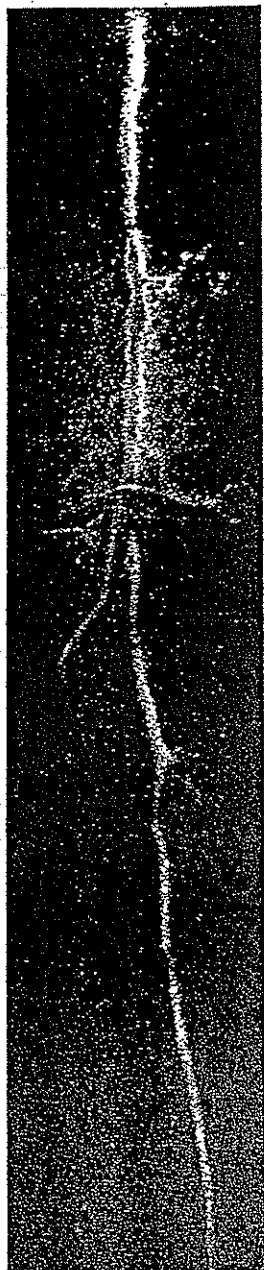

Figure 6. Popliteal and infrapopliteal CO₂ arteriogram showing popliteal artery occlusion (arrow), tibial peroneal trunk stenosis, a patent peroneal artery of good caliber and occlusion of both the anterior and posterior tibial arteries.

with the amount of contrast used⁷ and in patients with a history of contrast allergy, approaches 25% when ionic contrast is used.⁸ Introduction of non-ionic contrast and pre-treatment of patients with steroids has reduced but not eliminated this risk.^{7,8}

Acute renal dysfunction after arteriography has been reported by Martín-Paredero et al.⁹ to occur in 11.3% of 400 patients undergoing peripheral arteriography for occlusive or aneurysmal peripheral vascular disease. They

also found contrast-induced renal insufficiency in 41.7% of patients with pre-existing abnormal renal function. Hall et al.¹⁰ found that the risk of contrast-induced nephrotoxicity increased as the baseline serum creatinine increased, with 2% of patients with a serum creatinine < 1.2 mg/dl, 10% of patients with a serum creatinine between 1.3 and 1.9 mg/dl and 62% of patients with a serum creatinine greater than 2.0 mg/dl developing acute renal dysfunction after arteriography using ionic contrast. Interestingly, Parfrey et al.¹¹ did not find an increased risk of contrast-induced nephrotoxicity in patients with diabetes mellitus unless pre-existing renal insufficiency was present. Animal studies have suggested that non-ionic contrast agents are less nephrotoxic¹² but Schwab et al.¹³ in a randomized, controlled clinical trial of arteriography using ionic and nonionic contrast agents could not confirm this. Unfortunately, contrast-induced renal insufficiency is not always transient and both Gomes et al.¹⁴ and Martín-Paredero et al.⁹ have reported permanent renal failure requiring dialysis due to contrast induced nephrotoxicity.

The potential of CO₂ arteriography to essentially eliminate contrast-induced hypersensitivity reactions and nephrotoxicity is demonstrated by the study presented here. No allergic reactions were seen in any of the 115 patients studied, including the 21 patients with a history of contrast allergy. Similarly, despite pre-existing renal insufficiency in 70 of 115 patients, a transient increase in serum creatinine potentially due to contrast induced nephrotoxicity was seen in only one patient. Although arteriography using CO₂ gas alone was not possible in all patients, even in those in whom iodinated contrast was necessary, use of CO₂ gas significantly reduced the amount of iodinated contrast used to complete the study, which likely reduced the risk of hypersensitivity reaction and nephrotoxicity.

That CO₂ gas can be used as an intravascular contrast agent without risk of gas embolism has previously been demonstrated. Intravenous injection of CO₂ gas in doses of 100 to 200 cc was used commonly in the past for the detection of pericardial effusion¹⁵⁻¹⁸ and thousands of patients were studied without reported complications. In addition, previous animal studies have demonstrated that injection of up to 3 cc per pound of CO₂ gas into either a peripheral vein¹⁹ or a pulmonary vein²⁰ does not cause gas embolism. CO₂ gas is 20 times more soluble in blood than oxygen and rapidly combines with blood buffers, facilitating its transport to the lungs where it is eliminated.²⁰ Peripheral arterial injection of CO₂ gas for arteriography also has the added safety factor of at least one and usually two (including the lung) capillary beds through which the gas must pass before reaching the coronary or cerebral circulation which further reduces the likelihood of gas embolism. Experience with injection of

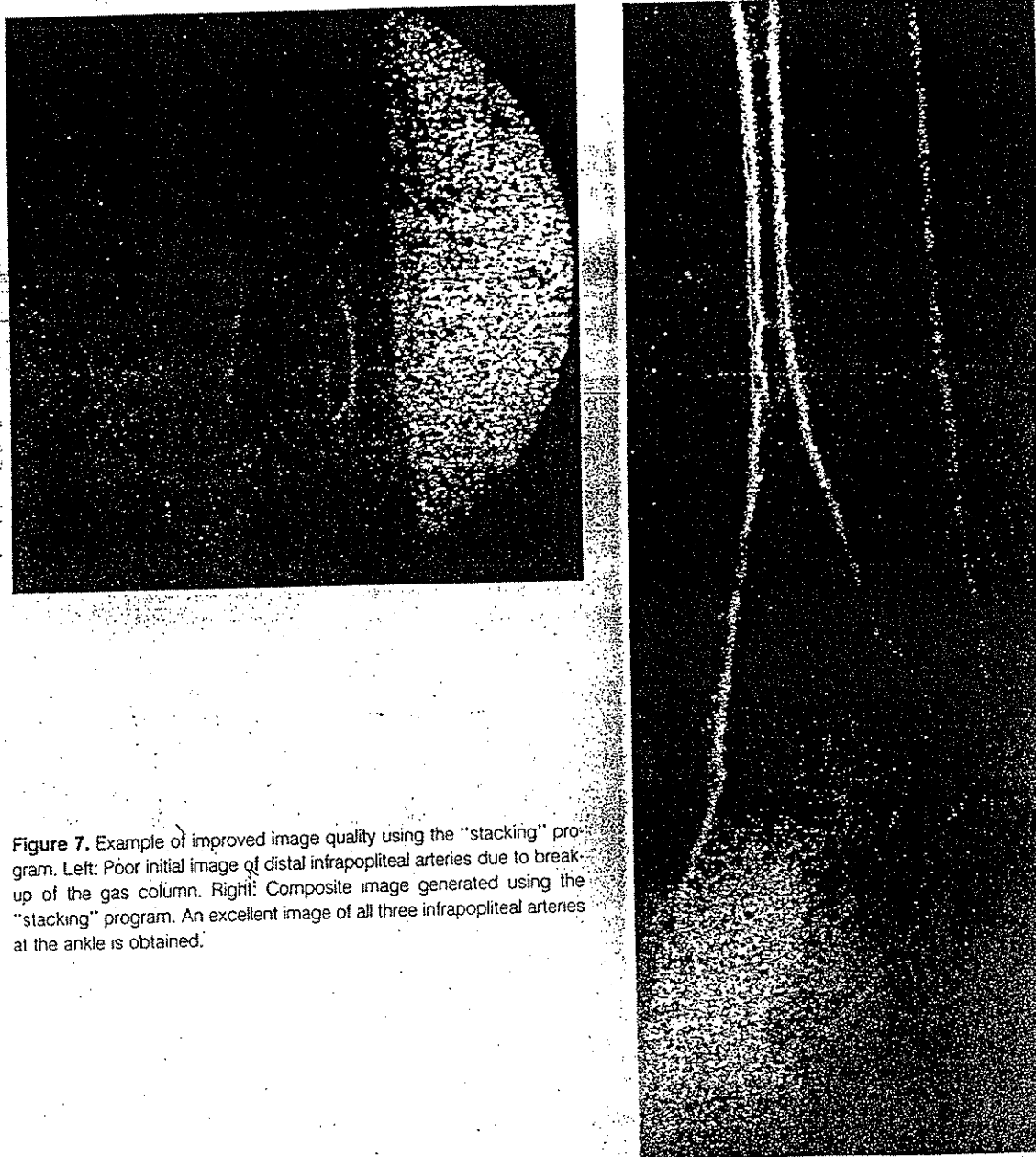


Figure 7. Example of improved image quality using the "stacking" program. Left: Poor initial image of distal infrapopliteal arteries due to break-up of the gas column. Right: Composite image generated using the "stacking" program. An excellent image of all three infrapopliteal arteries at the ankle is obtained.

CO₂ gas for peripheral arteriography in more than 700 patients at our institution has confirmed this as no evidence of gas embolism has been seen.

The only patient (of the entire group of more than 700 patients undergoing CO₂ arteriography at the University of Florida) who sustained a complication clearly attributable to CO₂ gas injection has been the patient reported here who developed transient ischemic colitis. This complication was likely due to trapping of a large amount of CO₂ gas in a large infrarenal aortic aneurysm which then formed a "vapor lock" in the inferior mesenteric artery.

Trapped CO₂ gas can also exchange with tissue nitrogen gas, potentially leading to embolization of insoluble nitrogen bubbles. Because of this, repeated injection of CO₂ gas should not be done when trapping of CO₂ gas within an aneurysm or any other part of the arterial system is observed. In addition, CO₂ arteriography should not be done in patients with severe respiratory compromise unless blood gases are obtained frequently during the procedure as patients with high arterial pCO₂ values (suggesting difficulty in eliminating CO₂ gas) may be at risk from this procedure.

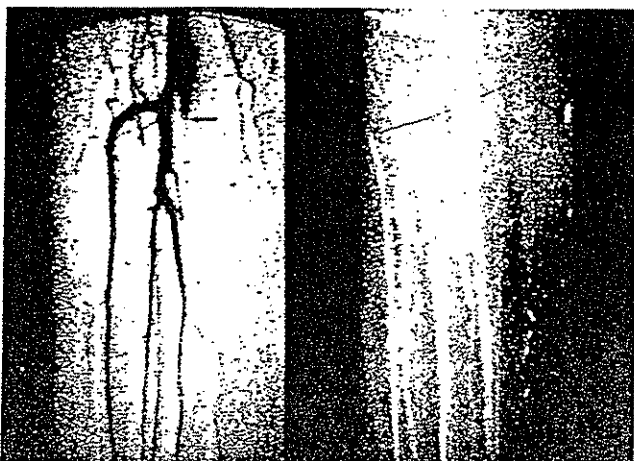


Figure 8. Left: Distal popliteal and infrapopliteal arteriogram done using iodinated contrast showing apparent occlusion of a popliteal to posterior tibial artery bypass (arrow). Right: Repeat study done with CO₂ gas as the contrast agent showing a patent graft (arrow). Flow into the graft was very slow due to a distal graft stenosis which prevented demonstration of the graft using standard iodinated contrast.

CO₂ gas also is not used for cerebral arteriography or aortic studies above the diaphragm in our institution because of the risk of neurotoxicity. In a previous animal study from the University of Florida,²² significant neurologic deficits were seen in rats after direct injection of CO₂ gas into the carotid arteries. Histologic examination of brain tissue revealed multi-focal ischemic infarction and disruption of the blood brain barrier. The quantity of cerebral tissue infarcted roughly parallel the amount of CO₂ gas injected. In contrast, Shifrin et al.²³ has reported that injection of 3–5 cc of CO₂ gas/kg into the aortic arch and carotid arteries of dogs was associated with no electroencephalographic changes during the procedure and no immediate or long-term neurologic deficits. However, until the question of neurotoxicity of CO₂ gas is resolved, injection of CO₂ gas in any situation in which the cerebral circulation could be exposed to gas should be avoided.

As one of the principal indications for CO₂ arteriography is renal insufficiency, the effect on renal function of direct CO₂ gas injections into renal arteries has also been carefully investigated in animals. Large volumes of CO₂ gas were injected into the renal arteries of dogs and no decrease in renal blood flow or renal function (as measured by ^{99m}Tc dimercaptosuccinic acid and ¹³¹Iodine sodium iodohippurate (Hippuran scans) was seen within 24 hours after CO₂ injection (IF Hawkins, Jr. unpublished data). In addition, no microscopic changes in the endothelium of the major renal arteries or in the glomeruli were seen by scanning or transmission electron microscopy when studies were done with the animal supine. Only when the kidney was positioned vertically

above the injection site in three animals were changes compatible with minimal acute tubular necrosis seen by transmission electron microscopy. A preliminary ultrasound study demonstrates that if the kidney is vertically oriented, a period of approximately 2 minutes after injection is required for CO₂ gas to clear from the cortex of the kidney. In contrast, when the kidney is positioned horizontally, the CO₂ gas completely clears from the kidney in approximately 30 seconds. Because of this, our current practice is to return the patient to a prone position between CO₂ injections immediately after filming.

Thus, use of CO₂ gas as a contrast agent for peripheral arteriography appears to be safe. However, for this new type of peripheral arterial imaging to be useful, arterial images must be of sufficient quality to allow accurate therapeutic planning in patients with peripheral vascular disease. Greater than 90% of CO₂ arterial images blindly reviewed by two vascular surgeons in this study were thought to be of good or excellent quality and agreement between results of CO₂ arteriograms and studies obtained with iodinated contrast was seen in 95% of cases. More significant, accurate therapeutic plans were possible in 92% of cases. The principal drawback with the clinical use of CO₂ arteriography in this study, as in previously reported studies from other institutions,^{2,3} was difficulty with imaging of infrapopliteal arteries. Use of the "stacking program" has improved results of infrapopliteal artery imaging and in contrast to the results reported by Weaver et al.,³ imaging of infrapopliteal arteries distal

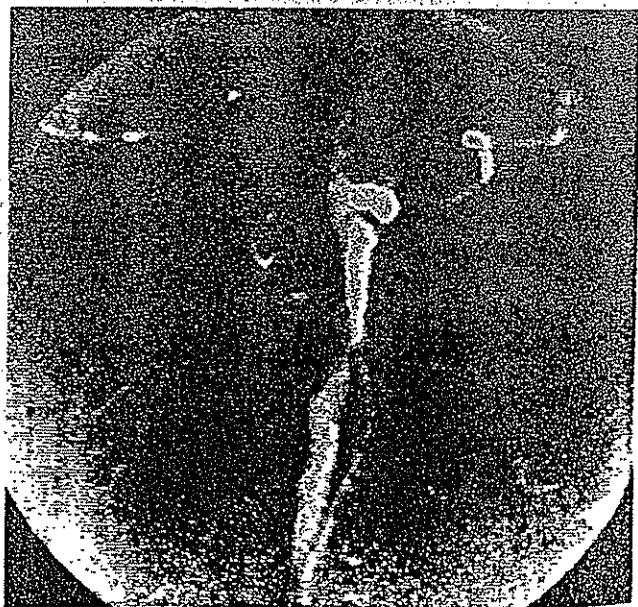


Figure 9. Aortic and renal CO₂ arteriogram showing a severe right renal artery stenosis and what appears to be a large plaque on the right side of the aorta at the level of the right renal artery (arrow). The renal artery stenosis was confirmed during renal bypass surgery but the aorta was found to be relative free of disease.

to significant superficial femoral or popliteal artery occlusive disease is now possible in almost 70% of cases. Further refinements with positioning and use of better DSA equipment may further enhance these results.

Thus, CO₂ arteriography appears to provide good to excellent images upon which accurate therapeutic decisions can be based in the great majority of patients studied using this new modality. Because CO₂ arteriography is safe and essentially eliminates the risks associated with injection of either ionic or non-ionic iodinated contrast agents, greater than 90% of patients undergoing CO₂ arteriograms benefit from the procedure. New developments with computer software and imaging techniques will likely further improve results of CO₂ arteriography and as CO₂ is a cost-effective contrast agent, the benefits of CO₂ arteriography in patients with peripheral vascular disease are significant.

References

- Hawkins IF. Carbon dioxide digital subtraction arteriography. *AJR* 139:19-24, 1982.
- Miller FJ, Mineau DE, Koehler PR, et al. Clinical intra-arterial digital subtraction imaging. *Radiology* 1983; 148:273-278.
- Weaver FA, Pentecost MJ, Yellin AE, et al. Clinical applications of carbon dioxide/digital subtraction arteriography. *J Vasc Surg* 1991; 13:266-273.
- Ansell G, Tweedie MCK, West CR, Evans P, Couch L. The current status of reactions to intravenous contrast media. *Invest Radiol* 1980; 15:suppl:S32-S39.
- Shehadi WG, Toniolo G. Adverse reaction to contrast media: a report from the committee on safety of contrast media of the International Society of Radiology. *Radiology* 1980; 137:299-302.
- Hartman GW, Hattery RR, Witten DM, Williamson B Jr. Mortality during excretory urography: Mayo Clinic experience. *AJR* 1982; 139:919-922.
- Lasser EC, Berry CC, Talner LB, et al. Pretreatment with corticosteroids to alleviate reactions to intravenous contrast material. *N Engl J Med* 1987; 317:845-849.
- Katayama H, Yamaguchi K, Kozuka T, et al. Adverse reactions to ionic and nonionic contrast media: a report from the Japanese Committee on the safety of contrast media. *Radiology* 1990; 175:621-628.
- Martin-Paredero V, Dixon SM, Baker JD, et al. Risk of renal failure after major arteriography. *Arch Surg* 1983; 118:1417-1420.
- Hall KA, Wong RW, Hunter GC, et al. Contrast-induced nephrotoxicity: the effects of vasodilator therapy. *J Surg Res* 1992; 53:317-320.
- Parfrey PS, Griffiths SM, Barrett BJ, et al. Contrast material-induced renal failure in patients with diabetes mellitus, renal insufficiency, or both: a prospective controlled study. *N Engl J Med* 1989; 320:143-149.
- Katzberg RW, Morris TW, Lasser EC, et al. Acute systemic and renal hemodynamic effects of meglumine/sodium diatrizoate 76% and iopamidol in euvolemic and dehydrated dogs. *Invest Radiol* 1986; 21:793-797.
- Schwab SJ, Hlatky MA, Pieper KS, et al. Contrast nephrotoxicity: a randomized controlled trial of a nonionic and an ionic radiographic contrast agent. *N Engl J Med* 1989; 320:149-153.
- Gomes AS, Baker JD, Martin-Paredero VM, et al. Acute renal dysfunction after major arteriography. *AJR* 1985; 145:1249-1253.
- Scatliff JH, Kummer AJ, Janzen AH. Diagnosis of pericardial effusion with intracardiac carbon dioxide. *Radiology* 1959; 73:871-883.
- Meltzer RS, Serruys PW, Hugenholz PG, Roelandt J. Intravenous carbon dioxide as an echocardiographic contrast agent. *J Clin Ultrasound* 1981; 9:127-131.
- Turner AF, Meyers HI, Jacobson G, Lo W. Carbon dioxide cineangiography in the diagnosis of pericardial disease. *AJR* 1966; 97:342-349.
- Phillips JH Jr., Burch GE, Hellinger R. The use of intracardiac carbon dioxide in the diagnosis of pericardial disease. *Am Heart J* 1961; 61:748-755.
- Oppenheimer MJ, Durant TM, Stauffer HM, et al. *In vivo* visualization of intracardiac structures with gaseous carbon dioxide. *Am J Physiol* 1956; 186:325-334.
- Moore RM, Braselton CW, Jr. Injections of air and carbon dioxide into a pulmonary vein. *Ann Surg* 1940; 112:212-218.
- Burko H, Klatte EC. Renewed interest in gases for contrast roentgenography. *Am J Radiol* 1967; 99:645-659.
- Coffey R, Quisling RG, Mickle JP, Hawkins IF Jr., Ballinger WB. The cerebrovascular effects of intraarterial CO₂ in quantities required for diagnostic imaging. *Radiology* 1984; 151:405-410.
- Shifrin EG, Plich MB, Verstandig AG, Gomori M. Cerebral angiography with gaseous carbon dioxide CO₂. *J Cardiovasc Surg* 1990; 31:603-606.

Discussion

DR. ROBERT B. SMITH, III (Atlanta, Georgia): We have performed a limited number of CO₂ angiograms at Emory over the years compared with the extensive experience of Dr. Seeger and his colleagues at the University of Florida. I have had the opportunity to visit their unit and they have a most impressive setup. Our radiologists have observed some of the same technical problems to which Dr. Seeger has alluded. Compressibility of the CO₂ gas leads to sudden injection of the bolus with rapid dissipation of the image in some patients. Anteriorly located vessels fill best requiring careful positioning of the patient and ideally the availability of a tiltable x-ray table. Cerebral toxicity is a definite risk with this method. We have had one patient who developed a temporary global neurologic deficit after CO₂ injection into the abdominal aorta. These relative disadvantages can be more than balanced by the obvious benefits of CO₂ angiography in patients with known severe contrast allergy or preexisting renal insufficiency. In addition, CO₂ is inexpensive compared with iodinated contrast agents. Expanded application of MR angiography perhaps supplemented by a more liberal use of CO₂ imaging in selected patients will eventually completely replace iodinated contrast angiography as the preferred method of study in vascular patients. In patients judged to have unreconstructible infra-inguinal disease by CO₂ angiography, do you routinely confirm that impression by contrast angiography using iodinated agents before concluding that the patient is not a candidate for revascularization? Is it feasible to perform renal and visceral transluminal balloon angioplasty using CO₂ techniques alone? What are the costs of CO₂ angiography versus standard contrast studies in your center, and also the time required for the two procedures?

DR. WILLIAM H. EDWARDS (Nashville, Tennessee): As with many other areas of new technology, it takes not only an enthu-

siastic physician but someone in the manufacturing business with a profit in mind to allow the technology to advance. This obviously is not the case with Dr. Hawkins and his pioneering efforts in CO₂ angiography as the CO₂ is fairly cheap. In his review, Dr. Seeger went back over 27 months to try to determine the efficacy of CO₂ angiography and on the basis of the arteriograms that he reviewed, was able to make a decision in retrospective manner as to therapy that might be offered, and he found it to be the case in a high percentage of cases. Because the CO₂ angiograms were used in a select group of patients, that is, those that were felt to be sensitive to iodinated contrast or had renal insufficiency, a fairly select group. Those with iodinated contrast that were used along with the CO₂ angiograms did have elevation of their serum creatinine as he indicated; however, those patients also had other procedures such as balloon angioplasty, and intrinsic renal disease as he mentioned. With the expanding population and the instance of renal artery occlusive lesions and renal insufficiency, techniques such as CO₂ angiography offer us a wonderful chance to perform the necessary arteriograms to try to determine if they are lesions that we might correct to allay the apprehensions of nephrologists. As a vascular surgeon who has remained active in the field of arteriography, I believe the application of CO₂ angiography will be best used in those patients with renal insufficiency. Hypersensitivity to contrast, including hives, can usually be well controlled with steroids, Benadryl, and Tagamet. The rare case of anaphylaxis can be a major problem. In the last 15 years in 40,000 arteriograms we have not had a severe anaphylactic reaction. How many times was there a failure of a planned CO₂ angiogram requiring a conventional iodinated or noniodinated contrast to replace it? In previous discussions Dr. Seeger has alluded to the technical problems that can be encountered with CO₂ angiography. Would he elaborate a little bit on this? Have these technical problems been overcome and is this a technique that might be available to more centers as they become interested? He showed on one of his slides and he mentions in his manuscript as one of the advantages of CO₂ angiography vessel injuries from arteriograms. Exactly what is different in the CO₂ angiogram that might allow you to make that statement?

DR. JAMES M. SEEGER (Closing Discussion): To deal with the questions about the cost of CO₂ arteriography compared

with standard contrast arteriography, the cost is basically the same for the technical component of the procedure but the contrast costs are different. One tank of disposable CO₂ gas costs about \$20.00 and you can do a number of studies with this really, up into 40 or 50 studies. Compare that to the cost of the nonionic contrast that costs \$1.00 per cc and the usual dosage for a standard contrast arteriogram which is around 200 cc of dye, and you can see the cost differential. Do we confirm unreconstructible disease shown by CO₂ arteriography with contrast? In the early part of the experience with CO₂ arteriograms that was a routine procedure. At this point, particularly if it is a good study that is well shown with the addition of the computer stacking program, our confidence in CO₂ arteriography is such that, particularly in those patients with severe renal insufficiency, that is not done. That is further strengthened by the comparison in this study to findings at surgery in essentially all of these patients. We commonly explore people who look like they may be unreconstructible and our intraoperative findings and intraoperative arteriograms showed that to be the case. The second question was regarding the value of CO₂ arteriography in renal and visceral arteriography. This is one of the more common uses of CO₂ arteriography in our institution. Renal artery studies are easy to obtain with good positioning and CO₂ can be used as a control for balloon angioplasty in these studies. What about the failure of the CO₂ arteriograms? What causes the failure? In general, it is two things. One is motion artifact since this is the digital subtraction technique and when patients move, digital subtraction techniques cannot be used. Secondly, it is the breakup of the CO₂ gas as it travels distally as I showed. Stacking has helped in that and now particularly with vessels of the ankle, we are obtaining studies in probably about 90 to 95% of cases. There still are a few cases in which you can not study. Interestingly, even if you do not get a complete study, you can markedly reduce the amount of contrast that is used. In the studies in which we had to use contrast as well as CO₂, we only had to use approximately 30 cc of dye compared with the standard contrast arteriogram which requires 200 cc. What about vessel injury? CO₂ can be injected through very small catheters. Arteriograms are routinely performed through #3 French catheters, which is the size of an 18-gauge needle or smaller. It is easier to do these on an outpatient basis and this potentially could reduce the risk of vessel injury.