

Current status of carbon dioxide angiography



Mel J. Sharafuddin, MD, and Anna E. Marjan, MD, Iowa City, Iowa

ABSTRACT

Objective: Unfamiliarity of endovascular surgeons with carbon dioxide (CO₂) angiography is one of the main reasons for its limited use. This review is intended to familiarize the reader with the principles and applications of that modality.

Methods: We conducted a comprehensive review of contemporary literature related to CO₂ angiography and its use in the field of vascular and endovascular surgery, including technical details and diagnostic and interventional applications.

Results: Cardinal physicochemical characteristics of CO₂ include buoyancy, ultralow viscosity, and nonmixing with blood. Because of the risk of neurotoxicity, intra-arterial CO₂ angiography should only be performed below the diaphragm. Venous CO₂ angiography can be performed anywhere in the torso and extremities. Ultralow viscosity enables intra-procedural imaging during vascular interventions without the need to exchange for an angiographic catheter. Benefits, advantages, and emerging applications of CO₂ angiography are listed. Potential complications and their avoidance and troubleshooting are discussed.

Conclusions: CO₂ holds promise as an effective and versatile angiographic contrast agent. It is also a valuable modality for the guidance of endovascular interventions. Current availability of easy to use, safe, and portable CO₂ delivery systems will likely expand the use of that modality even beyond the traditional indications of renal insufficiency and iodinated contrast allergy. (*J Vasc Surg* 2017;66:618-37.)

Since the discovery of x-rays, it became obvious that enhancement of the subtle differences in density is essential to delineate the borders of various soft tissue structures. The discovery of iodine as a safe contrast agent allowed research on iodinated contrast media (ICM) to begin, and in 1924, Brooks¹ described the first known clinical use of sodium iodine as a contrast agent in lower extremity angiograms, which was used to guide the level of amputation in patients with peripheral vascular disease. Over the years, contrast angiography evolved solely as a positive-contrast technique using almost exclusively ICM, a trend that continues to date.

The attributes of carbon dioxide (CO₂) as a negative contrast agent were recognized several decades ago.² Its wide availability, low cost, nontoxicity, and rapid tissue clearance rendered this agent a natural choice as a negative contrast agent in a variety of nonvascular imaging applications such as cisternography, peritoneography, and double-contrast gastrointestinal (GI) imaging. The safety of CO₂ over other gases is attributed to its much higher tissue solubility, virtually eliminating the risk of serious complications from inadvertent gas embolism.

Irvin F. Hawkins, widely acknowledged as a pioneer of modern CO₂ angiography, described how an error led him to realize the potential of this technique when he inadvertently injected air into the celiac artery, luckily without ill consequences.³ This experience, coupled with his knowledge of the safety of CO₂ as an intravenous contrast agent, led him to postulate CO₂ as a potential negative contrast agent in the arterial system. His early experience marked the beginning of this new approach for intravascular imaging, and since then, the work of Hawkins and many other pioneers has enabled the current status of CO₂ as a safe and highly versatile intravascular contrast agent.

The two obvious indications of CO₂ angiography are high-risk state for iodinated contrast-induced nephropathy (CIN) and iodinated contrast allergy. However, many other indications exist, including applications where CO₂ may outperform ICM.

Despite the recognized value of CO₂ angiography among interventional radiologists and angiographers, it has been slow to make its way into the toolbox of the vascular surgeon. This is likely a result of unfamiliarity, because CO₂ angiography is not a readily disseminated skill in vascular training programs. CO₂ angiography has not been standardized as a discipline, and the way it is performed varies depending on the operator and the application. There is also an exaggerated fear of complications and an unfounded assumption that it is time consuming and produces inferior-quality imaging.

This review is intended to better familiarize the reader with the technique of CO₂ angiography by introducing the key physical and chemical features contributing to the value of CO₂ as a contrast agent and how they can be used to optimize imaging in various applications. We will introduce the methods and approaches used

From the Department of Surgery, The University of Iowa Roy and Lucille Carver College of Medicine.

Author conflict of interest: none.

Correspondence: Mel J. Sharafuddin, MD, Department of Surgery, The University of Iowa Roy and Lucille Carver College of Medicine, 200 Hawkins Dr, Iowa City, IA 52242 (e-mail: mel-sharafuddin@uiowa.edu).

The editors and reviewers of this article have no relevant financial relationships to disclose per the JVS policy that requires reviewers to decline review of any manuscript for which they may have a conflict of interest.

0741-5214

Copyright © 2017 by the Society for Vascular Surgery. Published by Elsevier Inc. <http://dx.doi.org/10.1016/j.jvs.2017.03.446>

for CO₂ angiography and define its indications, risks, benefits, and applications where it can be of value. We will introduce the current imaging and technical details that assist the operator in obtaining excellent image quality. We will also describe the value of CO₂ as a contrast agent during a growing number of interventional procedures and explore future trends and potential of CO₂ in a variety of imaging and interventional applications.

METHODS

A comprehensive search of the United States (U.S.) National Library of Medicine related to CO₂ angiography and its use in the field of vascular surgery was conducted via PubMed. To ensure that pertinent studies were not missed, broad search terms were used: "CO₂ angiography," "carbon dioxide angiography," and "non-contrast angiography." Other search terms were "risks of" and "contrast induced nephropathy." The publications ranged in date from 1924 to present, with most of the research published in the last 10 years. Selected publications included reviews, case studies, and clinical trials.

RESULTS

The search term "carbon dioxide angiography" yielded 817 publications. The search was further refined by selecting English language publications. Publications were selected based on their relevance to the topic of discussion and on the quality of the study.

The retrospective review and publication of clinical data on all patients in this report was approved by our Institutional Review Board.

DISCUSSION

CO₂ as an alternative ICM

The most recognized indication for the use of CO₂ as an alternative to ICM is in patients at high-risk of CIN. This serious complication is the third-leading cause of hospital-acquired renal failure⁴ and carries a severalfold increase in short-term and long-term mortality. The incidence of CIN varies widely depending on the definition used, patient risk factors, route and rate of administration, and amount of contrast used. CIN usually manifests ~48 to 72 hours after administration of intravenous ICM. Suspected pathophysiology is generation of reactive oxygen species as a result of renal vasoconstriction/ischemia or direct tubular injury. Of the many approaches suggested to prevent CIN, current evidence seems to support only hydration as a protective countermeasure. The evidence for administration of N-acetylcysteine or bicarbonate infusions in the perioperative period has been less convincing, although many providers continue to use them in practice.

Established risk factors for CIN include pre-existing renal insufficiency, diabetes mellitus, dehydration, cardiovascular disease with congestive heart failure,

smoking, current use of calcium channel blockers or diuretics, advanced age (≥ 70 years), multiple myeloma, hypertension, and hyperuricemia.⁴ Vascular patients represent a population at high risk for developing CIN. Evidence from prospective clinical trials has consistently shown diabetes mellitus and baseline renal insufficiency are the most significant independent risk factors, both of which are highly prevalent in the vascular patient population.

Although the cutoff level of renal dysfunction to prompt the use of an alternative contrast medium is not uniformly defined, avoidance of extrinsic risk factors, such as use of nephrotoxic agents, in this high-risk population should be a high priority. This highlights the need for alternative non-nephrotoxic contrast media for diagnostic and interventional vascular applications. CO₂ can fulfill both roles, and some investigators have even advocated for its routine use during angiography.⁵

The second most common indication for CO₂ angiography is a known allergy to contrast media. Allergic contrast reactions range from mild rash to anaphylaxis. Pretreatment protocols have been developed to lower the incidence and severity of these reactions; however, there are many patients who would benefit from complete avoidance of ICM, especially in situations where immediate angiography is needed and in patients with history of anaphylaxis.

Another indication for CO₂ angiography is specific applications where CO₂ actually outperforms conventional ICM. As described under "Physical and chemical properties of CO₂," certain characteristics of CO₂ can allow better diagnostic information in certain specific applications. For example, improved demonstration of collateral pathways and reconstituted vessels distal to obstructions, demonstration of occult sites of GI bleeding, and visualization of portal-splanchnic veins can be attributed to the ultralow viscosity of CO₂, whereas enhanced vascular filling during central venography is attributed to nonmixing and volume displacement characteristics of CO₂.

Intraprocedural guidance during endovascular interventions is another often overlooked capability of CO₂ angiography, such as during balloon angioplasty and stenting of mesenteric and renal arteries, aortoiliac and lower extremity peripheral vascular occlusive disease, fine-needle transjugular intrahepatic portosystemic shunt (TIPS), embolization therapy, and endovascular abdominal aortic aneurysm (AAA) repair (EVAR).⁶⁻⁹ The use of CO₂ during interventions allows unlimited on-demand intraprocedural angiographic guidance. In addition, CO₂ angiography allows accurate device positioning without the multiple exchanges by injecting CO₂ through the interventional sheath. This is possible owing to the low viscosity of CO₂, which enables it to be injected with little resistance through the small space around the guidewire or interventional device catheter.

Role of CO₂ in lowering the risk of CIN

Lowering the risk of CIN during endovascular interventions, through minimizing the use of ICM while maintaining optimal diagnostic imaging and angiographic guidance, is a challenging task. An ideal approach should address patient-related risk factors, such as requirement of a large ICM dose, intra-arterial administration, and also risk factors specific to a procedure. For example, in complex aortic endovascular interventions such as fenestrated/branched EVAR, renal injury can result both from prolonged renal artery hypoperfusion and embolic events and can be compounded by a CIN.¹⁰ Minimizing the risk for CIN in complex aortic endovascular procedures is considered a high priority because acute kidney injury has been shown to be highly predictive of death in these procedures.¹¹

Strategies aimed at lowering the risk of CIN include optimal reliance on nonradiographic imaging modalities, rationing ICM use, and the use of alternative contrast media, primarily CO₂. In patients at high risk for CIN, it is crucial that alternative diagnostic imaging modalities be considered as a prelude to surgical or endovascular intervention. Duplex ultrasound imaging is the most useful imaging modality in the noninvasive characterization of vascular disease without the use of ICM and has been greatly improved with recent technological developments. Gadolinium-enhanced magnetic resonance angiography remains a useful imaging modality in patients with mild-to-moderate chronic kidney disease (CKD), but the association with nephrogenic systemic sclerosis has greatly limited its usefulness in patients with severe CKD. In recent years, dual-source computed tomography (CT) angiography (CTA) emerged as a high-resolution modality enabling accurate preoperative evaluation of vascular disease with a much lower contrast dose (30-40 mL).

CO₂ angiography can be used as a solely diagnostic preoperative vascular imaging modality or as an adjunct agent to minimize the amount of ICM required during the actual intervention.^{5,6} The most common approach, combining diluted ICM with CO₂, also allows for a reduced total dose. One can substitute with dilute ICM or another imaging modality for key runs. When CO₂ is used for imaging, a small amount of ICM is often required to confirm a finding seen with CO₂, which has been reported to occur in up to 40% of peripheral arterial interventional procedures.¹² However, when adjunct ICM is required, the overall contrast load is usually reduced substantially.

Anatomic landmarks, including vascular calcifications, prior stents, bony structures, clips, surface markers, and intravascular markers, can all be used as visual aids. Advanced referencing options available on modern equipment should also be used to their full potential, including roadmap, overlay, table position recall, and fusion imaging technology.

Physical and chemical properties of CO₂

CO₂ has been in use as an intravascular contrast agent for >30 years and remains the only alternative radiographic contrast medium. It possesses a number of physical and physiological properties that contribute to its utility (Table):

1. Lack of toxicity or allergic reactions: CO₂ is a naturally occurring neutral agent that is non-nephrotoxic, nonhepatotoxic, and nonallergenic.
2. Rapid complete intravascular clearance: CO₂ is highly soluble in blood, with a 30 mL intravascular bolus of CO₂ fully dissolving within 30 to 60 seconds. Most circulating CO₂ is eliminated by the lungs in a single pass.¹³ CO₂ exists in the blood in three forms:
 - A. Carbonic acid, which is the byproduct of the enzymatic conversion of CO₂ and water (H₂O) to carbonic acid (H₂CO₃) by carbonic anhydrase and represents the main form (68%). Carbonic anhydrase efficiently catalyzes the conversion of carbonic acid back into CO₂ in the lungs, where it is expelled out of the alveolar capillaries.
 - B. Carbamino compounds (22%), which are predominantly CO₂-bound hemoglobin.
 - C. Free-dissolved CO₂ (10%).
3. Buoyancy: CO₂ is highly buoyant, preferentially opacifying the nondependent (anterior) portion of the imaged vessel. This key characteristic of CO₂ greatly affects its proper use as a vascular imaging medium. Buoyancy can often be advantageous for imaging branches of anteriorly originating vessels, such as the superior mesenteric and celiac arteries, which are preferentially opacified with small volumes of CO₂. However, it is theoretically disadvantageous for posterior vessels such as the left renal and internal iliac arteries. This property of the gas is generally inconsequential when the vessel to be imaged is <10 mm in diameter because the gas bubbles tend to displace the blood in >80% of the lumen. However, when injected into a large vessel, such as the aorta or inferior vena cava (IVC), the CO₂ bubble flows along the nondependent part of the vessel, with incomplete blood displacement along the posterior portion.⁷ When that occurs, table rotation/tilting or patient repositioning are effective maneuvers used to enhance filling of posterior branches.⁷ For example, if gas fails to opacify a renal artery in the supine position, the patient or angiographic table is rotated allowing better opacification (Fig 1). If the renal artery remains unfilled, catheterization of the artery and selective injection with reflux can be undertaken. CO₂ buoyancy has also been used to improved visualization of the below-knee vessels, which may be suboptimally visualized in the supine position due to progressive fragmentation of the CO₂ bolus. Trendelenburg table tilting or elevation of the lower extremity 15° to 20° can optimize

Table. Physical and chemical characteristics of carbon dioxide (CO₂) and their implications on its utility as an intravascular contrast medium

Characteristic	Implications as contrast medium
<ul style="list-style-type: none"> • Very high plasma solubility in vivo 	<ul style="list-style-type: none"> • High water solubility of molecular CO₂ (20× greater than O₂) • Rapid enzymatic clearance of dissolved CO₂ • This allows for first-pass lung clearance: 60 mL intra-arterial bolus completely dissolves in 30-60 seconds • Allows repeat large bolus injections (20-30 mL) in rapid sequence (20-second intervals) • Virtually no limit to amount that can be given
<ul style="list-style-type: none"> • Hi buoyancy 	<ul style="list-style-type: none"> • Preferential visualization of nondependent section of the vascular tree • Potential for trapping/vapor lock
<ul style="list-style-type: none"> • Liquid displacement properties 	<ul style="list-style-type: none"> • Direct result of nonmiscibility and lack of bolus fragmentation, allowing the CO₂ bolus to be maintained well past the injection point • Unlike liquid contrast agents such as ICM, intravascular CO₂ bolus displaces an equal volume of blood, without significant admixing or dilution
<ul style="list-style-type: none"> • Low viscosity 	<ul style="list-style-type: none"> • Can be administered at high rate even through microcatheters or the interventional sheath • Better visualization of distally reconstituted arteries and veins due to better filling of collaterals
<ul style="list-style-type: none"> • Lower attenuation than tissue 	<ul style="list-style-type: none"> • CO₂ is a negative contrast agent • Implications on the radiographic imaging technique parameters (kV, mA). • Use of digital subtraction with stacking is mandatory to produce diagnostic quality angiograms • Higher susceptibility to motion artifact and bowel peristalsis artifact
<ul style="list-style-type: none"> • Compressibility 	<ul style="list-style-type: none"> • Explosive delivery/vessel distention • Aneurysm/plaque debris embolization

ICM, Iodinated contrast medium; N₂, nitrogen gas; O₂, oxygen gas.

infrageniculate distal filling. Filling below the knee can be further augmented in by selective intra-arterial administration of a vasodilator, such as 100-200 µg of nitroglycerin¹⁴ (Fig 2).

4. Ultralow viscosity/high diffusibility: CO₂ has very low viscosity compared with ICM, which allows for easy manual injection through small-bore catheters or even the small space between a catheter and guidewire.⁷ Sufficient CO₂ volume for

aortic imaging may be easily manually injected using a 3F or 4F end-hole diagnostic catheter.

5. Reflux: The gaseous properties of CO₂ result in central reflux from the point of administration. This permits excellent assessment for ostial disease without the need for catheter-withdrawal angiography or multiple obliquities. This feature is highly advantageous during ostial interventions such as renal and mesenteric arteries stenting. The term “catheter-less” CO₂ angiography⁷ has been coined to describe the administration of CO₂ through the sheath or around the guidewire, during fine positioning of a stent relative to the ostium, allowing high deployment precision.
6. Nonmiscibility and fluid displacement: During its intravascular injection, CO₂ displaces blood instead of mixing with it. Thus, unlike ICM, it does not undergo progressive dilution, allowing excellent visualization of central veins and other large and high-capacity vascular structures.
7. Colorless and odorless: This is an undesirable characteristic of CO₂ that makes it impossible to visually distinguish from air. Therefore, incorrect application of safeguards may result in air contamination, with serious complications.
8. Compressibility: As with other gases, CO₂ is compressible, which may result in pressure buildup when CO₂ is injected through a delivery catheter that has not been purged of liquid content. This can result in eruptive delivery when the liquid column has cleared the end of the catheter.

General principles in CO₂ angiography

Patient monitoring. Intraprocedural monitoring includes electrocardiogram tracings, pulse oximetry, and vital signs. In addition, capnography (end-tidal CO₂), which is defined as graphical and numerical representation of exhaled CO₂ during the respiratory cycle, should be monitored in intubated patients. Capnography is useful during CO₂ angiography because it allows the monitoring of ventilatory and hemodynamic functions in real time. Noninvasive microstream capnography can also be assessed in nonintubated patients, with the airway interface typically a nasal or oral canula allowing concomitant CO₂ sampling and low-flow oxygen (O₂) delivery.¹⁵ Although capnography remains underused during procedures performed under conscious sedation, its use is strongly recommended where the use of a large volume of CO₂ is anticipated or in high-risk patients. Capnography can provide real-time assessment of ventilation and global perfusion status not available by conventional monitoring means, such as central hypoventilation, airway obstruction, apnea, and air embolism, thus allowing timely treatment. In addition, because CO₂ elimination is highly dependent of cardiac output, capnography can be used to monitor for malperfusion.

Heavy sedation should be avoided at any cost during CO₂ angiography. Patient cooperation in breath holding

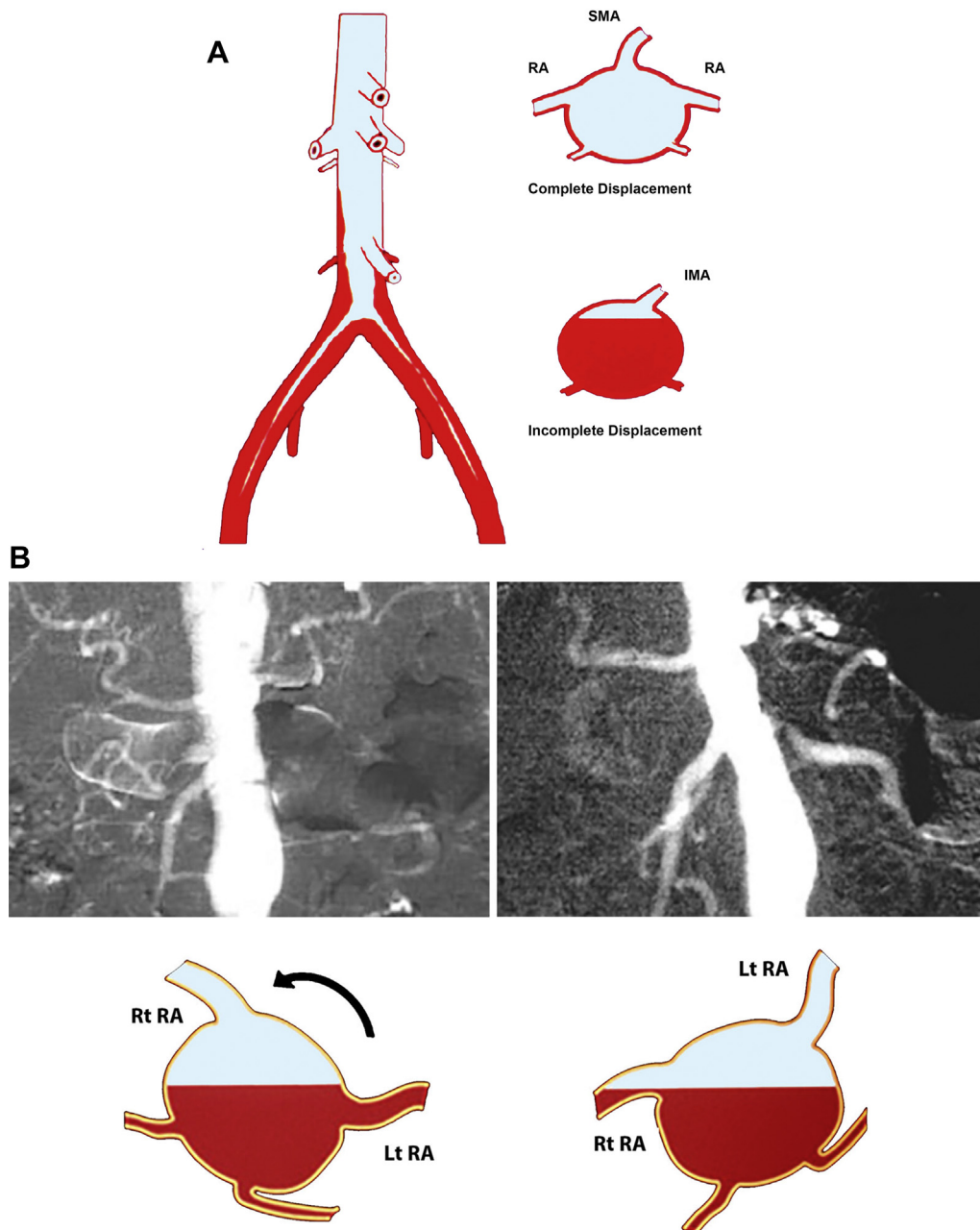


Fig 1. Implications of buoyancy on carbon dioxide (CO₂) angiography. **A**, Incomplete visualization of side branches when CO₂ is injected into a large vessel, such as the aorta or inferior vena cava (IVC), occurs because CO₂ preferentially occupies the anterior part of the vessel, with incomplete blood displacement along the posterior portion. As a result, there is underestimation of lumen diameter and poor filling of posterior or posterolateral side branches, such as the left (*Lt*) and right (*Rt*) renal artery (*RA*). **B**, Use of positional maneuvers to improve opacification of posterior structures during CO₂ angiography. Table rotation/tilting or patient repositioning (in the direction of the *curved arrow*) are effective maneuvers to anteriorly reposition poorly visualized structures. A common example is nonopacification of a posteriorly originating *Lt RA* in the supine position. The patient or angiographic table is rotated to the right, allowing better opacification. *IMA*, Inferior mesenteric artery; *SMA*, superior mesenteric artery. (Modified with permission from Caridi JG, Cho KJ, Fauria C, Eghbalieh N. Carbon dioxide digital subtraction angiography (CO₂ DSA): a comprehensive user guide for all operators. *Vasc Dis Manag* 2014;11:E221-56.)

is paramount during abdominal CO₂ angiography due to degradation of subtracted images by motion artifact. Likewise, distal lower extremity CO₂ imaging is greatly affected by motion artifact in an uncooperative patient

who experiences leg discomfort during gas injection. Heavy sedation can result in disinhibition in elderly patients, especially in the setting of dementia or an acute illness. Moreover, occurrence of respiratory depression

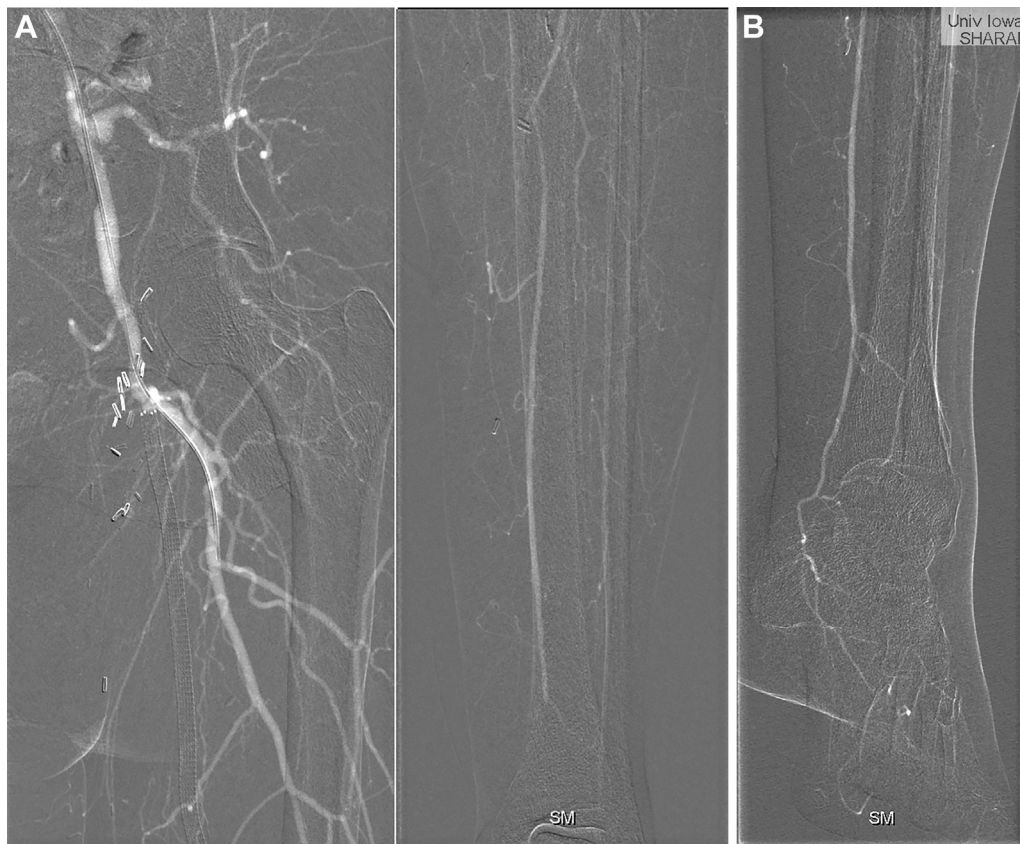


Fig 2. Utility of leg elevation to enhance the opacification of distal infrageniculate vessels, even in the face of extensive femoropopliteal occlusion. **A,** A reflux carbon dioxide (CO₂) angiogram with a 4F catheter positioned in the left profunda femoris artery demonstrates reconstitution of the popliteal trifurcation via collaterals in the presence of complete obliteration of the popliteal artery. Nonfilling of the pedal vessels is noted. **B,** Elevation of the leg to 20° using two pillows allowed excellent filling of the pedal vessels, thus demonstrating the feasibility of a distal bypass graft for revascularization. Although not used in this case, the administration of a vasodilator, such as nitroglycerine, could further enhance distal filling.

or hypotension, both important signs of air contamination, may be mistaken for adverse effects of deep conscious sedation. In a poorly cooperative patient, general anesthesia may sometimes be safer and more expedient.

Delivery platforms and technique. Despite being available for more than three decades, CO₂ angiography remains a largely unstandardized discipline. Most seasoned operators continue to view it as more of an art than a science. Although guidelines governing the use of CO₂ angiography tend to be local and operator dependent, there are general well-accepted principles depending on the particular application. For example, larger CO₂ volumes are generally required in applications where a larger volume of blood needs to be displaced, such as central venography or aortic imaging (30-60 mL), compared with focused imaging of a single vascular segment, such as a renal or femoropopliteal artery, where a volume of 10 to 15 mL generally suffices. The rate of injection is another variable that has to be tailored to the application, as are several adjunct positional

maneuvers that can be used to enhance filling of the segment being imaged.

Undoubtedly, there is a need to adopt well-defined standards for the indications, methods of use, including delivery platforms, dosing and rate of delivery, adjunct techniques, and safeguards. This will require consensus-type recommendations. So far, no effort has been made to initiate such a movement to standardize this growing discipline. Granted, an effort of that magnitude will have to be championed by a major endovascular society. The following section reflects our own assessment of the current status of the art and methods of CO₂ angiography.

Delivery catheter. Being a negative contrast, end-hole delivery works best to minimize dispersion of the CO₂ bolus. However, any lumen can be used, be it a needle, cannula, catheter, sheath, or even the minimal space between concentric coaxial devices. The operator should position the tip just upstream to the territory to be imaged. The operator should take into account CO₂ volume, volume of blood to be displaced, and the effect

of the clock-face takeoff of the branch to be imaged and its subsequent course. These factors determine the need for patient body or table rotation, table tilt, C-arm positioning, and the need for adjunct maneuvers to enhance visualization.

Gas storage and delivery system. There are multiple options for CO₂ delivery from its source, including the hand-injection purged syringe method, plastic bag system, dedicated computerized/automated CO₂ injectors, and newer portable closed-system platforms.

1. Hand-injection approach: The setup for hand injection involves medical grade CO₂ cylinder/laparoscopic insufflators with an inline bacterial filter, three-way stopcock connectors, and one-way check flow connectors.³ Advantages of this manual method are optimal timing, injection control, ability to arrest injection at any time, wide availability, and low cost. Disadvantages include high radiation exposure and the open nature of the CO₂ delivery system, with the potential for air contamination in case of component failure or operator error. Mindfulness of the potential for high radiation exposure to both patient and operator has to be considered during CO₂ angiography, and attention to optimized imaging geometry, such as minimizing the image intensifier-patient gap, and use of shielding barrier, are strongly recommended.
2. Bag reservoir delivery system: This approach became popular in the late 1990s until its discontinuation due to a permanent manufacturer recall prompted by reports of unintentional intra-arterial injection of O₂ from a poorly identified canister erroneously mistaken for CO₂, resulting in severe adverse effects.¹⁶ The system itself was adapted from a commercially available fluid disposal bag system (AngioDynamics, Queensbury, NY).¹⁷ It consists of a 1.5 L flaccid bag attached to a three-port check valve, multiple three-way ports and one-way check flow valves to reduce stopcock manipulation, a particulate filter (0.2 μm), and a bleed-back/contrast injection port near the catheter hub. Before use, the bag is filled with CO₂ and emptied three times to purge any air contamination.
3. CO₂MMANDER/AngiAssist Portable system: The CO₂MMANDER (AngioAdvancements, Ft. Meyers, Fla) is currently the only portable CO₂ delivery system approved by the U.S. Food and Drug Administration. It is used in conjunction with the AngiAssist, a disposable delivery apparatus (AngioAdvancements).¹⁸ The AngiAssist's key components are a proprietary three-way 60° connector (K-Connector), a series of one-way safety valves, a multiuse CO₂ cartridge, preattached 60 mL reservoir syringe, and 30 mL injection syringe (Fig 3). Advantages of this system are the dependable miniature CO₂ source allowing numerous uses, avoidance of direct connection between the CO₂

source and the patient, portability and reusability, and a relatively inexpensive disposable tubing/syringes apparatus. The apparatus can be left connected to the outer guide catheter or interventional sheath, allowing an uninterrupted closed-circuit connection for on-demand imaging without the need for repeated purging, which greatly simplifies the imaging process. The added length of the tubing system between the injection syringe and the catheter helps lower the operator's exposure to scatter radiation.

4. CO₂ Angioset: The CO₂ Angioset (OptiMed, Ettlingen, Germany) is not available in the U.S. but is popular in Europe and worldwide. It has the advantages of simplicity, portability, and enhanced safety compared with manual systems. The kit consists of a dedicated, well-marked medical grade CO₂ canister, a pressure-relief valve ensuring that any excessive pressure rise is purged, a sterile filter, three-way stopcock, and a dedicated 100-mL syringe allowing the delivered volume to be adjusted in 20-mL increments. One published report showed the system to be safe, easy to use, and highly diagnostic even in infrapopliteal arterial segments.¹⁹
5. Automated injectors: As with ICM, automated injection of CO₂ would offer several advantages, including precise control of injection timing, pressure, and volume, and reducing radiation exposure to the operator. However, unlike liquid ICM, an automated injector of a gas medium poses many technological challenges. The earliest automated CO₂ injector was the CO₂ject (AngioDynamics), which was designed in partnership with the University of Florida in the 1990s. Preliminary clinical experience was promising.²⁰ However, the system was expensive, bulky, and cumbersome to operate and quickly became irrelevant with the introduction of the popular bag method. More recently, interest in automated CO₂ injection resurfaced with the introduction in Europe of the Angiodroid Injector (Angiodroid SRL, San Lazzaro di Savena, Italy). This new generation computerized CO₂ injector has the advantages of being reliable, versatile, and user friendly. The device computes the amount of gas to be injected into the vessel and accordingly automatically, purges air out, verifies CO₂ purity, and determines the delivered volume and injection pressure. Preliminary reports of this system's clinical performance and safety have been encouraging.²¹⁻²³ A simpler automated CO₂ injectors (INSPECT 3005R and the more compact 2005R; Malek Medical GmbH, Wismar Germany) recently entered the European market, but experience with these systems is lacking.

Imaging parameters and technique. Being a negative contrast medium, optimized contrast visualization requires CO₂-specific imaging parameters, including a

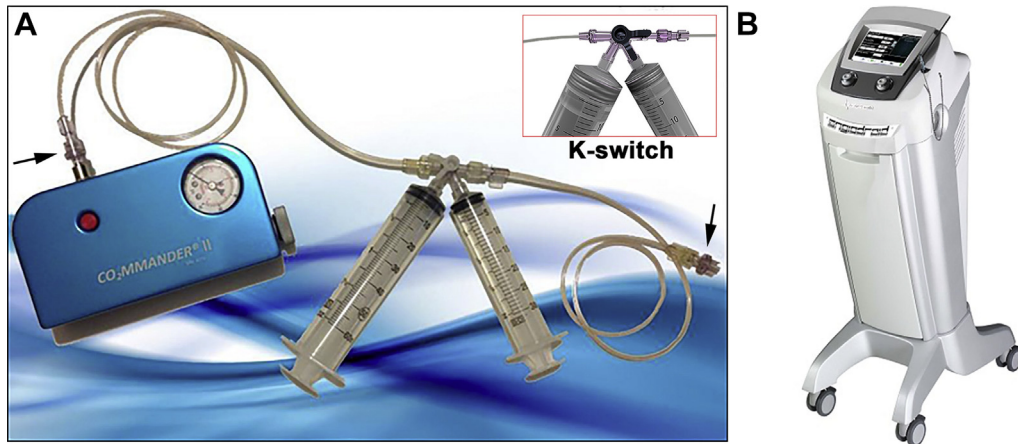


Fig 3. Representative examples of current carbon dioxide (CO₂) infusion approaches. CO₂ delivery during angiography has evolved along two broad categories: **(A)** simpler manual close-systems and **(B)** more capable complex automated injectors. **A**, The CO₂MMANDER/AngiAssist closed system for CO₂ angiography (AngioAdvancements, Ft. Meyers, Fla). The CO₂MMANDER refers to the reusable CO₂ delivery component. The AngiAssist refers to the disposable CO₂ management and delivery system and features a series of one-way valves and a proprietary K-valve stopcock that allows switching from reservoir filing to injection mode without the risk of air contamination. **B**, The Angiodroid (Angiodroid SRL, San Lazzaro di Savena, Italy) is the newest-generation automated CO₂ injector. It offers computerized operation, user-friendly interface, and a highly controlled delivery with multiple automated safeguards.

high mA (60-90)/low kV (50-70) technique, pulse width of 60 milliseconds, and a dedicated imaging and software package to increase photon flux and enhance negative contrast visualization. Because CO₂ imaging inherently necessitates subtraction, a high-resolution digital subtraction angiography system (1024 × 1024) is mandatory. Because of the importance of stacking in CO₂ angiography, a high frame imaging rate is mandatory (4-6 per second). Stacking software compensates for discontinuous gas column/bubble breakup/insufficient bolus volume.

However, the Achilles' heel of CO₂ angiography remains its susceptibility to motion artifact, which can render the subtracted CO₂ angiogram completely useless. This tends to be most problematic in the abdomen, and control of respiration, patient motion, and peristalsis artifacts is therefore crucial. Additional mask images, superselective CO₂ injection, intravenous glucagon, patient cooperation, as well as sedation and analgesics may all be helpful tactics. The nonmixing characteristic of CO₂ is a beneficial feature. However, this can also result in susceptibility to bolus fragmentation that can occur beyond the injection point after crossing bifurcations and areas of high turbulence. The resulting artifact, unique to CO₂ angiography, is often referred to as "pseudostenosis" and is a consequence of gas fragmentation. Fragmentation usually has a cobblestone-like appearance, but when in doubt, confirmation using additional runs with CO₂ or diluted ICM should be obtained.

CO₂-specific adverse effects and management. The occurrence and severity of complications during CO₂ angiography are often directly related to one of the

following factors: excessive dose delivered in a short time, air contamination, location in the vascular tree where CO₂ was delivered, and presence of adverse anatomy or underlying vascular disease. Considering the versatility of CO₂ angiography and the wide variability in operator experience and delivery techniques, the reported incidence of adverse effects with CO₂ angiography varies considerably, from rare to as high as 17%.^{12,24,25} Thankfully, almost all of the reported adverse effects are minor and transient in duration. Moreover, the overall complication rate appears to have become lower after adoption of closed-system delivery methods, implicating a possible role of room air contamination. Complications occurring during CO₂ angiography can generally be categorized into two broad categories: nonserious and serious/lethal. Abdominal discomfort, nausea, paresthesia or transient focal weakness, and tenesmus are examples of self-limited nonserious adverse effects occurring during or shortly after the injection and usually resolving within a few minutes. More serious complications include symptoms that persist long after the injection or are progressive in nature.

Nonserious adverse effects. CO₂ aortography may cause nausea and abdominal pain lasting 2 to 3 minutes. The cause is likely due to transient CO₂ trapping in the mesenteric arteries and resolves quickly upon reabsorption of the gas. No specific treatment is required, although rotating the patient from side to side and gently massaging the abdomen may enhance CO₂ reabsorption. Reducing the CO₂ bolus volume and injection pressure as well as careful purging of liquid from the catheter usually reduces the occurrence and severity of

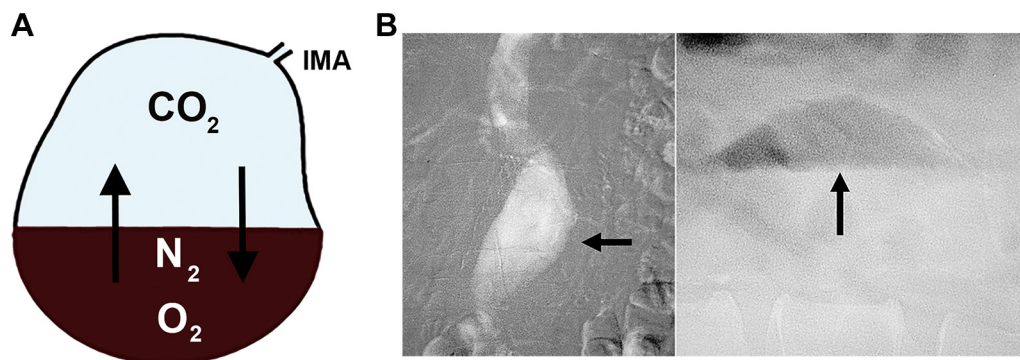


Fig 4. Mechanism of the vapor lock phenomenon. Persistent trapping of carbon carbon dioxide (CO_2) can result in equilibration of nonsoluble gases with the trapped gas pocket, mainly through exchange of CO_2 with nitrogen gas (N_2) or oxygen gas (O_2), or both, from the blood. Depending on its location, the resulting nondissolvable gas bubbles can cause a mechanical obstructive effect. **A**, Gas exchange occurring between blood and the trapped CO_2 pocket. **B**, CO_2 trapping in the anterior aspect of a large tortuous abdominal aortic aneurysm (arrow). IMA, Inferior mesenteric artery.

pain. Persistence or worsening of abdominal pain should prompt suspicion for vapor lock, which can cause mesenteric ischemia. Leg pain or cramping is also a common benign occurrence during selective lower extremity CO_2 injection. Injection of CO_2 into a peripheral vein for upper extremity venography may cause pain at the injection site. This can also be the result of explosive delivery, and ensuring proper purging of the catheter can often help reduce discomfort. Decreasing the amount and vigor of CO_2 delivered by using selective injection and stacking technique can lessen that occurrence.

Serious adverse effects.

- **Air contamination:** This is one of the most serious complications that can occur during CO_2 angiography. Unlike liquid contrast agents, CO_2 is colorless and cannot be distinguished from air. Hence, contamination with air due to breached technique or equipment failure can go unrecognized. Dedicated automated CO_2 injection systems have built-in features for ensuring purity of the delivered gas. In the near future, CO_2 sensors incorporated into the injection circuit will also ensure that only pure CO_2 is delivered into the patient.

Ischemic manifestations of air embolism depend on the vascular bed and are quite variable in severity. The most devastating sequelae involve neurotoxicity and abdominal aortic or cardiopulmonary air-lock phenomena which can lead to bowel ischemia or cardiovascular collapse. Most instances involving small amounts of air contamination are, thankfully, self-limited in nature. When symptoms persist or where risk of irreversible injury exists, steps need to be taken to clear intravascular air. Effective therapeutic adjuncts include positional maneuvers, massaging, aspiration of the air pocket using an end-hole catheter, hyperbaric oxygen therapy, and heparinization to prevent secondary thrombosis.

- **Aortic vapor lock:** Vapor lock usually occurs in the setting of multiple rapid-sequence injections, especially in high-risk vascular anatomies such as severe aortic tortuosity or a large aneurysm. CO_2 trapping in the anterior aspect of an aneurysm may preclude its timely elimination. The phenomenon of vapor lock occurs as a result of exchange and equilibration of nonsoluble blood gases (mainly nitrogen gas [N_2] and O_2) with the trapped CO_2 pocket. Depending on its location, the resulting nondissolvable gas pocket can cause a mechanical obstructive effect. In an AAA, obstruction of the inferior mesenteric artery can result in colonic ischemia (Fig 4). Vapor lock in the visceral aorta can result in middle gut mesenteric ischemia, which can lead to serious complications if not promptly addressed. This phenomenon should be suspected when prolonged, unrelenting abdominal pain occurs during CO_2 angiography. The presence of multiple risk factors in the same patient should prompt caution. For example, known large AAA, severe aortic tortuosity, and presence of known superior mesenteric artery occlusive disease will be at a higher risk for mesenteric vapor lock. Depending on the location and infused volume, allowing 1 to 3 minutes between CO_2 injections may help prevent the localized accumulation of the culprit gas pocket. Nitrous gas anesthesia increases the risk of N_2 transfer to the trapped pocket and should always be avoided during CO_2 angiography.

When an aortic gas vapor lock obstructing one or more mesenteric vessels is suspected in the setting of nonresolving abdominal pain, the first step is fluoroscopic assessment. If a persistent gas bubble is identified, positional and manual compression maneuvers are first used, including side-to-side table or patient rotation, and deep abdominal massage to unlock and dissipate the gas bubble. If unsuccessful, fluoroscopically guided catheter aspiration is a quick

and effective means for removing the culprit gas pocket. If pain persists, heparin should be administered to prevent secondary thrombosis, and consideration should be given to hyperbaric O₂ therapy. The patient is subsequently monitored for the need of surgical exploration.

- **Cardiac/pulmonary artery vapor lock:** When CO₂ is used in venous applications, it rapidly passes through the central veins and right cardiac chambers into the pulmonary arteries. CO₂ trapped in the pulmonary artery is usually absorbed ≤ 30 seconds in the absence of air contamination. Trapped gas in the anteriorly located pulmonary artery usually occurs after inadvertent injection of an excessive volume of CO₂ or insufficient spacing of repeated large-volume injections, resulting in equilibration with nonsoluble blood gases. The symptoms are similar to massive pulmonary embolism with hypoxia and hypotension. Unlike the commonly seen transient gas pocket over the pulmonary outflow tract, an occlusive pulmonary artery gas lock is a potentially lethal complication marked by acute cardiovascular collapse caused by acute right-sided heart failure and impaired left heart filling. Fluoroscopy will show a persistent gas bubble in the pulmonary artery. When this is noted, especially if oxygen desaturation or hypotension, or both, develop it is crucial to consider the potential of unrecognized air contamination. Initial management should to place the patient in the Trendelenburg/left lateral decubitus position. If that does not relieve the symptoms, fluoroscopically-guided catheter aspiration of the pocket should be promptly undertaken.
- **Thrombotic atheroembolism:** Cholesterol and thrombotic atheromatous emboli represent a category of devastating, potentially fatal complications that can occur in certain high-risk patients during CO₂ angiography. A sudden rise in intraluminal pressure and explosive CO₂ delivery can cause the release of loosely adherent fragments into the downstream vascular beds. Disseminated distal atheroembolism can cause any or all of irreversible renal failure, progressive nonocclusive bowel ischemia, pancreatitis, rhabdomyolysis, livedo reticularis, spinal cord ischemia, or other peripheral embolic lesions, which are associated with a high mortality.^{12,26,27}

Risk factors for microembolic complications during CO₂ angiography include wedged or subluminal position of the catheter within mural thrombus or plaque, presence of irregular mural thrombus in an AAA, and coral reef or shaggy aorta. An important step to avoid this complication is to ensure that the catheter tip is not close to these embolic sources. Positioning the catheter tip in a side branch before injection may prevent this complication by allowing the gas to reflux into the aorta without a jet effect.

However, the single most important safeguard against a sudden surge in intraluminal pressure is to ensure complete fluid purging from the catheter lumen before the bolus delivery. Otherwise, the CO₂ bolus becomes compressed against the fluid column, expanding in an eruptive manner once the liquid column exits the catheter. Explosive release of the CO₂ bolus can double the intraluminal pressure, and although this is generally unlikely to cause vascular damage, release of loosely adherent atheromatous debris or mural thrombus may occur.

- **Spinal cord ischemia:** Transient spinal cord ischemia has been reported during intra-abdominal injection of CO₂.²⁵ Patients may complain of transient paresthesia or dysesthesia that quickly resolves as the CO₂ burden is dissolved and clears. Persistent neurologic deficits, however, should raise major concerns. A gas lock is unlikely in these posteriorly located branches, except in the presence of severe scoliosis or aortic tortuosity, and a microembolic etiology is more likely. A persistent deficit should raise a concern for air contamination, and consideration should be given to cerebrospinal fluid drainage. An atheroembolic cause can also be implicated in nonresolving spinal cord deficits and may carry a poor prognosis.
- **Neurotoxicity:** Neurotoxicity is a risk whenever CO₂ is administered intra-arterially above the diaphragm. This also includes upper extremity peripheral arteries, even in the forearm, because of possibility of reflux into the subclavian and vertebral arteries. However, intravenous supradiaphragmatic injection of even large volumes of CO₂ is generally considered safe. Rarely, an unrecognized right-to-left intracardiac shunt may result in paradoxical CO₂ neurotoxicity with potentially disastrous outcomes. It is thus important to ensure that a patient undergoing central venography has no risk for right-to-left physiology such as pulmonary hypertension, severe chronic obstructive pulmonary disease, or known congenital heart disease.

Selected applications of CO₂ angiography

Lower extremity peripheral arteries angiography and endovascular interventions. Highly diagnostic peripheral arterial vascular imaging can be achieved using CO₂ at nearly any infradiaphragmatic location. The entire spectrum of endovascular interventions can also be accomplished, including balloon angioplasty, stenting, atherectomy, and any other type of intervention requiring intravascular luminal imaging.^{22,23} The low viscosity of CO₂ allows easy assessment of progress using the indwelling sheath, interventional device, or balloons, without the need to exchange to another catheter, termed "catheter-less" delivery. There is also virtually no limit on the number of runs or amounts of CO₂ used. As a result, multiple adjustments of endoprosthesis position

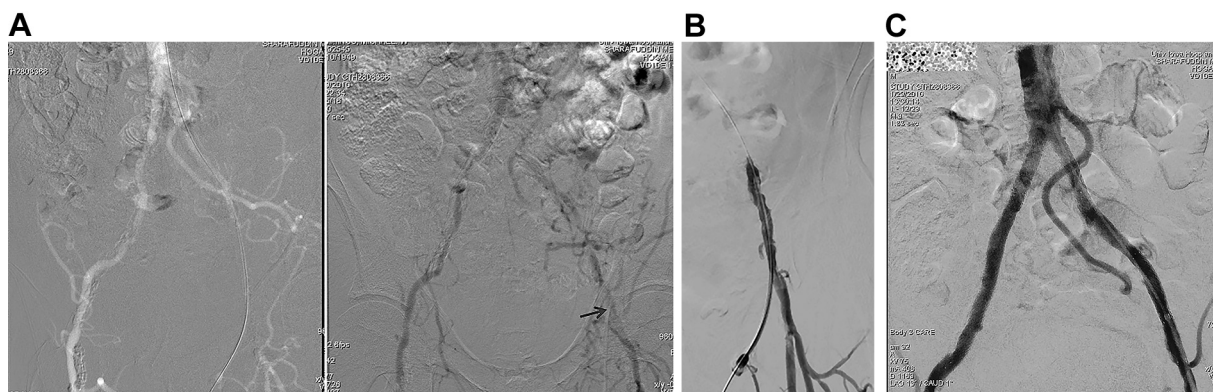


Fig 5. Patient with debilitating claudication and noninvasive vascular evaluation suggestive of aortoiliac disease. After access is obtained into the left common femoral artery, resistance is noted during advancement of a guidewire into the aorta. **A**, A digital subtraction angiogram obtained through the 4F dilator, using 20 mL of carbon dioxide (CO₂), demonstrates occlusion of the left external iliac artery. The low viscosity of CO₂ also enables visualization of the entire aortoiliac pelvic circulation and the extensive collateral network. **B**, Iodinated contrast injection into the left common femoral artery through a 4F sheath shows the occlusion and very little detail regarding the extent of the occlusion, the level of reconstitution, or the status of the contralateral iliac axis. However, in this poorly cooperative patient, the CO₂ angiogram is more prone to motion and bowel peristalsis artifact compared with iodinated contrast-enhanced angiography. **C**, Final angiogram after recanalization and stenting.

can be made before final deployment. CO₂ is also an ideal agent during retrograde pedal access interventions by allowing contrast guidance while maintaining extralow-profile access. The low density of gas contrast compared with the radiodense vascular endoprosthesis inherently enhances visualization of the device. CO₂ is also valuable in the assessment of long-segment total occlusions due to better collateral filling, allowing identification of the reconstituted vessel distal to the occlusion, which may not be visible using ICM (Fig 5).

Reliability of CO₂ in assessing stenosis severity in vessels <8 mm in diameter is generally comparable to digital angiography using ICM and can also yield comparable densitometric analysis of stenotic lesions.²⁸

The value of CO₂ angiography as an alternative contrast agent in the iliofemoral segments has been well documented, with the highest diagnostic quality being in above-the-knee arterial segments.^{23,29,30} Although the diagnostic value of CO₂ in the infrapopliteal vessels is less consistent in the more distal segments,³⁰ growing experience with this modality, including our own, has demonstrated that excellent visualization of these segments can be achieved in experienced hands and with the use of a number of adjunct techniques (Fig 2 and Fig 6):

1. Selective catheterization (popliteal artery or distal).
2. Use of a small (3F-4F) end-hole catheter. Selective distal delivery of an intact CO₂ bolus allows optimized filling of the distal vasculature while proximal segment imaging is readily accomplished by proximal reflux. Even in the presence of femoropopliteal occlusion, visualization of the distal arteries can be enhanced by achieving the

distal-most possible position of the catheter tip, which optimizes collateral filling.

3. Digital stacking software (Fig 7).
4. High frame rate acquisition of at least 6 frames/s.
5. Acquisition of several mask frames before injection to optimize the yield of digital stacking.
6. Patient cooperation is paramount; therefore, patient education before the procedure, coaching during the injection, and if needed, the use of a leg immobilizer are valuable.
7. High contrast x-ray technique (low kV, high mA).
8. Leg elevation (15°-20° relative to the torso) to allow preferential infrageniculate filling.
9. Selective intra-arterial administration of 200 to 300 µg nitroglycerin for vasodilatation.¹⁹

Experience with these and other adjunct maneuvers for optimizing distal vessel filling and CO₂ imaging and the availability of a dedicated CO₂ imaging system may increase the reliability of CO₂ imaging in the below-knee segments and also provides a reliable roadmap to interventional procedures.^{13,18,19}

Newly developed computerized CO₂ injectors may also further enhance the visualization of the distal arterial segment, owing to flow parameters optimization.^{22,23,31} CO₂ is injected through an automatic presettable constant pressure and volume injector to enable nearly complete filling of the vascular space and minimum gas flow fragmentation, resulting in reliable and consistent imaging. These systems also enable unparalleled safety by virtually eliminating the risk of air contamination and avoiding intravascular pressure surging that may cause peripheral emboli or vessel injury. Optimal filling of the vessels and collateral pathways ensures high reliability

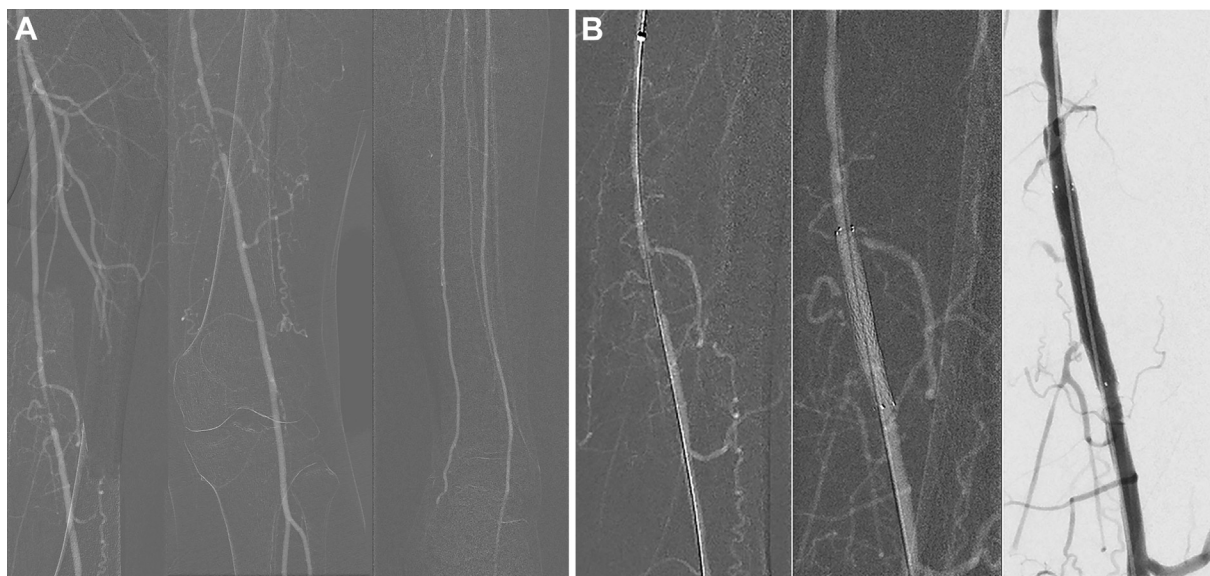


Fig 6. Left lower extremity selective (stacked) carbon dioxide (CO₂) angiogram in a patient with chronic kidney disease (CKD) and a solitary kidney presenting with toe ulceration. **A**, Focal occlusion of the mid superficial femoral artery is noted. **B**, The lesion is traversed and stented. Only 5 mL of diluted iodinated contrast medium (ICM) was used for completion run. Note is made of the better visualization of stent elements on CO₂ angiography owing to the lower radiodensity of CO₂.

in detecting significant stenoses and allows excellent vascular anatomic details in secondary branches, even in the presence of multilevel vascular disease. The main drawback of modern automatic injectors is high cost and bulkiness in the crowded angiography suite environment. They have also not yet been approved for use in the U.S.

Because of the negative effect of the gas contrast, CO₂ angiography allows excellent visualization of the stent itself during angiography and may thus enable a better tool for angiographic assessment of stent integrity, patency, and in-stent restenosis. Struts are easier to see, and therefore, abnormalities caused by poor expansion/wall apposition, compression, distraction, and fractures are easier to see with CO₂ angiography (Fig 6). This is particularly helpful in endoprostheses with lower radiovisibility.

Visualization of collateral pathways and reconstituted vascular stumps. Visualization of collateral pathways is an important component of the angiographic evaluation in arterial and in venous occlusive disease. Buoyancy of CO₂ allows better filling of anterior collateral pathways. In addition, low viscosity, blood displacement, and nonmixing properties also enable collateral visualization. Unlike CO₂, ICM mixes with blood when injected into a vessel and becomes diluted, making it less dense as it travels through collateral vessels. CO₂ also enables antegrade, retrograde, and contralateral (cross-midline) vascular filling. This allows the operator to visualize all potential collateral pathways, which can be valuable in assessing the physiology of vascular occlusions. Moreover,

the reconstituted segments distal to complete occlusions can also be visualized,^{13,23} allowing for better demonstration of revascularization options (Fig 5).

Intra-abdominal arteriography and endovascular interventions (renal, mesenteric, and transplant organs). CO₂ imaging of the celiac and superior and inferior mesenteric vessels is relatively straightforward given their anterior course from the aorta, allowing excellent filling of these anteriorly oriented branches, which can then be imaged in any projection. Consequently, CO₂ imaging is an excellent choice for guiding mesenteric endovascular interventions.

The value of CO₂ angiography in renovascular disease is well documented, especially given the high incidence of CKD in this population and susceptibility to CIN. A large number of studies, including a few randomized trials, have demonstrated equivalency or superiority of CO₂ compared with ICM in the diagnosis, management planning, and endovascular management of renal artery occlusive disease.³²

Feasibility of catheter-less angiography is another valuable characteristic of CO₂, enabling optimal imaging of mesenteric and renal vessels during endovascular interventions. CO₂ can be readily delivered through the interventional sheath or the interventional catheter around the guidewire. This enables low-profile interventions with minimal size access and may eliminate the need for bilateral access during certain interventions.⁷ Intravenous administration of glucagon (0.5-1 mg) before CO₂ injection improves intra-abdominal CO₂ angiography by decreasing peristalsis and reducing bowel gas artifacts.

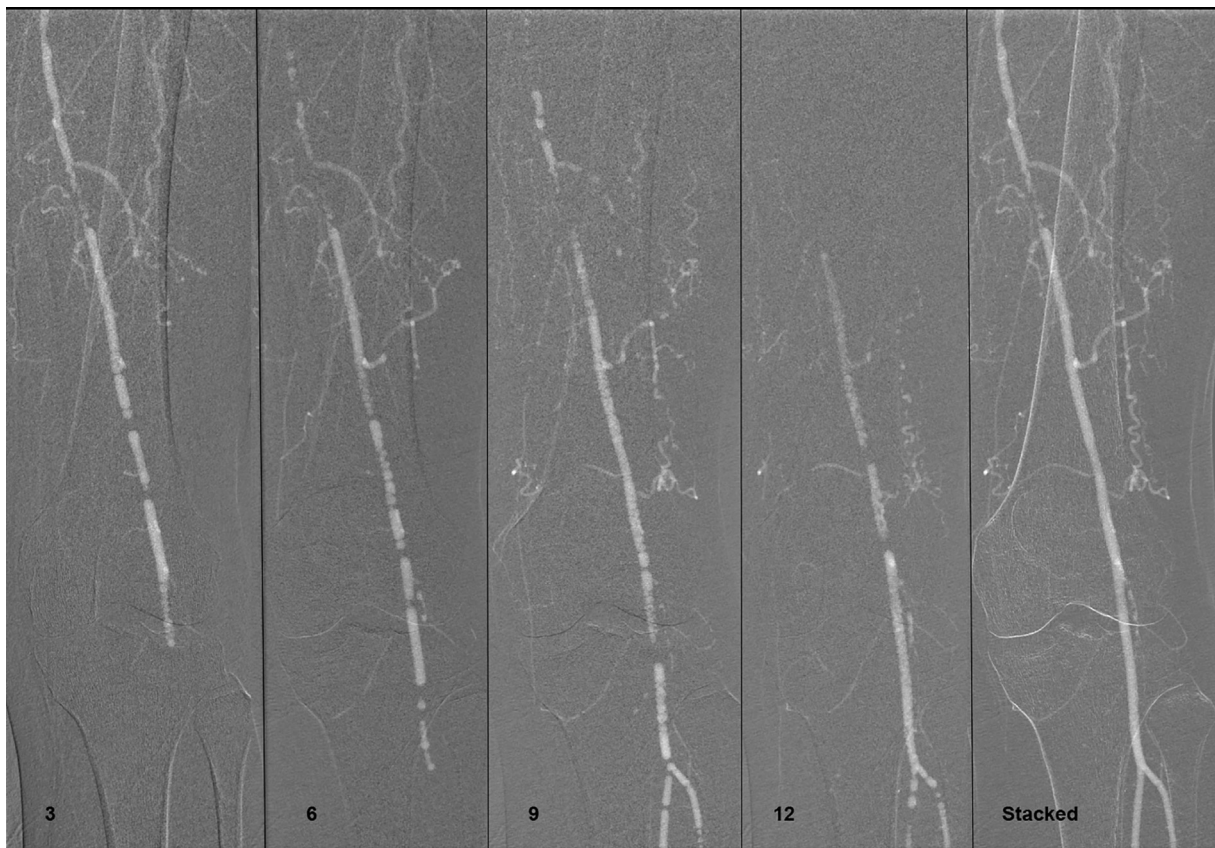


Fig 7. Digital stacking refers to postprocessing software that is widely available in most modern angiographic equipment. It is also referred by some vendors as peak opacification or minimal opacification (when referring to the negative density of gas). Breakup of the carbon dioxide (CO₂) bolus occurs after it travels well beyond the injection point. This results in fragmentation into smaller bubbles and incomplete luminal filling on the static frame. Image stacking refers to the summation of the individual frames. The resulting image represents a reconstruction of the entire lumen from the individual segments seen on the various frames. High-quality digital imaging equipment, high frame-acquisition rate, proper masking, and avoidance of motion are crucial for successful stacking.

As mentioned before, the feature of central reflux when CO₂ is injected into the renal artery allows reliable delineation of the renal artery ostium. This can be done repeatedly while positioning the stent before final deployment, allowing accurate positioning relative to the ostium (Fig 8). Even though CO₂ angiography enables excellent demonstration of ostial and main renal artery disease, its diagnostic accuracy diminishes in subsequent branches, especially secondary and tertiary order branches.³³ Moreover, CO₂ does not allow opacification of the nephrogram, which is a useful feature in assessing parenchymal renal perfusion. Although CO₂ angiography can demonstrate other non-atherosclerotic conditions involving the main renal artery, such as fibromuscular dysplasia,⁷ its sensitivity and specificity in subtle dysplastic lesions and branch involvement are likely inferior to ICM.³³

Patients with suspected artery stenosis after renal or pancreatic transplant are particularly vulnerable to ICM-induced nephrotoxicity as a result of pre-existing

microvascular disease, rejection, and drug toxicity episodes. CO₂ imaging is ideal in those cases because of the lack of nephrotoxicity. Moreover, because of the anterior orientation of the transplanted organ vessels, CO₂ provides excellent opacification of these vessels in diagnosis and also in guidance of endovascular interventions.

Peripheral and central venography. Venography is an application that lends itself well to CO₂ angiography. Low viscosity, nonmixing, and fluid displacement properties of CO₂ allow the easy and safe delivery of a large nondiluted bolus, allowing clear visualization of high-capacity central veins, in a manner superior to ICM. In the presence of total central venous occlusion, CO₂ readily demonstrates bilateral collateral pathways from a single injection point and allows the demonstration of the reconstituted vascular segments beyond the occlusion. Peripheral venography can be easily performed through a small needle placed in a peripheral vein. Ability to inject a large volume of CO₂ in a relatively short time enables full opacification of long venous segments.

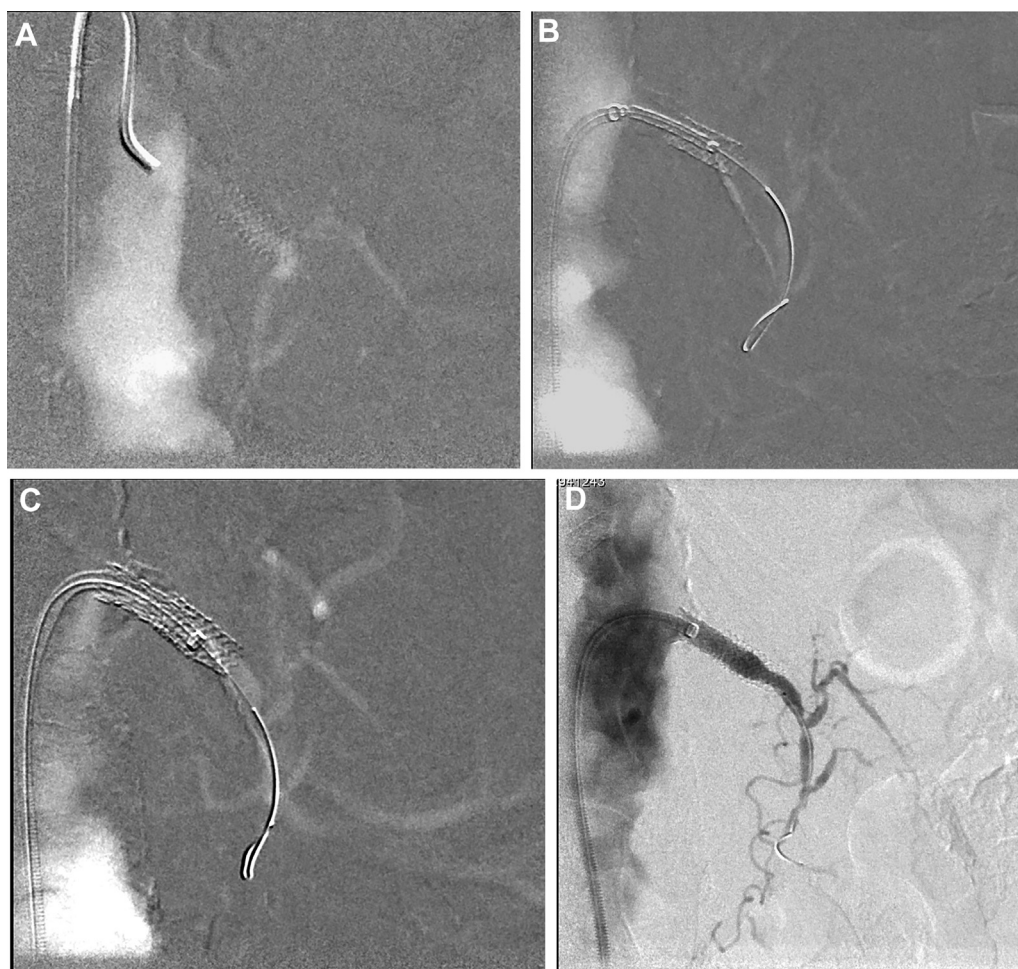


Fig 8. Renal artery stenting in a patient with bilateral renal artery disease presenting with hypertension and flash pulmonary edema. She has a prior malpositioned and restenosed left renal artery stent. **A**, Nonselective end-hole catheter injection of 10 mL of carbon dioxide (CO₂) demonstrates high-grade stenosis of the left renal artery ostium and a restenosed stent that does not cover the ostial lesion. **B**, After predilation, the lesion was crossed with a 5F Flexor sheath (Cook Medical, Bloomington, Ind), and a Formula-418 stent (Cook Medical) was positioned across the lesion. Reflux angiogram using 10 mL of CO₂ demonstrates the renal artery ostium very well. **C**, CO₂ angiogram after stent deployment shows excellent position. **D**, Final control angiogram, using 5 mL of diluted iodinated contrast medium (ICM) after ostial flaring into the aorta, confirms excellent position and patency.

Preferential demonstration of the deep venous system can be accomplished with the use of tourniquets, akin to the approach used in conventional ICM ascending venography.

Indications for upper extremity CO₂ venography include evaluation of arm swelling, mapping of upper extremity veins for planning of autogenous hemodialysis fistulas,¹⁴ and peripherally inserted central catheter placement in patients with difficult venous access. CO₂ is also valuable in guiding placement peripheral and central venous catheters. Slow injection of CO₂ from a small peripheral venous canula opacified the veins, serving as a target for venipuncture in the arm veins or subclavian vein or can be used to generate a central venous roadmap.

Because of its low viscosity, brisk CO₂ infusion can overdistend the highly compliant veins, causing more discomfort than with ICM venography. Therefore, when injected peripherally, it is important to infuse the CO₂ in a slow, controlled manner.

We have found CO₂ helpful in planning interventions for pelvic central venous occlusions, especially those associated with May-Thurner syndrome (Fig 9). Ability of CO₂ to reflux through competent valves allows better retrograde visualization of important inflow veins that are not visualized using liquid contrast agents.

IVC filter placement and retrieval. CO₂ venography is a useful contrast agent for guiding IVC filter placement and retrieval.¹⁴ High-quality inferior vena cavography is a crucial component of the IVC filter placement

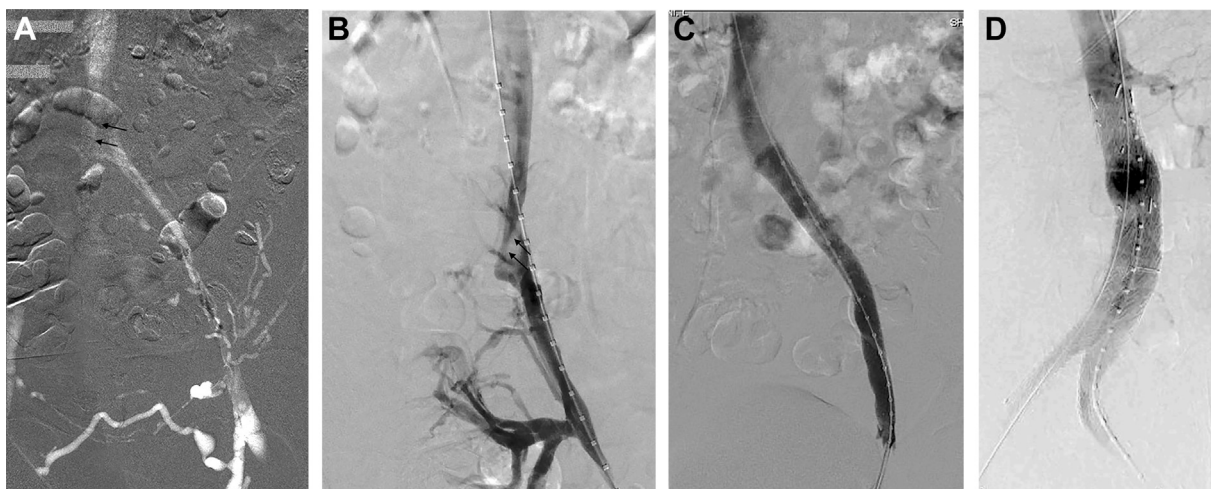

Fig 9. Carbon dioxide (CO₂) venography in a patient with left iliac vein occlusion. **A**, After percutaneous access into the left common femoral vein, 20 mL of CO₂ was injected through a 4F micropuncture cannula, demonstrating long-segment occlusion and high-grade stenosis of the left iliac axis (*arrows*). CO₂ reflux and collateral filling readily opacifies the great saphenous vein as well as the contralateral iliac vein and the inferior vena cava (IVC). **B**, Band-like obstruction at the level of the crossing right common iliac artery with associated synechial changes are better demonstrated on iodinated contrast medium (ICM) venography (*arrows*). Findings are consistent with underlying May-Thurner compression. **C**, Completion venogram after stenting.

procedure and requires localization of the position of both renal veins as well as the identification of any aberrant renal veins. Diameter assessment with CO₂ cavography correlates well with ICM cavography but is somewhat less accurate in the determination of the position and number of renal veins. Unlike with ICM, inflow of unopacified blood from the renal veins cannot be demonstrated on CO₂ cavography. One needs to be particularly aware of the potential for nonvisualization of the more posteriorly oriented right renal vein, which may require additional positional changes for its demonstration. Alternatively CO₂ venography can be performed using a reflux technique with a directional catheter placed in each of the two renal veins as more reliable means to localize the renal vein and the opacity of any accessory or aberrant renal veins that tend to communicate with the main renal vein in the hilum. CO₂ cavography is also less sensitive for the detection of partial thrombosis, particularly when located along the posterior surface of the IVC. When suspected, supplementation with ICM cavography should be performed.

Detection of bleeding. Three combined properties of CO₂ (low viscosity, compressibility, and immiscibility) allow for better detection of sources of bleeding that may otherwise be occult on conventional angiography using conventional ICM. The ability to demonstrate occult bleeding not visible on ICM angiography is not only attributable to the high diffusion of CO₂ but may also reflect expansion of the gas upon exiting the vessel. In addition, unlike ICM, the lack of a capillary phase may allow better visualization of the bleeding point(s) due to the lack of overlapped opacified tissue and lack of

progressive dilution caused by mixing with unopacified blood. These same attributes are likely the reason CO₂ angiography has shown promise in the demonstration of endoleak, vascular collaterals, and vascular malformations.

CO₂ has been used to localize bleeding in various conditions, including trauma, tumor-hemorrhage, GI bleeding, and iatrogenic injuries. Several reports have documented successful demonstration of an active bleeding site using CO₂ angiography, even with a negative result on ICM angiography.³⁴ One report of 27 patients with suspected upper GI bleeding cited a threefold higher ability of CO₂ to detect a bleeding site (44%) compared with ICM (14%),³⁵ and another series reported ~2.5-times the sensitivity for defining the acute hemorrhage compared with ICM.³⁶ However, no head-to-head comparison study has been conducted to date.

In traumatic bleeding, contrast-enhanced CT plays an important role in the evaluation of active bleeding from the spleen, liver, kidney, and pelvis. It also provides enough information to institute angiographic therapy and direct the angiographer to the precise area of interest. Because of the low viscosity, CO₂ is sensitive in detecting extravasation. If extravasation is seen on the aortogram, the bleeding artery is catheterized, and the arteriogram is performed with CO₂ and contrast medium for a roadmap before embolization.

CO₂ angiography can also provide excellent guidance during coil or plug embolization. However, because of its low viscosity, one needs to keep in mind that CO₂ angiographic assessment may underestimate the therapeutic effect of a coils pack.

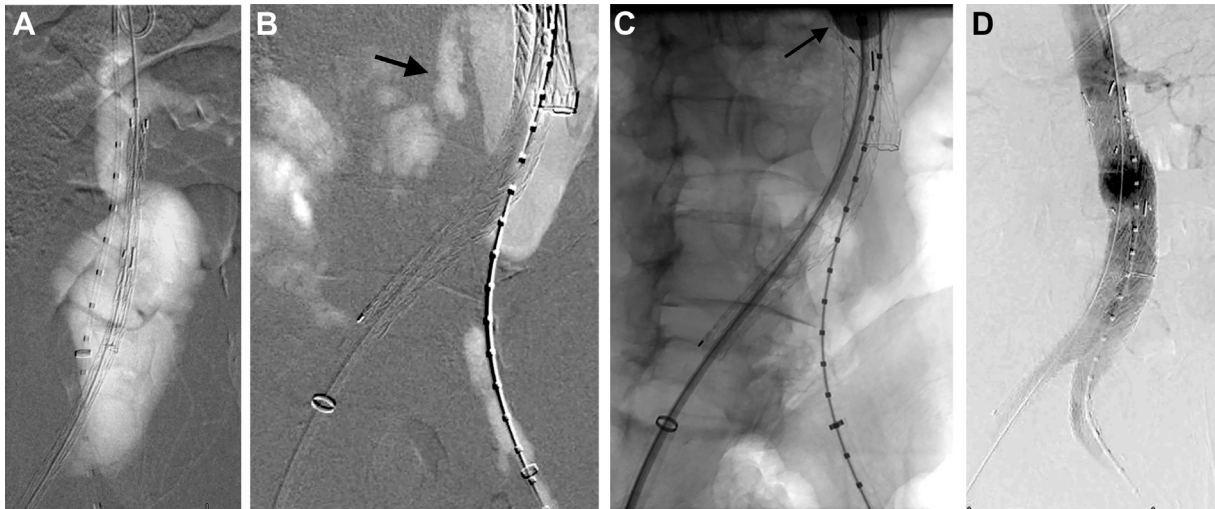

Fig 10. Patient presenting with a ruptured abdominal aortic aneurysm (AAA). **A**, Endograft positioning and deployment was conducted solely using carbon dioxide (CO₂) angiographic guidance. However, the patient suddenly developed hypotension after deployment of the main body. **B**, CO₂ aortogram shows frank extravasation of gas (*arrow*). **C**, A balloon endoclamp was promptly deployed to control bleeding (**D**) while the procedure was promptly completed.

CO₂ cannot be used to deliver a liquid embolic agent, although some approaches have been explored to increase the opacity of liquid embolic agents by mixing in a small amount of gadolinium or tungsten powder with polyvinyl alcohol embolic suspension.

Portal and splanchnic venous imaging and interventions. The routine use CO₂ guidance during TIPS has become widely accepted. The entire procedure, including wedge hepatic vein portography, portal localization, tract measurement, and final assessment after placement of TIPS, can be performed with CO₂.⁷ Using CO₂ also allows performance of TIPS using a fine-needle system (21 gauge compared with 16 gauge in conventional kits), which may be preferable in patients at high risk for hemorrhagic complications.³⁷

Wedged hepatic venography is a popular method for the evaluation of portal hypertension and portal vein patency as well as for guidance during TIPS. The low viscosity of CO₂ allows better assessment of the portal venous system compared with ICM, which can result in suboptimal filling in the setting of portal venous flow reversal in severe portal hypertension.

Splenoportography remains an important angiographic method for evaluating patients with cirrhosis and portal hypertension, especially in the pediatric age group, by eliminating the need for an arterial puncture. Trans-splenic CO₂ portography can be safely accomplished using a 25-gauge needle and allows excellent dynamic visualization of the splenoportal venous system and portosystemic collaterals.

Hemodialysis access planning and interventions. CO₂ venography has been shown to be highly reliable in vein mapping for planned arteriovenous access, especially

autogenous fistulas.¹⁴ CO₂ has also been used for evaluation of malfunctioning hemodialysis access conduits as well as during guidance of mechanical and pharmacomechanical declotting procedures of thrombosed hemodialysis grafts and native fistulas.³⁸ It can also be used for the evaluation of autogenous arteriovenous fistulas that have failed to mature, which can be valuable in patients who have not yet required hemodialysis and in whom ICM should be avoided. One needs to be very cautious while assessing the native arteriovenous anastomosis or arterial anastomosis of a prosthetic graft by the CO₂ reflux technique because of the potential for transient neurologic sequelae, attributed to proximal reflux of CO₂ into the vertebral arteries.

Endovascular AAA repair. There is now ample evidence that CO₂ can be used as primary contrast agent during EVAR, allowing >80% reduction in the amount of ICM used.^{9,39} The largest experience with EVAR using CO₂ guidance was published by Criado et al,⁹ who also described a method of CO₂ administration through the sidearm of the aortic endograft delivery sheath, a method termed “catheter-less” angiography. Although this method was described specifically using the Zenith system (Cook Medical, Bloomington, Ind), it can be applied to virtually any other system, including the Excluder system (W. L. Gore & Associates, Flagstaff, Ariz) with the use of a Tuohy-Borst Y-adaptor applied to the guidewire lumen. Although other options exist for EVAR without the use of ICM, such as intravascular ultrasound guidance, the benefits of conventional fluoroscopic guidance and the high expense of intravascular ultrasound imaging should be taken into consideration in those instances. One drawback of CO₂ guidance for

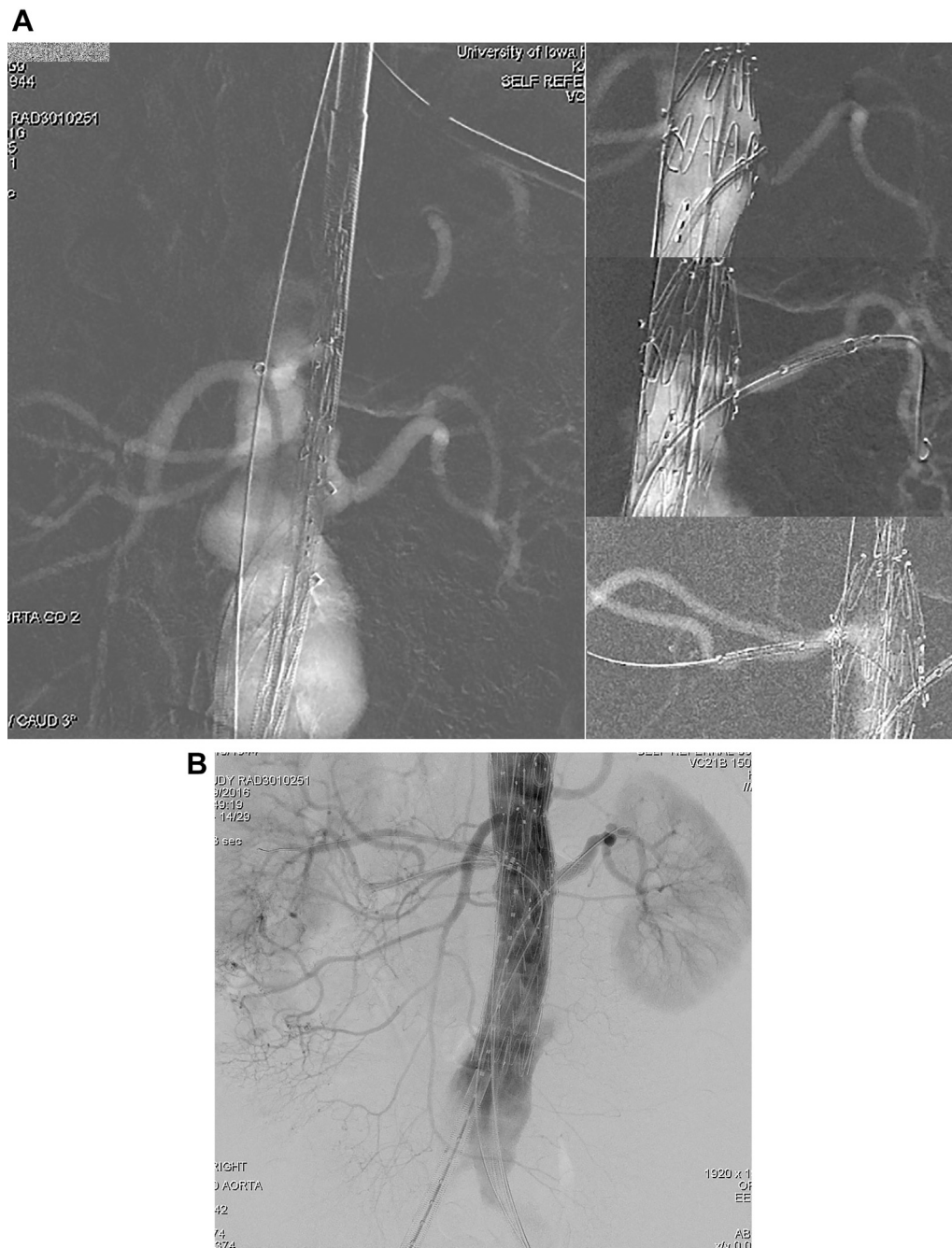


Fig 11. A, Carbon dioxide (CO₂) angiography used to guide device positioning and visceral alignment during fenestrated endovascular aneurysm repair (EVAR) procedure. **B,** Iodinated contrast medium (ICM) angiogram after completion of the fenestration part of the procedure.

EVAR is the potential for nonopacification of posterior renal arteries if the injecting catheter becomes pushed anteriorly by a partially deployed endograft, which can lead to error in estimating the position of the lowest renal artery.

EVAR in ruptured AAA. The use of CO₂ as primary imaging modality during EVAR of ruptured AAA has also been reported.⁴⁰ The obvious drawback is that it may require additional setup time. However, in operating

rooms well experienced with CO₂ imaging, especially when a reusable portable closed system is available, this modality can be readily used in ruptured AAA repair⁴⁰ (Fig 10). In addition to the lack of nephrotoxicity, CO₂ offers a number of unique advantages, including excellent filling of renal and mesenteric branches, even in patients with circulatory collapse. In the setting hemodynamically unstable AAA rupture where a proximal occlusion balloon has been deployed, the gas can be

easily administered through the sidearm of a sheath to guide accurate endoprosthesis positioning.

Complex endovascular aortoiliac interventions. The use of complex aortoiliac endografting procedures, including those with branched/fenestrated devices and parallel grafts, is increasing. These procedures are technically demanding and require complicated deployment sequences and a significantly higher volume of contrast compared with standard infrarenal EVAR.

There have been few reports on the use of CO₂ angiography during complex EVAR. However, our growing experience with the use of CO₂ angiography as a primary contrast agent during complex aortic endovascular interventions has found it to be a valuable tool. The use of CO₂ angiography reduces the volume of ICM used while allowing virtually unlimited intraoperative imaging to help with the conduct of the procedure. CO₂ readily allows visualization of stenosed or shuttered visceral branches during fenestrated and branched aortic endograft procedures (Fig 11).

Because of its ability to delineate visceral branches, CO₂ angiography may also be a valuable option for coregistration of renal and mesenteric arteries on the three-dimensional roadmap during the use of fusion imaging guidance in complex EVAR procedures.⁴¹

Endoleak detection. The low viscosity of CO₂ allows it to demonstrate an occult endoleak that may be intermittent or in a low-flow state, which results in non-visibility on conventional angiography. CO₂ has been reported to have high sensitivity and positive predictive value for types I and III endoleaks. However, owing to the exaggerated ability of CO₂ to diffuse through small branches, the positive predictive value for clinically relevant type II endoleaks is thought to be inferior to conventional digital subtraction angiography. It is worthwhile to note that the bulk of published reports on endoleak detection using CO₂ angiography described intraoperative data.^{6,8} Data on detecting persistent or delayed endoleaks are very limited.

Vascular malformations evaluation and intervention. One published study suggested a role for CO₂ angiography in the planning and intraprocedural assessment of residual malformation during embolization therapy. CO₂ is also valuable in the detection and management planning of traumatic arteriovenous communications.³⁴ Again, this is thought to result from the low viscosity of CO₂.

Interventional oncology applications. The main value of CO₂ in oncologic vascular imaging is its ability to detect abnormal vascular communications, such as arteriovenous shunting, which is useful for determining the optimal approach for transcatheter arterial injection.⁴² The low viscosity of CO₂ allows excellent visualization of the tumor vascular bed through a 3F microcatheter for superselective angiography and for delivery of embolic agents.

Evolving applications of CO₂: Microbubble enhancement and CTA. Microbubble CO₂ enhancement refers to a new approach aimed at optimizing imaging quality while reducing some of the complications seen with conventional CO₂ angiography. CO₂ gas is premixed with the patient's blood and dispersed into a bubble mixture before injection.⁴³ Preliminary reports suggest consistent improvement in image quality of CO₂ angiography. A similar approach was explored in the CO₂ microbubble generator through a cavitation effect. Although this approach generally produces inferior image quality compared with conventional CO₂, microbubble CO₂ enhancement has the advantages of lower neurotoxicity, avoidance of vapor lock type complications, and potential use as a CTA contrast agent.

Avoidance of ICM is an important goal in a patient population likely to require frequent follow-up angiographic imaging. CTA is perhaps the most widely used cross-sectional angiographic study and is a significant source of ICM exposure in this at-risk patient population. Newer applications have evaluated the potential role of CO₂ as alternative contrast agent during CTA. High-pitch CO₂-enhanced CTA using dual-source approaches may hold a great promise in the near future. A recent pilot study showed CO₂-enhanced CTA was technically feasible. It may be a good option in noninvasive/cross-sectional vascular imaging and may become a useful modality in post-EVAR follow-up.

CONCLUSIONS

CO₂ is a safe, inexpensive, and highly versatile intravascular contrast agent. It is non-nephrotoxic and nonallergenic and should be the contrast agent of choice for infradiaphragmatic angiographic imaging in patients with renal impairment or severe ICM allergy. Although CO₂ angiography is currently regarded as a complementary angiographic technique in high-risk patients, it possesses unique physical properties allowing it to complement or even totally replace ICM in several diagnostic and interventional applications.

CO₂ angiography is a valuable addition to the endovascular surgeon armamentarium. Proficiency with this technique is easy to gain, provided the operator invests the time to understand the particular physical and chemical characteristics of CO₂. Familiarity with digital imaging and availability of modern equipment are essential. Awareness of this technique's limitations and contraindications is critical, and the operator must develop a compulsive attention to details in to avoid air contamination, even when using a dedicated closed-system setup. It is mandatory to avoid using CO₂ intra-arterially in locations above the diaphragm. Avoiding explosive delivery and allowing appropriate delay between injections are other important safeguards. Strategies to enhance image quality and diagnostic yield are easy to acquire with experience, and most operators

will become quickly proficient. The list of applications for CO₂ angiography is long, and future developments may allow that list to grow.

AUTHOR CONTRIBUTIONS

Conception and design: MS

Analysis and interpretation: MS

Data collection: MS, AM

Writing the article: MS, AM

Critical revision of the article: MS

Final approval of the article: MS, AM

Statistical analysis: Not applicable

Obtained funding: Not applicable

Overall responsibility: MS

REFERENCES

- Brooks B. Intra-arterial injection of sodium iodid: preliminary report. *JAMA* 1924;82:1016-9.
- Barrera F, Durant T, Lynch P, Oppenheimer M, Stauffer H, Stewart G 3rd. In vivo visualization of intracardiac structures with gaseous carbon dioxide; cardiovascular-respiratory effects and associated changes in blood chemistry. *Am J Physiol* 1956;186:325-34.
- Hawkins I. Carbon dioxide digital subtraction arteriography. *AJR Am J Roentgenol* 1982;139:19-24.
- Rundback JH, Nahl D, Yoo V. Contrast-induced nephropathy. *J Vasc Surg* 2011;54:575-9.
- Hawkins I, Caridi J. Carbon dioxide (CO₂) digital subtraction angiography: 26-year experience at the University of Florida. *Eur Radiol* 1998;8:391-402.
- Huang SG, Woo K, Moos JM, Han S, Lew WK, Chao A, et al. A prospective study of carbon dioxide digital subtraction versus standard contrast arteriography in the detection of endoleaks in endovascular abdominal aortic aneurysm repairs. *Ann Vasc Surg* 2013;27:38-44.
- Caridi JG, Cho KJ, Fauria C, Eghbalieh N. Carbon dioxide digital subtraction angiography (CO₂ DSA): a comprehensive user guide for all operators. *Vasc Dis Manag* 2014;11: E221-56.
- Sueyoshi E, Nagayama H, Sakamoto I, Uetani M. Carbon dioxide digital subtraction angiography as an option for detection of endoleaks in endovascular abdominal aortic aneurysm repair procedure. *J Vasc Surg* 2015;61:298-303.
- Criado E, Upchurch GR Jr, Young K, Rectenwald JE, Coleman DM, Eliason JL, et al. Endovascular aortic aneurysm repair with carbon dioxide-guided angiography in patients with renal insufficiency. *J Vasc Surg* 2012;55:1570-5.
- Martin-Gonzalez T, Pinçon C, Maurel B, Hertault A, Sobocinski J, Spear R, et al. Renal outcomes following fenestrated and branched endografting. *Eur J Vasc Endovasc Surg* 2015;50:420-30.
- Boyle JR. Acute kidney injury predicts mortality after endovascular aortic repair. *Eur J Vasc Endovasc Surg* 2015;50:431.
- Prasad A. CO₂ angiography for peripheral arterial imaging: the good, bad, and ugly. *Catheter Cardiovasc Interv* 2015;85: 878-9.
- Cho KJ. Carbon dioxide angiography: scientific principles and practice. *Vasc Specialist Int* 2015;31:67-80.
- Cho K, Hawkins IF. Carbon dioxide angiography: principles, techniques, and practices. Boca Raton, FL: CRC Press; 2007.
- Krauss B, Hess DR. Capnography for procedural sedation and analgesia in the emergency department. *Ann Emerg Med* 2007;50:172-81.
- Cho KJ, Hawkins IF. Discontinuation of the plastic bag delivery system for carbon dioxide angiography will increase radiocontrast nephropathy and life-threatening complications. *AJR Am J Roentgenol* 2011;197:W940-1.
- Hawkins I Jr, Caridi J, Kerns S. Plastic bag delivery system for hand injection of carbon dioxide. *AJR Am J Roentgenol* 1995;165:1487-9.
- Caridi JG. Vascular imaging with carbon dioxide: confidence in a safe, efficacious, user-friendly system. *Semin Intervent Radiol* 2015;32:339-42.
- Abdulghaffar W, Elganayni F, Saleh HA, Abou-Issa AH, Abouelcibaa O. Role of carbon dioxide angiography in management of below knee arterial lesions. *Egypt J Radiol Nucl Med* 2012;43:549-54.
- Bees NR, Beese RC, Belli AM, Buckenham TM. Carbon dioxide angiography of the lower limbs: initial experience with an automated carbon dioxide injector. *Clin Radiol* 1999;54: 833-8.
- Palena LM, Diaz-Sandoval LJ, Candeo A, Brigato C, Sultato E, Manzi M. Automated carbon dioxide angiography for the evaluation and endovascular treatment of diabetic patients with critical limb ischemia. *J Endovasc Ther* 2016;23:40-8.
- Scalise F, Novelli E, Auguadro C, Casali V, Manfredi M, Zannoli R. Automated carbon dioxide digital angiography for lower-limb arterial disease evaluation: safety assessment and comparison with standard iodinated contrast media angiography. *J Invasive Cardiol* 2015;27:20-6.
- Micari A, Sbarzaglia P, Meeks M, Liso A, Riina M, Lunetto ML, et al. New imaging modalities in peripheral interventions. *Eur Heart J Suppl* 2015;17:A18-22.
- Moos JM, Ham SW, Han SM, Lew WK, Hua HT, Hood DB, et al. Safety of carbon dioxide digital subtraction angiography. *Arch Surg* 2011;146:1428-32.
- Caridi JG, Hawkins IF Jr. CO₂ digital subtraction angiography: potential complications and their prevention. *J Vasc Intervent Radiol* 1997;8:383-91.
- Rundback JH, Shah PM, Wong J, Babu SC, Rozenblit G, Poplasky MR. Livedo reticularis, rhabdomyolysis, massive intestinal infarction, and death after carbon dioxide arteriography. *J Vasc Surg* 1997;26:337-40.
- Mizuno A, Nishi Y, Niwa K. Total bowel ischemia after carbon dioxide angiography in a patient with inferior mesenteric artery occlusion. *Cardiovasc Interv Ther* 2013;29:243-6.
- Black CM, Lang EV, Kusnick CA, Siebes M, Barnhart W, Berbaum KS, et al. 1996 AUR Memorial Award. Densitometric analysis of eccentric vascular stenoses: comparison of CO₂ and iodinated contrast media. *Acad Radiol* 1996;3:985-93.
- Oliva VL, Denbow N, Thérassé É, Common AA, Harel C, Giroux MF, et al. Digital subtraction angiography of the abdominal aorta and lower extremities: carbon dioxide versus iodinated contrast material. *J Vasc Intervent Radiol* 1999;10:723-31.
- Rolland Y, Duvauferrier R, Lucas A, Gourlay C, Morcet N, Rambeau M, et al. Lower limb angiography: a prospective study comparing carbon dioxide with iodinated contrast material in 30 patients. *AJR Am J Roentgenol* 1998;171:333-7.
- Giordano A, Messina S, Polimeno M, Corcione N, Ferraro P, Biondi-Zoccai G, et al. Peripheral diagnostic and interventional procedures using an automated injection system for carbon dioxide (CO₂): case series and learning curve. *Heart Lung Vessel* 2015;7:18-26.
- Caridi JG, Stavropoulos SW, Hawkins IF. CO₂ digital subtraction angiography for renal artery angioplasty in high-risk patients. *AJR Am J Roentgenol* 1999;173:1551-6.
- Das CJ, Neyaz Z, Thapa P, Sharma S, Vashist S. Fibromuscular dysplasia of the renal arteries: a radiological review. *Int Urol Nephrol* 2007;39:233-8.

34. Hawkins IF, Cho KJ, Caridi JG. Carbon dioxide in angiography to reduce the risk of contrast-induced nephropathy. *Radiol Clin North Am* 2009;47:813-25.
35. Back MR, Caridi JG, Hawkins IF Jr, Seeger JM. Angiography with carbon dioxide (CO₂). *Surg Clin North Am* 1998;78:575-91.
36. Hawkins IF, Caridi JG, Wiechmann BN, Kerns SR. Carbon dioxide (CO₂), digital subtraction angiography in trauma patients. *Semin Intervent Radiol* 1997;14:175-80.
37. Hawkins I Jr, Caridi J. Fine-needle transjugular intrahepatic portosystemic shunt procedure with CO₂. *AJR Am J Roentgenol* 1999;173:625-9.
38. Ehrman KO, Taber TE, Gaylord GM, Brown PB, Hage JP. Comparison of diagnostic accuracy with carbon dioxide versus iodinated contrast material in the imaging of hemodialysis access fistulas. *J Vasc Intervent Radiol* 1994;5:771-5.
39. Chao A, Major K, Kumar SR, Patel K, Trujillo I, Hood DB, et al. Carbon dioxide digital subtraction angiography–assisted endovascular aortic aneurysm repair in the azotemic patient. *J Vasc Surg* 2007;45:451-60.
40. Knipp BS, Escobar GA, English S, Upchurch GR Jr, Criado E. Endovascular repair of ruptured aortic aneurysms using carbon dioxide contrast angiography. *Ann Vasc Surg* 2010;24:845-50.
41. Ahmad W, Gawenda M, Brunkwall S, Shahverdyan R, Brunkwall JS. Endovascular aortoiliac aneurysm repair with fenestrated stent graft and iliac side branch using image fusion without iodinated contrast medium. *Ann Vasc Surg* 2016;33:e5-9.
42. Teshima Y, Iwasaki N. Efficacy of CO₂-DSA in embolization. *Cancer Chemother Pharmacol* 1994;33:S109-10.
43. Chang TI, Chan CY, Su SK, Wang SS, Wu IH. A novel bubble-mixture method to improve dynamic images in carbon dioxide angiography. *J Endovasc Ther* 2015;22:564-7.

Submitted Sep 28, 2016; accepted Mar 27, 2017.