

U.S. copyright law (title 17 of U.S. code) governs the reproduction and redistribution of copyrighted material.



ILLiad TN: 3331427

**Borrower:** FLUFLO

**Lending String:**

**Patron:** Daugherty(UF), Ms. Judy

**Journal Title:** JBR-BTR ; organe de la Société royale belge de radiologie (SRBR) = orgaan van de Koninklijke Belgisc

**Volume:** 82 **Issue:** 2  
**Month/Year:** 1999**Pages:** 74

**Article Author:** Ketelslegers E; Goffette P; Pringot J

**Article Title:** Demonstration of post-traumatic hepatic hemorrhage

**Imprint:**

**ILL Number:** 27357122



**COPYRIGHT NOTICE**

The copyright law of the United States (title 17, United States Code) governs the making of photocopies or other reproductions of copyrighted material. Under certain conditions specified in the law, libraries and archives are authorized to furnish a photocopy or other reproduction. One of these specific conditions is that the photocopy or reproduction is not to be 'used for any purpose other than private study, scholarship, or research.' If a user makes a request for, or later uses, a photocopy or reproduction for purposes in excess of 'fair use,' that user may be liable for copyright infringement. This institution reserves the right to refuse to accept a copying order if, in its judgment, fulfillment of the order would involve violation of copyright law.

**Call #:**

**Location:**

R

**ARIEL**

**Charge**

**Maxcost:** \$25.00/\$30 EFTS

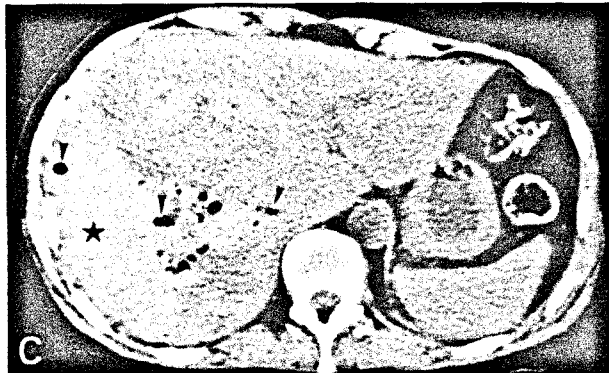
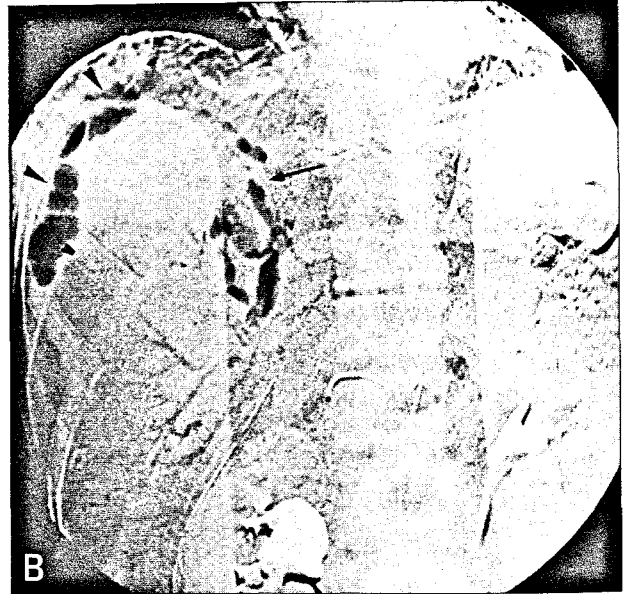
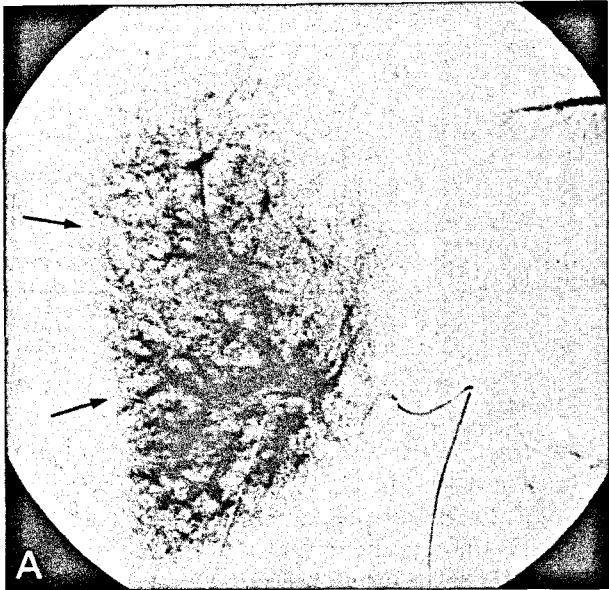
**Shipping Address:**

University of Florida  
Health Science Center Library  
Document Delivery Department  
1600 SW Archer Rd.  
Gainesville, FL 32610-0206

**Odyssey:**

**Ariel:** 159.178.76.49

## IMAGES IN CLINICAL RADIOLOGY



*Demonstration of post-traumatic hepatic hemorrhage with carbon dioxide digital subtraction angiography*

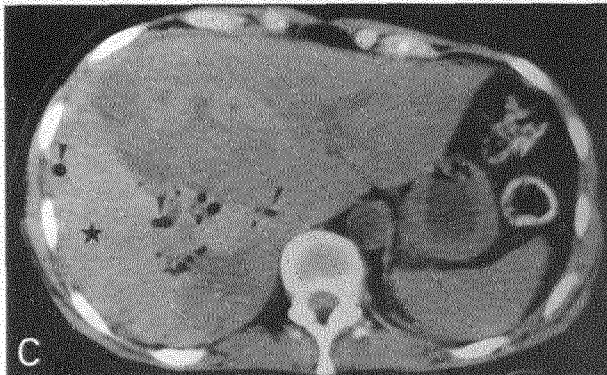
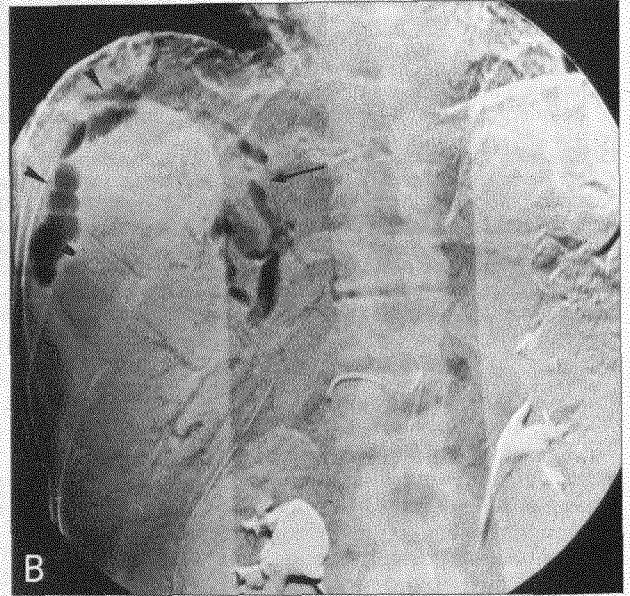
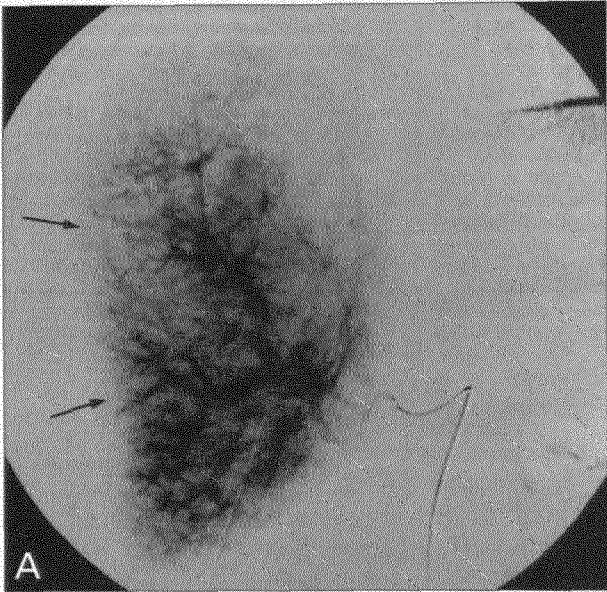
A 53-year-old woman was referred to our hospital for evaluation of right hepatic masses. Because hepatocellular carcinoma was suspected, she underwent laparoscopic exploration. Five needle biopsy samples of the main lesion located in the dome of the right liver were obtained.

Her postoperative course was complicated at 8 hours by a severe hypovolemic shock. A hepatic digital subtraction angiography was performed. Nonionic iodinated contrast media injections identified a smooth pressure defect on the right hepatic lobe but failed to demonstrate the bleeding site (Fig. 1A, arrows). Carbon dioxide (CO<sub>2</sub>) angiography (Fig. 1B) clearly showed arterial bleeding (arrow) from the dome of the right peri-hepatic space (arrowheads). Right hepatic embolization with gelfoam pledges resulted in complete cessation of the hemorrhage. Unenhanced computed tomography (Fig. 1C) confirmed the presence of a right peri-hepatic hematoma (star) and showed the presence of gas bubbles in the right liver and within the hematoma (arrowheads).

CO<sub>2</sub> is a safe alternative contrast agent to iodine. As CO<sub>2</sub> permits visualization of minute amounts of arterial bleeding, ongoing hemorrhage may be seen only with CO<sub>2</sub> in some instances.

E. Ketelslegers, P. Goffette, J. Pringot  
Department of Radiology,  
Cliniques Universitaires St. Luc,  
B-1200 Bruxelles, Belgium

## IMAGES IN CLINICAL RADIOLOGY



*Demonstration of post-traumatic hepatic hemorrhage with carbon dioxide digital subtraction angiography*

A 53-year-old woman was referred to our hospital for evaluation of right hepatic masses. Because hepatocellular carcinoma was suspected, she underwent laparoscopic exploration. Five needle biopsy samples of the main lesion located in the dome of the right liver were obtained.

Her postoperative course was complicated at 8 hours by a severe hypovolemic shock. A hepatic digital subtraction angiography was performed. Nonionic iodinated contrast media injections identified a smooth pressure defect on the right hepatic lobe but failed to demonstrate the bleeding site (Fig. 1A, arrows). Carbon dioxide (CO<sub>2</sub>) angiography (Fig. 1B) clearly showed arterial bleeding (arrow) from the dome of the right peri-hepatic space (arrowheads). Right hepatic embolization with gelfoam pledges resulted in complete cessation of the hemorrhage. Unenhanced computed tomography (Fig. 1C) confirmed the presence of a right peri-hepatic hematoma (star) and showed the presence of gas bubbles in the right liver and within the hematoma (arrowheads).

CO<sub>2</sub> is a safe alternative contrast agent to iodine. As CO<sub>2</sub> permits visualization of minute amounts of arterial bleeding, ongoing hemorrhage may be seen only with CO<sub>2</sub> in some instances.

E. Ketelslegers, P. Goffette, J. Pringot  
Department of Radiology,  
Cliniques Universitaires St. Luc,  
B-1200 Bruxelles, Belgium