

Use of a Compression Paddle to Displace Bowel Gas for Carbon Dioxide Digital Subtraction Angiography¹

Eric S. Stram, MD
Christopher P. Molgaard, MD

DURING the past several years, carbon dioxide digital subtraction angiography (CO₂ DSA) has become accepted as a valuable diagnostic tool, primarily for patients with renal insufficiency or iodinated contrast medium allergy (1–6). The applications have expanded as digital subtraction imaging equipment has improved and angiographers have become more familiar with the use of CO₂ as a contrast agent (4–7). CO₂ DSA requires high-quality digital subtraction imaging because of the limited contrast differential between the injected CO₂ gas and the overlying tissues. Computerized techniques such as pixel shifting, image stacking, and edge enhancement can improve detail (3–5). Even slight motion of gas-filled bowel loops due to peristalsis or diaphragmatic motion can degrade diagnostic detail in abdominal and pelvic CO₂ DSA (4). Catheter repositioning, oblique projections, breath holding, and intravenous glucagon can minimize motion artifact from overlying bowel gas (3,5,8). Despite these techniques, it can still be difficult to obtain diagnostic quality detail. We describe a technique in which a gastrointestinal (GI) compression paddle is used to displace bowel gas for improved CO₂ DSA image quality.

nal wall with a GI compression paddle, similar to the technique used for barium studies of the GI tract. The compression paddle is held by hand with a lead glove while standing behind a protective screen. Alternatively, a balloon-type paddle is inflated and placed on the patient's abdomen and then the image intensifier is gently lowered onto the paddle to hold it in position (**Fig 1**). Fluoroscopy is used as the image intensifier is lowered to check the position of the paddle and to visualize the minimum amount of pressure required to displace overlying bowel loops. Enough pressure is applied to displace bowel away from the vessels of interest without compressing the underlying arteries. The compression device must be held as motionless as possible so that it will be subtracted during filming. When the paddle is in place, CO₂ angiography is performed. We use a rapid manual injection of a 50-mL CO₂ bolus while filming at a rate of four images per second.

• Case 1

An 81-year-old man with right foot ischemia was referred for a right leg runoff arteriogram and possible right iliac artery angioplasty/stent placement. The referring surgeon wanted to optimize inflow for an anticipated femoral-distal bypass procedure. Pelvic magnetic resonance angiography (MRA) was attempted, but the images were suboptimal due to patient motion. The patient had severe chronic ob-

Index terms: Angiography, contrast media • Angiography, technology

JVIR 1999; 10:405–408

¹ From the Department of Diagnostic Radiology, Lahey Clinic, 41 Mall Road, Burlington, MA 01805. Received June 22, 1998; revision requested July 27; revision received and accepted September 28. Address correspondence to C.P.M.

© SCVIR, 1999

MATERIALS AND METHODS

• Technique

The technique requires external compression of the anterior abdomi-

April 1999 JVIR

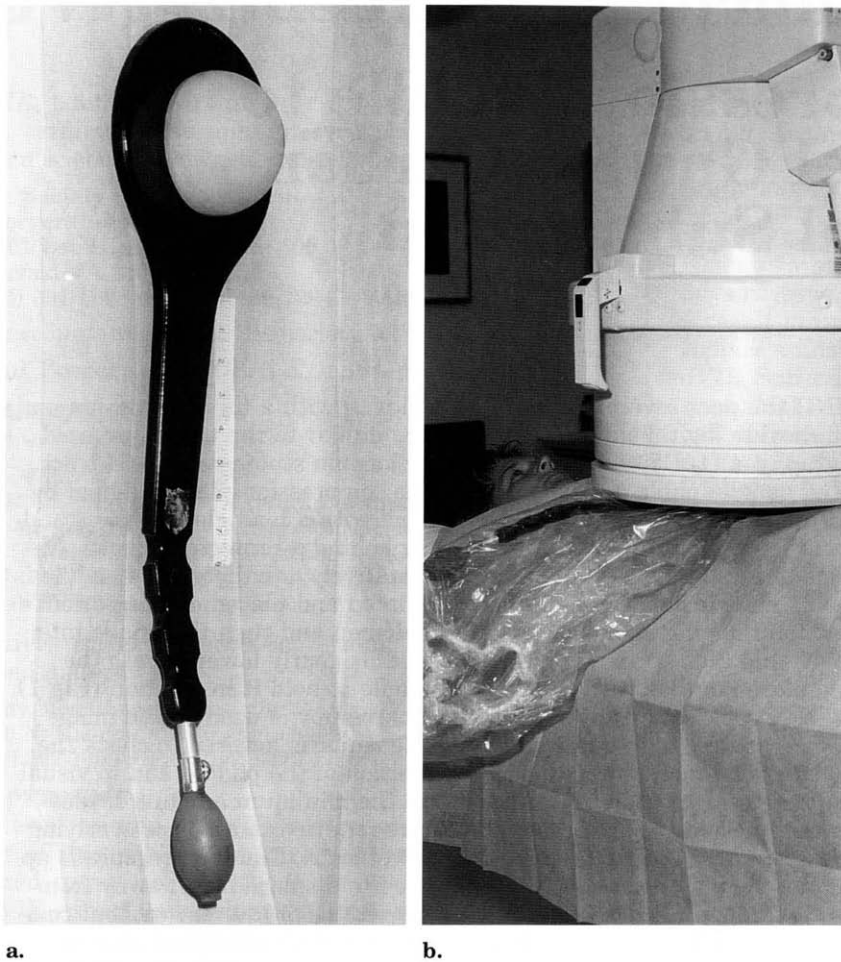

Figure 1. (a) Balloon-type compression paddle with a 4-inch-diameter (10 cm) balloon. (b) Simulated angiography patient with the balloon paddle held in place by the image intensifier.

structive pulmonary disease (COPD) and was unable to suspend respiration. Because of underlying chronic renal insufficiency, CO₂ DSA was used to evaluate the abdominal aorta and right iliac arterial system. A large amount of small bowel gas was present in the pelvis. The patient was tachypneic at baseline and unable to suspend respiration during imaging. The bowel gas moved with each diaphragmatic excursion, resulting in subtraction artifact despite lack of peristalsis. Despite using catheter repositioning and repeated imaging in multiple obliquities, the right iliac arterial system was not adequately visualized (**Fig 2a**).

We then used a hand-held GI compression paddle to displace

bowel gas from the right iliac region, and CO₂ DSA was repeated. The right iliac artery was then well visualized with only a mild stenosis (**Fig 2b**). There was no pressure gradient across this segment, and no intervention was performed.

• Case 2

A 33-year-old man with hypertension and renal insufficiency was referred for arteriography to rule out renal artery stenosis. The serum creatinine level was 2.8 mg/dL (247.5 μ mol/L). CO₂ DSA was performed to evaluate the renal arteries. Bowel gas in the mid abdomen partially obscured the proximal left renal artery (**Fig 3a**). The study was repeated with a GI compression

paddle positioned to displace the overlying bowel gas. The renal arteries were then well visualized and appeared normal (**Fig 3b**).

This technique has been used in eight cases without patient discomfort or complication. In six of the cases, no iodinated or gadolinium-based contrast was required. In one of the other cases, 20 mL of dilute iodinated contrast material was used to evaluate iliac artery stent placement. In the other case, 30 mL of dilute gadolinium-based contrast material was used for a more detailed evaluation of a stent placed for ostial renal artery stenosis.

DISCUSSION

Angiography performed with use of iodinated contrast material is the gold standard for imaging arterial anatomy in the abdomen and pelvis. Because of its noninvasive nature, MRA is an excellent alternative, especially in patients with iodinated contrast allergy and renal failure (8,9). Continued improvement in MRA image quality and availability will decrease the need for purely diagnostic CO₂ DSA examinations. However, CO₂ DSA will continue to be a useful adjunct for guiding endovascular interventions (2,6). It will also remain useful in evaluating arterial segments with metal stents, which are limited by artifact on MRA studies.

Motion artifact from overlying bowel gas in CO₂ DSA studies can limit angiographic detail, most commonly in the renal and common iliac arteries. Preprocedure overnight fasting, intravenous glucagon, oblique positioning, and catheter repositioning will usually allow diagnostic quality imaging of the arteries in question. However, sometimes a segment of the artery cannot be adequately visualized despite these techniques. This may then require the use of dilute nonionic (or gadolinium-based) contrast material to visualize the arterial segment. Even small amounts of iodinated contrast material used as an adjunct to CO₂ DSA procedures can result in deterioration of renal func-

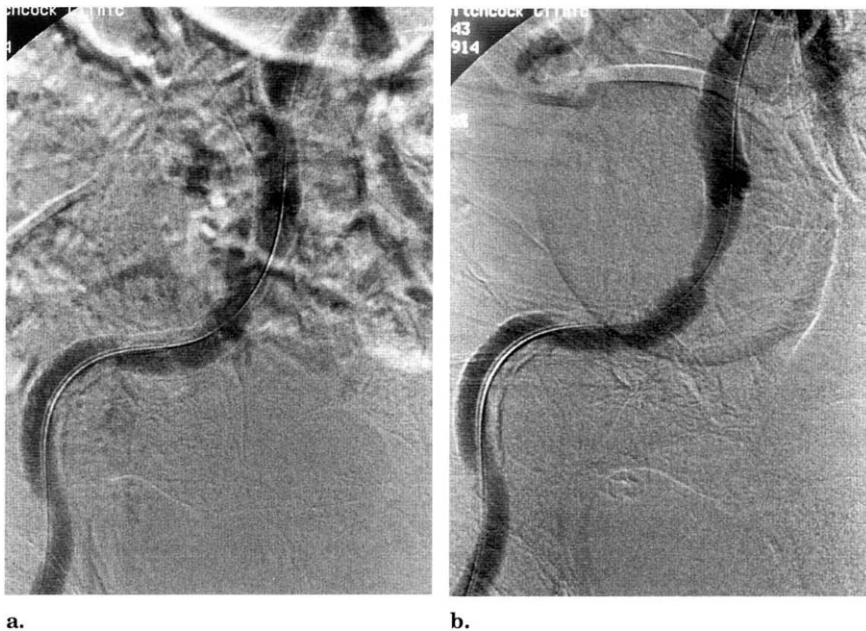


Figure 2. (a) CO₂ DSA of the right iliac arterial system in an anteroposterior projection. Image quality is degraded by respiratory motion, which caused subtraction artifact in bowel loops overlying the right iliac arterial system. (b) CO₂ DSA with GI compression paddle in place. The bowel gas has been displaced, and the right iliac arterial system is better visualized with only a mild stenosis present.

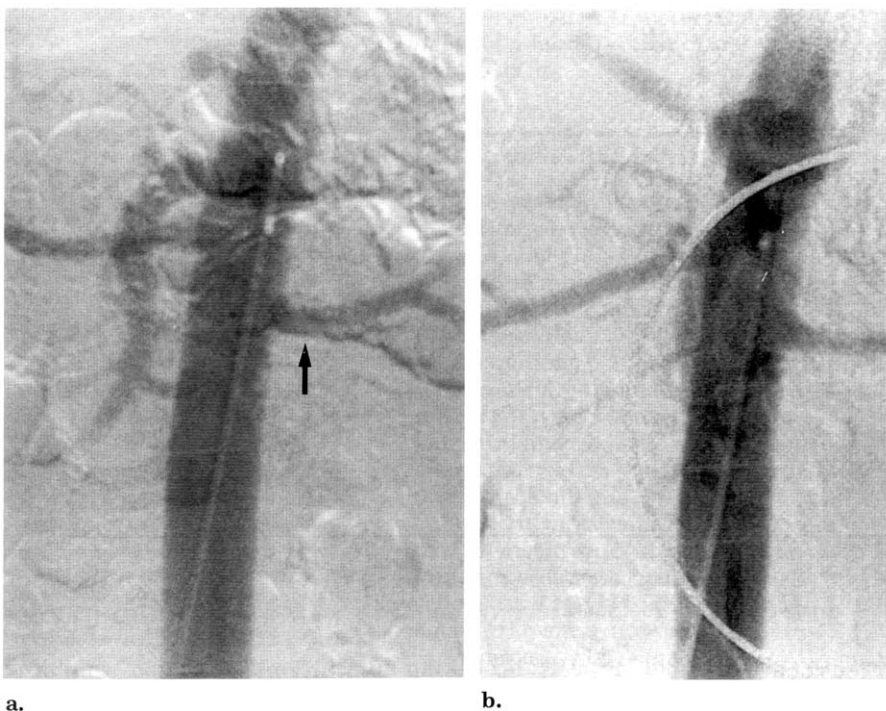


Figure 3. (a) CO₂ DSA of the aorta and renal arteries. The inferior margin of the left renal artery is not well visualized due to artifact from bowel gas (arrow). (b) CO₂ DSA of the aorta and renal arteries with the GI compression paddle. The proximal left renal artery and the majority of the right renal artery are now better visualized.

tion (2). Use of a GI compression paddle to displace the overlying bowel gas has nearly always eliminated the need for iodinated contrast material in our cases. Also, examination time and radiation exposure have been decreased, as there is less often a need for the multiple oblique projections previously required to clear an arterial segment obscured by overlying bowel gas.

Our technique is similar to that previously described for intravenous DSA studies of the renal arteries, in which a urographic compression device is used to displace bowel gas away from the renal arteries (10). The 10-cm-diameter compression paddle we have used has been of adequate size in our cases. However, the larger size of an intravenous urogram abdominal compression device may be beneficial if gas is obscuring a larger field, such as the area over both renal arteries. Our technique may also be useful when dilute gadolinium is used as the contrast agent, as preliminary data show there is relatively lower attenuation and bowel gas may interfere with image quality (11,12).

References

1. Yusuf SW, Whitaker SC, Hinwood D, et al. Carbon dioxide: an alternative to iodinated contrast media. *Eur J Vasc Endovasc Surg* 1995; 10:156-161.
2. Weaver FA, Pentecost MJ, Yellin AE, Davis S, Finck E, Teitelbaum G. Clinical applications of carbon dioxide/digital subtraction arteriography. *J Vasc Surg* 1991; 13:266-273.
3. Hawkins IF, Caridi JG. CO₂ digital subtraction arteriography: advantages and current solutions for delivery and imaging. *Cardiovasc Intervent Radiol* 1995; 18:150-152.
4. Schreier DZ, Weaver FA, Frankhouse J, et al. A prospective study of carbon dioxide-digital subtraction vs standard contrast arteriography in the evaluation of renal arteries. *Arch Surg* 1996; 131:503-508.
5. Yang X, Manninen H, Soimakallio S. Carbon dioxide in vascular imaging and intervention. *Acta Radiol* 1995; 36:330-337.
6. Frankhouse JH, Ryan MG, Papanicolaou G, Yellin AE, Weaver FA. Carbon dioxide/digital subtraction arteriography-assisted translum-

- minal angioplasty. *Ann Vasc Surg* 1995; 9:448-452.
7. Kerns SR, Hawkins IF. Carbon dioxide digital subtraction angiography: expanding applications and technical evolution. *AJR* 1995; 164: 735-741.
 8. Snidow JJ, Johnson MS, Harris VJ, et al. Three-dimensional gadolinium-enhanced MR angiography for aortoiliac inflow assessment plus renal artery screening in a single breath hold. *Radiology* 1996; 198: 725-732.
 9. Prince MR, Narasimham DL, Stanley JC, et al. Breath-hold gadolinium-enhanced MR angiography of the abdominal aorta and its major branches. *Radiology* 1995; 197:785-792.
 10. Hillman BJ, Ovitt TW, Capp MP, et al. Renal digital subtraction angiography: 100 cases. *Radiology* 1982; 145:643-646.
 11. Kaufman JA, Geller SC, Waltman AC. Renal insufficiency: gadopentetate dimeglumine as a radiographic contrast agent during peripheral vascular interventional procedures. *Radiology* 1996; 198:579-581.
 12. Matchett WJ, McFarland DR, Russell DK, et al. Gadopentetate dimeglumine as a contrast agent at digital subtraction angiography. *Radiology* 1996; 201:569-571.

Call for Editor

The Society of Cardiovascular & Interventional Radiology (SCVIR) is seeking applications for the position of *JVIR* Editor-in-Chief. This position will become available in 2000 when the current Editor concludes his term. Qualified candidates must be a practicing interventional radiologist and an active SCVIR member with considerable experience in writing, editing, or reviewing scientific articles for publication.

Interested individuals should contact Tricia McClenny, SCVIR Headquarters Office, 10201 Lee Highway, Suite 500, Fairfax, VA 22030. Telephone (703)691-1805 for application materials. Deadline for receipt of completed applications is July 1, 1999.