

The Use of Carbon Dioxide Wedged Hepatic Venography to Identify the Portal Vein: Comparison with Direct Catheter Portography with Iodinated Contrast Medium and Analysis of Predictive Factors Influencing Level of Opacification

Geert Maleux, MD, Frederik Nevens, MD, PhD, Sam Heye, MD, Chris Verslype, MD, PhD, and Guy Marchal, MD, PhD

PURPOSE: This study was conducted to assess the value of wedged hepatic venography (WHV) with CO₂ as a contrast agent for identification of the portal venous system in patients with cirrhosis. Additionally, the predictive value of several parameters that potentially influence the level of portal vein opacification by CO₂ WHV was analyzed.

MATERIALS AND METHODS: In 163 patients, CO₂ WHV was performed before transjugular intrahepatic portosystemic shunt creation to opacify and map the portal vein for subsequent targeting by intrahepatic puncture technique. Concordance between CO₂ WHV and direct catheter portography with iodinated contrast medium was assessed by analysis of sensitivity parameters. Additionally, analysis of factors potentially influencing the opacification of the portal vein with use of CO₂ WHV was assessed.

RESULTS: CO₂ WHV was successfully performed in all 163 patients. In three patients (1.8%), CO₂ extravasation was noted, but without any clinical consequence. Sensitivity rates of CO₂ WHV for opacification of the right and left portal veins and the portal main trunk were 93.83% and 68.52%, respectively. Positive predictive factors ($P < .05$, Wilcoxon two-sample test) were high portosystemic gradient, spontaneous splenorenal shunt, esophageal varices, and reversed portal flow. One negative predictive factor was a patent umbilical vein.

CONCLUSIONS: CO₂ WHV is safe, highly efficient, and reliable in the identification of the right and left portal veins. CO₂ WHV is clearly less effective in opacifying the entire portal main trunk. With use of CO₂ WHV, the portal venous system is most distinctly opacified in patients presenting with a high portosystemic gradient, a spontaneous splenorenal shunt, esophageal varices, and reversed portal flow.

J Vasc Interv Radiol 2006; 17:1771-1779

Abbreviations: MPV = main portal vein, TIPS = transjugular intrahepatic portosystemic shunt, WHV = wedged hepatic venography

ASSESSMENT of patency of the portal venous system can be performed by

From the Departments of Radiology (G.M., S.H., G.M.) and Hepatology (F.N., C.V.), University Hospitals Gasthuisberg, Herestraat 49, B-3000 Leuven, Belgium. Received February 28, 2006; revision requested May 16; final revision received July 13; and accepted August 6. Address correspondence to G.M.; E-mail: geert.maleux@uz.kuleuven.ac.be

None of the authors have identified a conflict of interest.

© SIR, 2006

DOI: 10.1097/01.RVI.0000242185.26944.60

different radiologic examinations. Historically, indirect portography after catheterization of the splenic or superior mesenteric artery was the method of choice (1), but today it has been largely replaced by noninvasive methods like duplex ultrasonography (US), computed tomography (CT), and magnetic resonance (MR) imaging (2-4). Wedged hepatic venography (WHV) with CO₂ as contrast medium has been suggested as another efficient imaging tool to demonstrate the portal vein and end branches before tran-

sjugular intrahepatic portosystemic shunt (TIPS) creation (5-8) or to use as part of an "all-in-one" invasive diagnostic workup to evaluate liver cirrhosis and portal hypertension-related symptoms (9,10).

The aim of the present study was to investigate the efficacy of WHV with CO₂ in demonstrating the main portal vein (MPV) and intrahepatic end branches compared with direct catheter portography with iodinated contrast medium. Additionally, several parameters were analyzed to deter-

mine the potential predictive value of portal vein opacification by CO₂ WHV.

MATERIALS AND METHODS

Study Population

Approval by the institutional review board is not required for retrospective studies such as this in the authors' institution.

From January 1998 to October 2005, 163 consecutive CO₂ WHV procedures, each preceding TIPS creation, were performed in our institution. There were 118 men and 45 women, with a mean age of 56.7 ± 11.7 years (SD). Sixty-eight patients (41.72%) with uncontrollable or recurrent variceal bleeding, 69 patients (42.33%) with refractory ascites, 20 patients (12.27%) with hepatic hydrothorax with or without concomitant refractory ascites, and six patients (3.67%) with known but uncomplicated portal hypertension were scheduled for gastrointestinal surgery. Assessment of Child-Pugh class was performed before TIPS creation in all patients. The underlying liver diseases included alcoholic liver cirrhosis ($n = 117$), non-alcoholic steatohepatitis ($n = 5$), hepatitis C ($n = 15$), granulomatous hepatitis ($n = 1$), hemochromatosis ($n = 1$), hepatitis B ($n = 3$), polycystic liver disease ($n = 1$), toxic hepatitis ($n = 3$), venoocclusive disease ($n = 5$), primary biliary sclerosis ($n = 5$), sclerosing cholangitis ($n = 1$), isolated thrombosis ($n = 1$), and hilar cholangiocarcinoma in a liver transplant recipient ($n = 1$).

Technique of CO₂ WHV and Direct Portography

Percutaneous access was made by puncture of the right internal jugular vein, and catheterization of the right hepatic vein was performed with a 4-F or 5-F Cobra-shaped catheter (Hoogewoud 5-F or SlipCath 4-F; William Cook Europe, Bjaeverskov, Denmark) and a 0.035-inch guide wire (Glide Wire; Terumo Europe, Leuven, Belgium). Before the imaging studies were performed, pressure measurements in the right atrium, which were considered to represent the systemic pressure, were assessed. The diagnos-

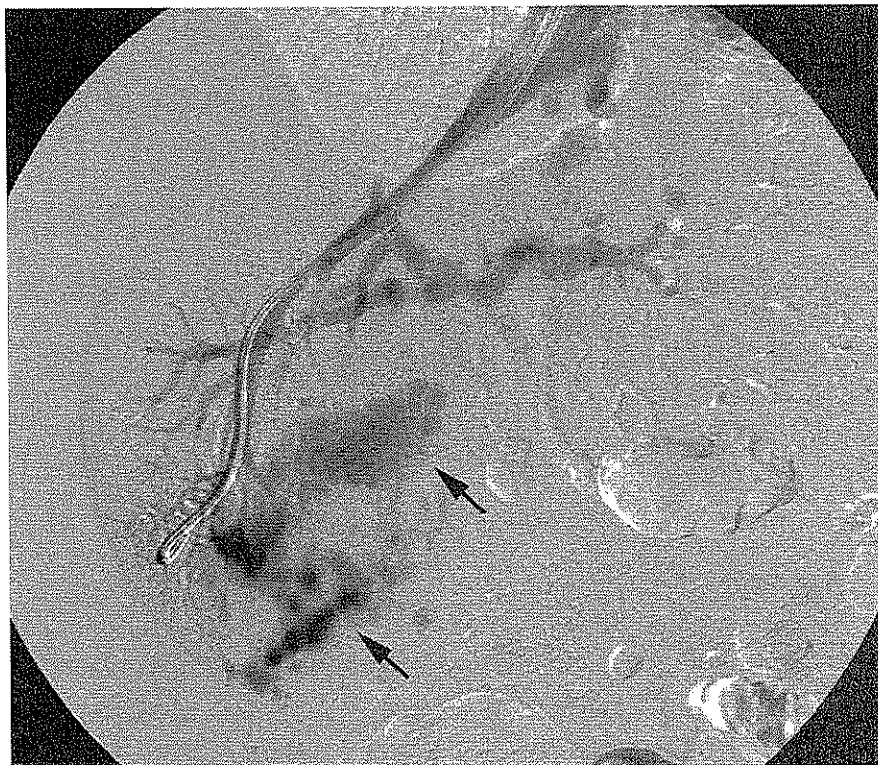

Figure 1. CO₂ WHV in a 43-year-old man who presented with refractory ascites and concomitant hepatic hydrothorax clearly shows extravasation of CO₂ bubbles (arrows) projecting over the right liver lobe.

tic catheter was placed as deep as possible in a right hepatic vein end branch to obtain a complete wedge position. No occlusion balloon was used. Injection of CO₂ was performed manually or automatically, respectively, with a hand-injection system consisting of a syringe with a three-way stopcock connected with a CO₂ tank and the catheter (CO₂ Angioset; Optimed, Ettlingen, Germany) or with an automated CO₂ injector (CO₂nnect; Angiodynamics, Queensbury, NY). With both systems, the first injection was performed with a small amount of CO₂ injected: 20 mL with the manual system and 30 mL with the automated system. All imaging series were performed with the patient under apnea and were made in an anteroposterior projection. If the portal venous system was not completely opacified with CO₂, additional series were performed with the amounts of CO₂ increased by 20 mL but never exceeding 80 mL of CO₂ in the same series.

The last indirect CO₂ portogram obtained was then used as a roadmap to

guide the intrahepatic puncture from the right hepatic vein into the portal venous system. When a catheter was brought into the MPV, hand-injected direct portography with 10 mL of iodinated contrast medium (iohexanol [Omnipaque 240] or iodixanol [Visipaque 270]; Amersham, Wemmel, Belgium) was performed. In all procedures, this amount of contrast medium was enough to obtain adequate opacification of the portal venous system, and subsequently this technique could be considered the gold standard for portal vein opacification. Then, direct pressure measurements in the MPV were assessed subsequently, and creation of a portosystemic shunt was performed as previously described (11).

Study Design

In the first part of the study, the sensitivity of CO₂ WHV to visualize the different levels of the portal venous system was studied. Therefore, a scoring system was used: a score of 0 indicated that no portal vein branch at

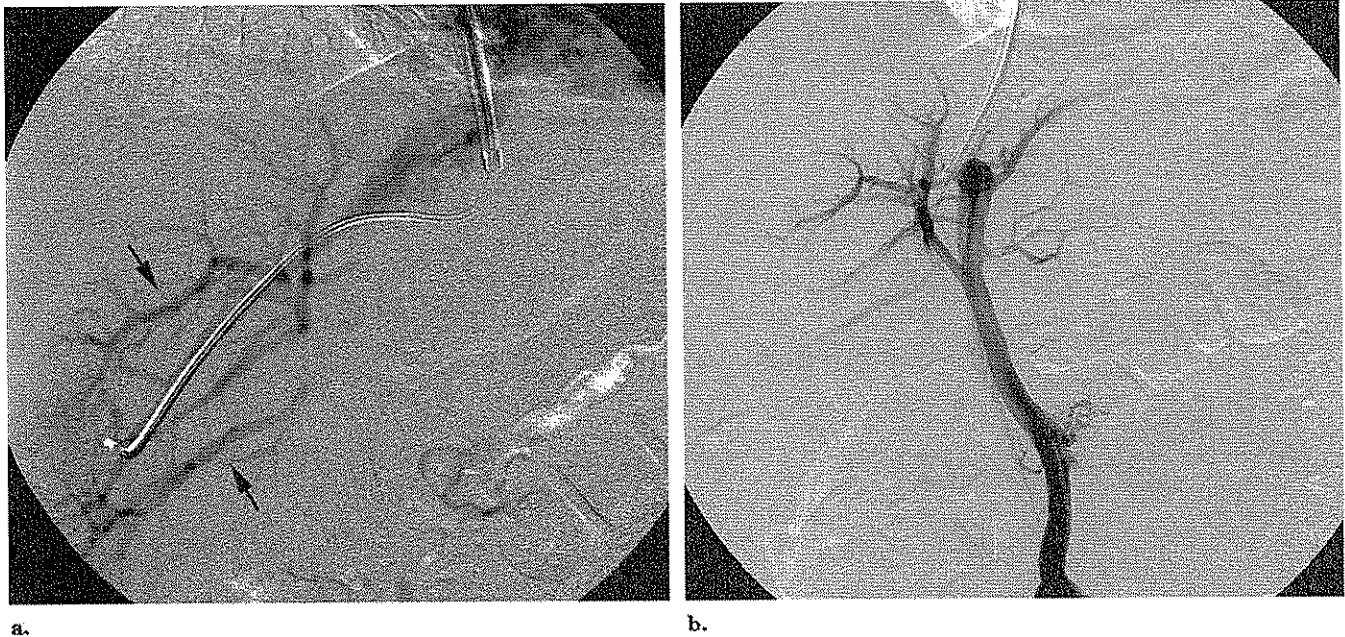


Figure 2. CO₂ WHV (a) in an 80-year-old woman who presented with recurrent variceal bleeding and hepatitis C virus–induced liver cirrhosis shows opacification of the end branches of the right portal vein (arrows) but no opacification of the right portal main branch. The corresponding direct catheter portography with iodinated contrast medium (b) shows a fully patent portal venous system including the portal main trunk and right and left portal veins and end branches.

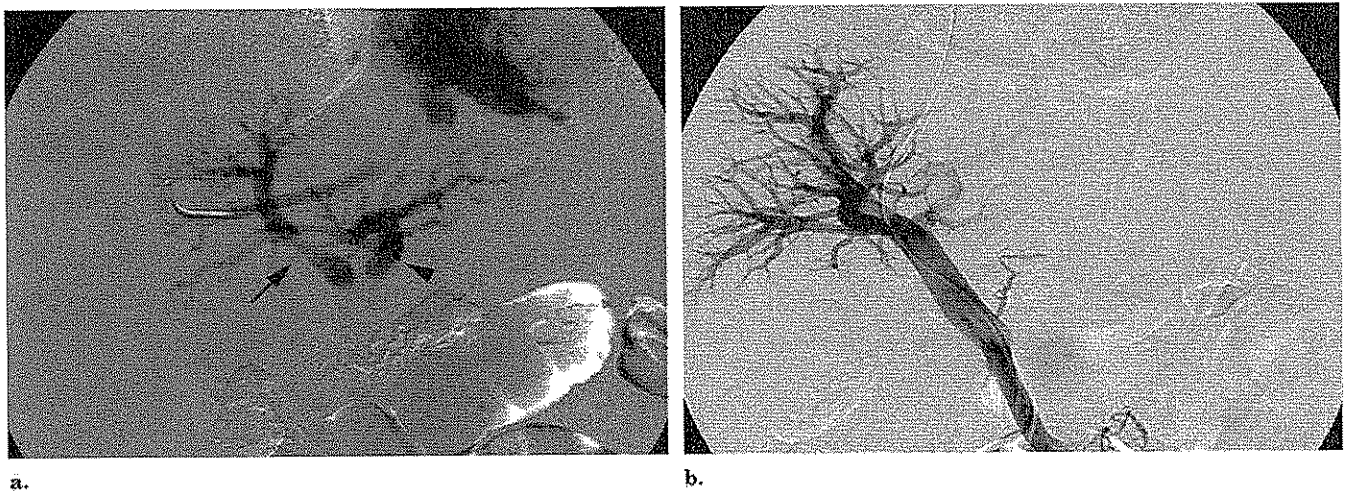


Figure 3. CO₂ WHV (a) in a 79-year-old man who presented with refractory ascites reveals a patent right (arrow) and left (arrowhead) portal vein and end branches. The corresponding direct portography with iodinated contrast medium (b) demonstrates a fully patent portal venous system.

all was revealed, a score of 1 indicated opacification of distal branches of the right portal vein but no opacification of the main right portal vein, a score of 2 indicated opacification of the main right portal vein and its end branches, a score of 3 indicated opacification of

right and left portal veins and end branches but no opacification of the MPV, and a score of 4 indicated opacification of the patent MPV and its right and left branches. Additionally, in case of MPV opacification by CO₂ WHV, a distinction was made be-

tween complete and incomplete opacification (ie, suggesting an underlying stenosis). All CO₂ WHV studies were reviewed in one sitting, and the contrast venograms were reviewed in another by two interventional radiologists (G.M. and S.H.) with 15 and 8

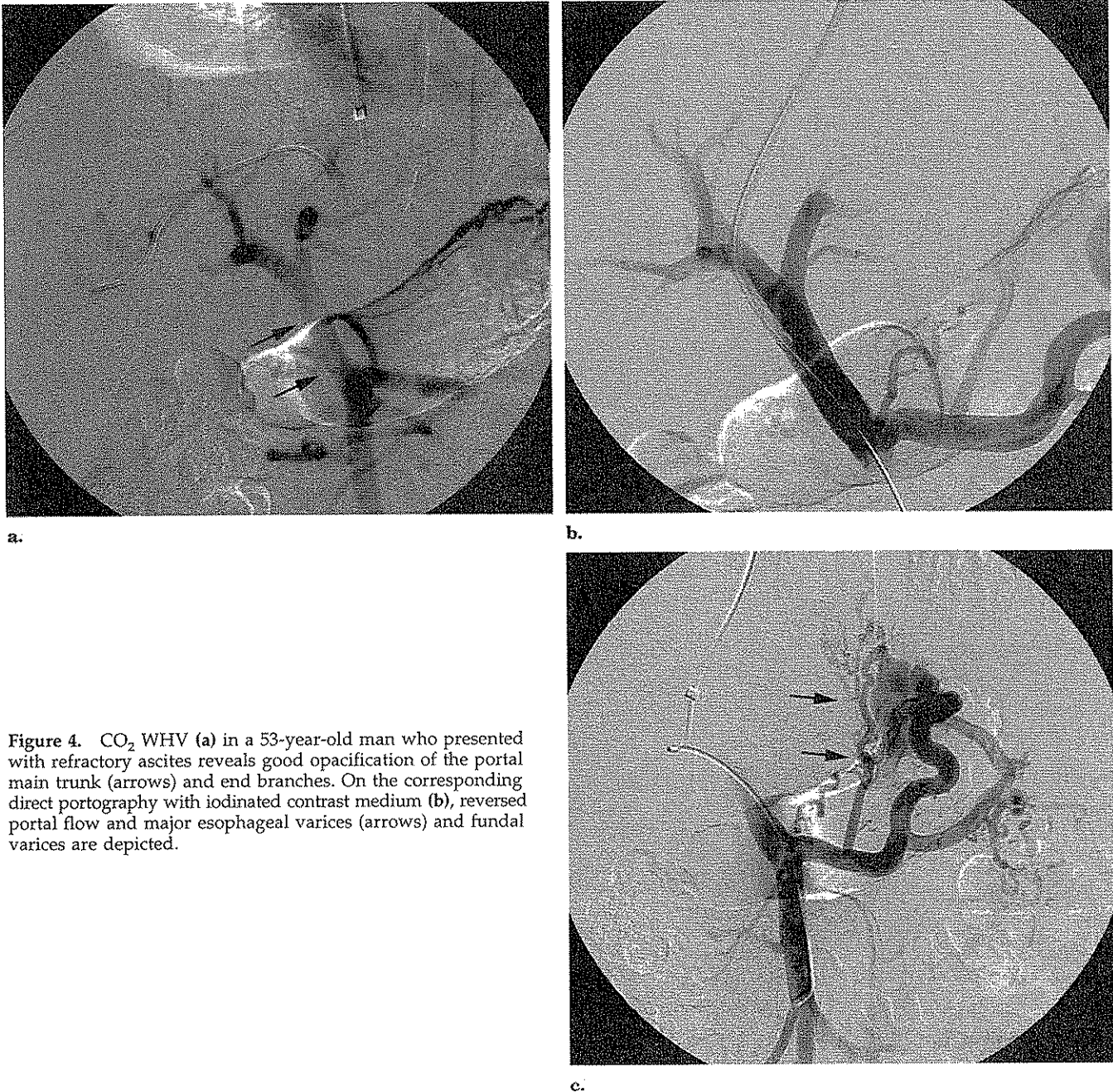


Figure 4. CO₂ WHV (a) in a 53-year-old man who presented with refractory ascites reveals good opacification of the portal main trunk (arrows) and end branches. On the corresponding direct portography with iodinated contrast medium (b), reversed portal flow and major esophageal varices (arrows) and fundal varices are depicted.

years of experience, respectively. In case of a discrepancy between the two readers' scoring, a consensus was obtained after discussion.

In the second part of the study, several parameters that potentially influence the performance of CO₂ WHV were assessed to determine which parameters favored full and clear opaci-

fication of the MPV and its branches and end branches. The parameters analyzed were age, sex, underlying liver disease, portosystemic pressure gradient, Child-Pugh class, patency of the umbilical vein, spontaneous splenoportal shunt, reversed portal flow, esophageal varices, and medical indication for TIPS creation.

Statistical Analysis

Sensitivity (including exact 95% CIs) was calculated for the different levels of opacification of the portal vein (ie, scores of 1–5) with CO₂ WHV, with direct portography with iodinated contrast medium used as the standard. Because the standard out-

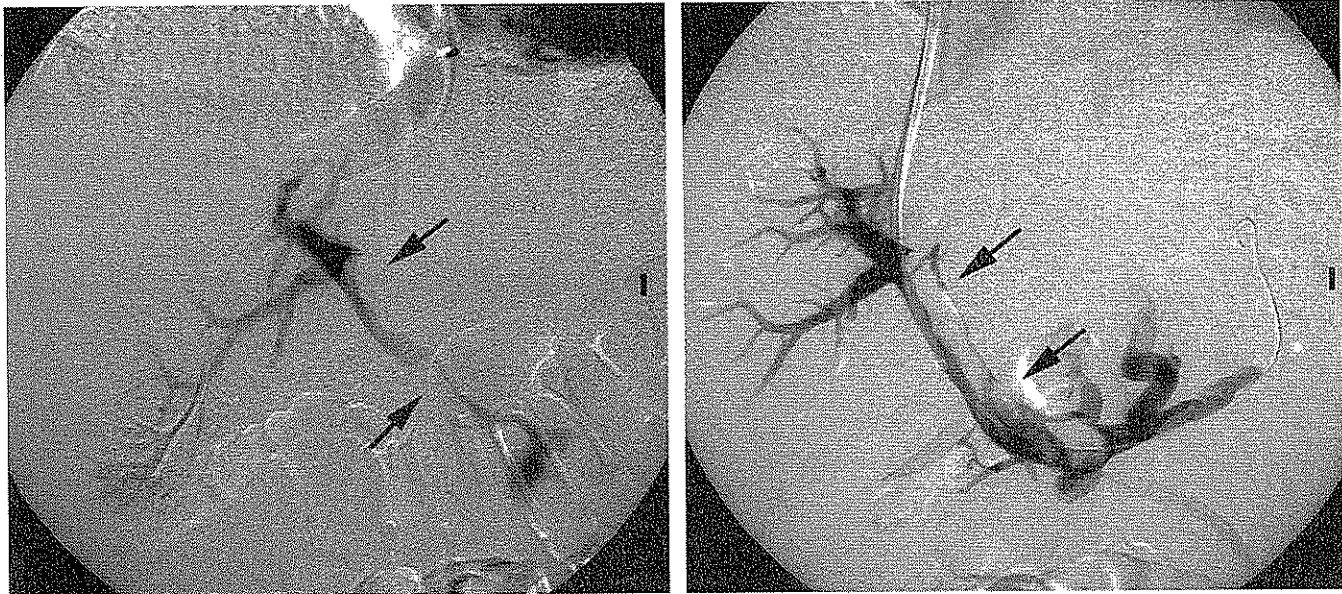


Figure 5. CO₂ WHV (a) in a 74-year-old man with refractory ascites demonstrates patent right and left portal veins and end branches. The MPV trunk is clearly narrowed (arrows) by a sharply delineated mass effect. The corresponding direct catheter portography with iodinated contrast medium (b) confirms these findings (arrows), which are suggestive of partial portal vein thrombosis.

come is nearly always a fully patent portal main trunk and end branches, calculation of specificity does not make sense. Spearman correlations and nonparametric tests (Wilcoxon two-sample test, Kruskal-Wallis test) were used to compare the CO₂ score between the levels of a set of factors. All reported *P* values were two-sided, and the α level was set at 5%. No correlation was made for multiple testing. All analyses were performed with the SAS statistical package (version 9.1; SAS, Cary, NC).

RESULTS

Image Analysis

In all 163 cases (100%), it was possible to place a diagnostic 4-F or 5-F Cobra catheter wedged in the right hepatic vein and subsequently perform CO₂ WHV. In three patients (1.8%), a clear amount of CO₂ bubbles extravasated and dispersed into the peritoneal cavity (Fig 1). No hemodynamic changes were noted by the anesthesiologist in any patient, and no additional medical procedures were necessary. No early or late symptoms were experienced by the patient as a potential result of this CO₂ extravasation.

Creation of a portosystemic shunt

Table 1
Sensitivity Parameters of Different Levels of Opacification of the Portal Venous System by CO₂ WHV

Level of Opacification	No. of Patients	Sensitivity (%)	95% CI
Right portal vein end branches	159	97.55	93.84–99.33
Right portal vein main branch	154	95	91.30–98.25
Right and left main portal branch	152	93.83	88.94–97.00
Entire main portal vein	110	68.52	60.77–75.58
Stenosed main portal vein	13	80.00	28.36–99.49

was also possible in all patients, and subsequent analysis of direct catheter portography with iodinated contrast medium was available in all patients. Direct portography showed fully patent right and left portal veins and end branches in all but one patient. The portal main trunk was stenosed in five patients (3.06%), the portal vein was occluded in one patient (0.6%), and the MPV and end branches were fully patent in the remaining 157 patients (96.31%).

Sensitivity Analysis

Analysis of the level of opacification of the portal venous system revealed no opacification of any distal portal end branch (ie, score of 0) in four patients, opacification of right

portal end branches without opacification of the remaining parts of the portal venous system (ie, score of 1) in five patients (Fig 2), opacification of the right portal main branch without opacification of the left portal vein or portal vein main branch (ie, score of 2) in three patients, opacification of right and left portal main branches without opacification of the MPV (ie, score of 3) in 41 patients (Fig 3), and opacification of the entire MPV (ie, score of 4) in 110 patients (Fig 4). In 13 of these 110 patients, the MPV was incompletely opacified, suggesting an underlying stenosis.

In the five patients who presented with an MPV stenosis on direct portography (Fig 5), CO₂ WHV revealed opacification of the MPV and clear delineation of the stenosis in four cases

Table 2
CO₂ Scoring Groups According to Sex

CO ₂ Score	Male	Female
0	2	2
1	3	1
2	3	0
3	34	7
4	66	32
Stenosis of MPV	10	3

Table 3
CO₂ Scoring Groups According to Child-Pugh Class

CO ₂ Score	Class A	Class B	Class C
0	1	2	1
1	1	1	2
2	0	0	3
3	6	20	15
4	5	34	59
Stenosis of MPV	4	2	7

Table 4
CO₂ Scoring Groups According to Underlying Disease Group

CO ₂ Score	Group 1	Group 2a	Group 2b	Group 3
0	0	2	1	1
1	1	1	2	0
2	0	3	0	0
3	3	26	10	2
4	3	76	17	2
Stenosis of MPV	1	9	3	0

and no opacification of the MPV and subsequently no depiction of the portal stenosis in one.

Sensitivity for opacification of the right portal end branches, right portal main branch, and right and left portal main branches, and complete opacification of the MPV with or without underlying stenosis, is summarized in Table 1.

Analysis of Parameters Influencing Level of Opacification

Age.—The mean age of the 163 patients included in the study was 56.66 years (SD, 11.72; median age, 57 years; first quartile, 48 y; third quartile, 66 y). There was no evidence of a relationship between age and CO₂ score. The Spearman correlation was 0.04 ($P = .61$).

Sex.—Among the 163 patients, 118 were men (72.39%) and 45 were women (27.61%). Distribution of sex among the five CO₂ score groups is summarized in Table 2. There is no evidence that CO₂ scores were different between male and female patients (Wilcoxon two-sample test, $P = .26$).

Child-Pugh class.—Patients' Child-Pugh classes before TIPS creation were class A in 17 patients (10.43%),

class B in 59 patients (36.20%), and class C in 87 patients (53.37%). Distribution of Child-Pugh scores among the CO₂ score groups is summarized in Table 3. There was no evidence of a relationship between CO₂ score and Child-Pugh score. The Spearman correlation was 0.13 ($P = .09$).

Underlying liver disease.—The aforementioned underlying liver diseases were clustered in four groups, as summarized in Table 4: group 1 included presinusoidal portal hypertension (ie, portal vein thrombosis, primary biliary sclerosis, sclerosing cholangitis, and hilar cholangiocarcinoma in a transplant recipient); group 2a included sinusoidal portal hypertension based on alcoholic cirrhosis; group 2b included sinusoidal cirrhosis based on other diseases (nonalcoholic alcohol steatosis, hepatitis C, granulomatous hepatitis, hemochromatosis, hepatitis B, polycystic liver disease, toxic hepatitis); and group 3 included postsinusoidal portal hypertension (ie, venoocclusive disease). There was no evidence of a significant difference in CO₂ score among the four groups (Kruskal-Wallis test, $P = .23$). There was also no evidence of a significant difference between groups 2a and 2b (Wilcoxon two-sample test, $P = .28$).

Portosystemic gradient.—The patient with portal vein occlusion was excluded from analysis of potential correlation with portosystemic gradient because pressure measurements cannot be made in an occluded portal vein. The mean portosystemic gradient in the 162 remaining patients was 22.27 mm Hg (SD, 12.61; median, 18.00 mm Hg; first quartile, 13 mm Hg; third quartile, 27 mm Hg). There was a significant relationship between portosystemic gradient and CO₂ score: the higher the portosystemic gradient, the higher the CO₂ score. The Spearman correlation was 0.33 ($P < .0001$).

Patent umbilical vein.—A patent umbilical vein was revealed on CO₂ WHV and direct portography with iodinated contrast medium in 30 patients (18.40%) (Fig 6). Distribution of umbilical vein patency among CO₂ scoring groups is summarized in Table 5. There was a significant difference in CO₂ score between groups: the group without opacification had a higher score (Wilcoxon two-sample test, $P = .0096$).

Spontaneous splenorenal shunt.—A spontaneous splenorenal shunt was demonstrated on direct portography in 24 patients (14.72%). Distribution of the presence of a spontaneous splenorenal shunt among the CO₂ scoring groups is summarized in Table 6. There was a significant difference in CO₂ score between groups: patients with a spontaneous splenorenal shunt had a higher score (Wilcoxon two-sample test, $P = .019$).

Reversed portal flow.—Reversed portal flow was depicted on direct portography in 42 patients (25.77%), and hepatopetal flow was seen in 122 patients (74.23%). Distribution of the presence of hepatofugal and hepatopetal flow among CO₂ scoring groups is summarized in Table 7. There was a significant difference in CO₂ scores between groups: patients with hepatofugal flow had a higher score (Wilcoxon two-sample test, $P < .0001$).

Esophageal varices.—In 104 patients (63.8%), esophageal varices were depicted on direct portography. No varices could be detected in 59 patients (36.2%). Distribution of the presence or absence of esophageal varices among CO₂ scoring groups is shown in Table 8. There was a sig-

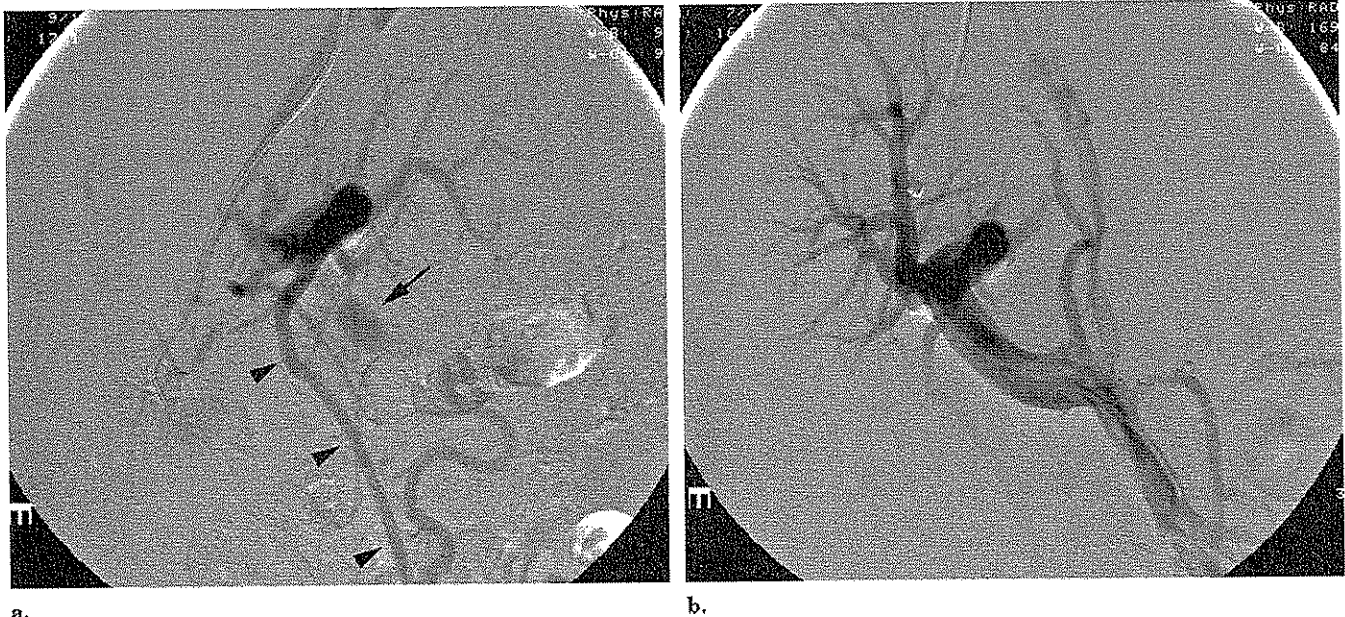


Figure 6. CO₂ WHV (a) in a 70-year-old woman who presented with refractory ascites as a result of alcohol-induced liver cirrhosis shows opacification of the right and left portal vein; the portal main trunk (arrow) is partly opacified. Note the clear opacification of a paraumbilical venous collateral vessel (arrowhead). The corresponding direct catheter portography with iodinated contrast medium (b) shows a fully patent portal venous system.

Table 5
CO₂ Scoring Groups According to Patency of Umbilical Vein

CO ₂ Score	Patent Umbilical Vein	No Opacification of Umbilical Vein
0	0	4
1	0	4
2	2	1
3	15	26
4	11	87
Stenosis of MPV	2	11

Table 6
CO₂ Scoring Groups According to Presence of a Spontaneous Splenorenal Shunt

CO ₂ Score	Spontaneous Splenorenal Shunt	No Spontaneous Splenorenal Shunt
0	0	4
1	0	4
2	0	3
3	2	39
4	20	78
Stenosis of MPV	2	11

Table 7
CO₂ Scoring Groups According to Hepatofugal and Hepatopetal Flow

CO ₂ Score	Hepatofugal Flow	Hepatopetal Flow
0	0	4
1	0	4
2	0	3
3	3	38
4	33	65
Stenosis of MPV	6	7

nificant difference in CO₂ score between groups; the group with opacified varices had a higher score (Wilcoxon two-sample test, $P = .017$).

Indication for TIPS.—The indications for TIPS were clustered in three groups: group 1, variceal bleeding; group 2, refractory ascites, hepatic hydrothorax, and a combination of the two; and group 3, preparation for gastrointestinal surgery. The CO₂ scores among these groups is shown in Table 9. There was no evidence of a significant difference in CO₂ score between groups (Kruskal-Wallis test, $P = .31$).

DISCUSSION

Assessment of the patency of the portal vein and its end branches in patients with cirrhosis and portal hypertension-related complications is of major clinical importance and will influence further medical therapy (12) or will hamper or even contraindicate future TIPS creation (11) or liver transplantation. Portal vein patency is almost always accurately established before a TIPS procedure or liver transplantation by noninvasive imaging like duplex US, CT, or MR imaging,

with sensitivity levels close to 100% (2).

A few retrospective studies (6–8) and prospective studies (9) have demonstrated the superiority of WHV with CO₂ as a contrast medium over WHV with iodinated contrast material to depict segments or the entire portal venous system. However, none of these studies compared CO₂ WHV with the gold standard of direct catheter portography with iodinated contrast medium. Our study, which compared CO₂ WHV versus direct catheter portography with iodinated contrast me-

Table 8
CO₂ Scoring Groups According to Presence or Absence of Esophageal Varices

CO ₂ Score	Esophageal Varices	No Varices
0	3	1
1	2	2
2	2	1
3	18	23
4	70	28
Stenosis of MPV	9	4

dium, clearly shows that indirect opacification of the right and left main portal branches by CO₂ WHV has a very high sensitivity and can be considered a reliable and efficient radiologic mapping method before the creation of a TIPS, taking into account that the right portal vein is classically the targeted vessel during intrahepatic puncture for TIPS creation (13). Indirect opacification by CO₂ WHV of the entire portal main trunk is clearly less efficient, with a sensitivity of 68.22%, and leads to an overestimation of portal vein thrombosis. However, Vlachogiannakos et al (10) suggested the use of CO₂ WHV together with pressure measurements and transjugular liver biopsy as a routine outpatient workup in patients with cirrhosis before TIPS creation or liver transplantation and termed it "the one-stop liver shop." The results of our study cannot establish that CO₂ WHV is highly reliable in the identification of the portal main trunk and the portal vein end branches, and subsequently that it should be considered the gold standard for evaluation of patency of the portal venous system. Although CO₂ WHV—performed during the same session and with the same access as transjugular liver biopsy and pressure measurements—can still be performed as an adjunctive imaging method in the radiologic workup of a patient with cirrhosis, assessment of the patency of the portal venous system should always be performed with duplex US, CT, or MR imaging. Additionally, injection of CO₂ into the liver parenchyma with use of a diagnostic end-hole catheter is very safe, with a complication rate of 1.8%. None of these complications were lethal or even required any intervention, and

Table 9
CO₂ Scoring Groups According to Indication for TIPS Creation

CO ₂ Score	Indication Group 1	Indication Group 2	Indication Group 3
0	0	3	1
1	2	1	1
2	0	3	0
3	16	24	1
4	44	52	2
Stenosis of MPV	6	6	1

Note.— See text for explanation of indication groups.

no early or late sequelae were noted, although some case reports have described liver laceration and patient death (14,15).

Evaluation of the degree of stenosis by CO₂ WHV in case of MPV stenosis seems to be less reliable than direct portography, although the sample of patients with a portal vein stenosis in this series ($n = 13$) was too small to allow us to make definite conclusions.

Depending on the underlying pathophysiologic vascular changes induced by liver cirrhosis in these patients, CO₂ WHV will provide more extensive information on portal anatomy and patency. First, the higher the portosystemic gradient, the better the CO₂ opacification of the entire portal venous system. Increase of portal pressure results in a greater portal vein diameter and decreased portal flow velocity as demonstrated and measured by duplex US (16). When CO₂ is injected in the liver parenchyma, it traverses the hepatic sinusoids and drains into the portal circulation. Decrease of portal flow apparently facilitates portal vein opacification rather than decrease in portal pressure.

In cases of reversed portal flow, the injected CO₂ will be easily drained into the portal circulation in the same manner as the portal blood is drained. Esophageal varices or spontaneous splenorenal shunts are potential partial or complete draining pathways of the portal blood and subsequently can also draw injected CO₂ into these vascular structures, thereby providing better CO₂ opacification of the main portal trunk.

A patent umbilical vein can also drain CO₂, as described earlier, and can thereby lessen opacification of the portal main trunk. The anatomic location ventral to the portal system po-

tentially plays a role in providing worse opacification of the main portal trunk. The buoyancy of gas has the characteristics of preferentially filling the nondependent portal structures (17). The histology of the underlying liver disease, particularly the difference between presinusoidal, sinusoidal, and postsinusoidal portal hypertension-induced liver cirrhosis, will not significantly influence the CO₂ score. As a part of this analysis, we did not find any difference in CO₂ score between viral and other types of hepatitis-induced liver cirrhosis and alcohol-induced liver cirrhosis, as was previously suggested by Ishikawa et al (18). These authors also described a correlation between Child-Pugh score and CO₂ score: the higher the Child-Pugh score, the better the CO₂ score. These findings could not be confirmed by our study.

There are some limitations of this study. The study population consisted of patients with cirrhosis who presented with severe portal hypertension-related complications and were to undergo a TIPS procedure (and had a patent portal vein on US), rather than a general population of patients with cirrhosis. As an additional bias in the study population, patients with portal vein thrombosis were not included, making sensitivity and specificity analysis possible only for patients with a patent portal venous system. In that way, calculation of only sensitivity made sense.

In summary, CO₂ WHV is safe, highly efficient, and reliable for right and left portal vein opacification, but it is clearly less efficient for opacification of the main portal trunk. Therefore, we can recommend CO₂ WHV as a reliable imaging tool only for opacification of the right and left portal vein

branches during TIPS creation. We cannot recommend the use of CO₂ WHV as a reliable part of a diagnostic routine workup alongside transjugular liver biopsy and hepatic wedge pressure measurements in a single outpatient procedure through the same jugular vascular access to evaluate the patency of the entire portal venous system, the histology of the underlying liver disease, and the portal pressure measurements in patients with cirrhosis, as has been previously suggested (9,10). Cross-sectional imaging like duplex US, CT, and MR imaging have a much higher sensitivity and specificity (2,4) and are still indicated when patency of the portal venous system has to be assessed. However, successful and complete opacification of the portal venous system by CO₂ WHV is increased in the presence of some vascular pathophysiologic changes typical of cirrhosis, such as reversed portal blood flow, increased portal pressure, large esophageal varices, and spontaneous spleno-renal shunt. A patent umbilical vein can be considered a negative predictive factor for optimal opacification of the portal vein by CO₂ WHV.

References

- Inoue Y, Nakamura H, Akaji H. The optimal dose of nicardipine for enhancement of indirect portography. *Cardiovasc Intervent Radiol* 1998; 21: 17-21.
- Finn JP, Kane RA, Edelman RR, et al. Imaging of the portal venous system in patients with cirrhosis: MR angiography vs duplex Doppler sonography. *AJR Am J Roentgenol* 1993; 161:989-994.
- Nghiem HV, Winter TC, Mountford MC, et al. Evaluation of the portal venous system before liver transplantation: value of phase-contrast MR angiography. *AJR Am J Roentgenol* 1995; 164:871-878.
- Kraus BB, Ros PR, Abbitt PL, et al. Comparison of ultrasound, CT and MR imaging in the evaluation of candidates for TIPS. *J Magn Reson Imaging* 1995; 5:571-578.
- Rees CR, Niblett RL, Lee SP, et al. Use of carbon dioxide as a contrast medium for transjugular intrahepatic portosystemic shunt procedures. *J Vasc Interv Radiol* 1994; 5:383-386.
- Krajina A, Lojik M, Chovanec V, et al. Wedged hepatic venography for targeting the portal vein during TIPS: comparison of carbon dioxide and iodinated contrast agents. *Cardiovasc Intervent Radiol* 2002; 25:171-175.
- Yang L, Bettmann MA. Identification of the portal vein: wedge hepatic venography with CO₂ or iodinated contrast medium. *Acad Radiol* 1999; 6:89-93.
- Martinez-Cuesta A, Elduayen B, Vivas I, et al. CO₂ wedged hepatic venography: technical considerations and comparison with direct portography with iodinated contrast. *Abdom Imaging* 2000; 25:576-582.
- Debernardi-Venon W, Bandi JC, Garcia-Pagan JC, et al. CO₂ wedged hepatic portography in the evaluation of portal hypertension. *Gut* 2000; 46:856-860.
- Vlachogiannakos J, Patch D, Watkinson A, et al. Carbon-dioxide portography: an expanding role? *Lancet* 2000; 355:987-988.
- Bilbao JL, Quiroga J, Herrero JJ, et al. transjugular intrahepatic portosystemic shunt (TIPS): current status and future possibilities. *Cardiovasc Intervent Radiol* 2002; 25:251-269.
- Francoz C, Belghiti J, Vilgrain V, et al. Splanchnic vein thrombosis in candidates for liver transplantation: usefulness of screening and anticoagulation. *Gut* 2005; 54:691-697.
- Schultz SR, LaBerge JM, Gordon RL, et al. Anatomy of the portal vein bifurcation: intra- versus extrahepatic location: implications for transjugular intrahepatic portosystemic shunt. *J Vasc Interv Radiol* 1994; 5:457-459.
- Theuerkauf I, Strunk H, Brensing KA, et al. Infarction and laceration of liver parenchyma caused by wedged CO₂ venography before TIPS insertion. *Cardiovasc Intervent Radiol* 2001; 24:64-67.
- Semba CP, Saperstein L, Nyman U. Hepatic laceration from wedged venography performed before transjugular intrahepatic portosystemic shunt placement. *J Vasc Interv Radiol* 1996; 7:143-146.
- Haag K, Rossle M, Ochs A, et al. Correlation of duplex sonography findings and portal pressure in 375 patients with portal hypertension. *AJR Am J Roentgenol* 1999; 172:631-635.
- Hawkins IF, Caridi JG. Carbon dioxide (CO₂) digital subtraction angiography: 26-year experience at the University of Florida. *Eur Radiol* 1998; 8:391-402.
- Ishikawa A, Nishida H, Baba T, et al. Evaluation of balloon-occluded hepatic venography with carbon dioxide for portography and correlation between retrograde portogram and liver function in patients with liver cirrhosis. *Hepatol Res* 2000; 18:239-251.