

Fei Sun
Javier Hernández
Verónica Crisóstomo
Luis-Fernando Pineda
Juan Rafael Lima
Jesús Usón
Manuel Maynar

Fine-needle percutaneous transhepatic parenchymal portal venography by using carbon dioxide: a pilot study in pigs

Received: 27 July 2001
Revised: 14 January 2002
Accepted: 1 February 2002
Published online: 9 May 2002
© Springer-Verlag 2002

F. Sun (✉) · J. Hernández · V. Crisóstomo
L.-F. Pineda · J.R. Lima · J. Usón
Minimally Invasive Surgery Centre,
Campus Universitario,
Avenida de la Universidad, s/n,
10071 Cáceres, Spain
e-mail: feisun@ccmi.es
Tel.: +34-927-181032
Fax: +34-927-181033

M. Maynar
Department of Radiology,
Faculty of Medicine,
Las Palmas University,
35016 Las Palmas de Gran Canaria, Spain

Abstract Our purpose was to evaluate the feasibility and safety of carbon dioxide (CO₂) in fine-needle percutaneous transhepatic parenchymal portal venography and its potential clinical applications. Three Belgian landrace pigs received fine-needle percutaneous transhepatic parenchymal portal venography by using CO₂ as a contrast agent. Under fluoroscopic and B-mode ultrasonic guidance, right or left lobe of liver was punctured with a 22-G Chiba needle, through which CO₂ was injected with a dedicated CO₂ injector at injection rate of 20 ml/s for 20 ml, 40 ml/s for 40 ml, 40 ml/s for 60 ml, and 40 ml/s for 80 ml, respectively. The portal venograms were obtained by use of digital subtraction angiography (DSA) system with animal in supine position. In one pig transarterial portal venography was per-

formed, in addition, using iodinated contrast agent. The portal vein was visualized in each run of venography. Optimal images of portal tree structure up to four-order branches were obtained in all those with CO₂ injection rate of 40 ml/s, which appeared much better in quality than those obtained by cranial mesenteric arteriography with iodinated contrast agent. No extravasation of CO₂, liver laceration, or any other complication occurred during the procedures. The technique we proposed demonstrated optimal portography, which appeared to be safe, minimally invasive, less time-consuming, cost-effective, and easy to perform, with great potential in clinical applications.

Keywords Carbon dioxide · Contrast media · Portography · Diagnostic imaging

Introduction

Portal venography has a wide spectrum of indications in clinical applications, including, for example, portal hypertension, hepatic encephalopathy, ascending portal thrombophlebitis, hepatocellular carcinoma and pancreaticobiliary tumors, hepatic metastatic tumors, and gastrointestinal hemorrhage [1]. Evaluation of portal system not only provides essential information for diagnosis, e.g., differentiation of splanchnic arterial disease from portal venous disease, follow-up of surgically created portosystemic shunts, and transjugular intrahepatic portosystemic shunts (TIPS), but also is helpful in planning of therapy, tumor staging, and predicting prognosis of

liver-related diseases. In addition, there have been increasing concerns about evaluation of patency of portal vein in potential candidates for liver transplantation [2, 3, 4]. Currently, various modalities are widely used to evaluate portal system, including, for example, transarterial portography by catheterization in superior mesenteric artery or splenic artery using digital subtraction angiographic system (DSA), computed tomography during arterial portography (CTAP), conventional percutaneous transhepatic portography, color Doppler ultrasonography, MR portography with or without using gadolinium as a contrast agent, each of which has particular drawbacks as well as benefits in clinical applications [5, 6, 7, 8].

Carbon dioxide (CO₂) hepatic wedged portography has been paid increasing interest in demonstrating portal structures. The quality of CO₂ hepatic wedged portographs looks superior to those of DSA transarterial portographs. The most significant benefits lie in fact that CO₂ is nonallergic and lacks nephrotoxicity, and is of extremely low cost (\$0.005 per milliliter in the U.S.) when compared with various contrast agents described above, e.g., approximately one thousandth the cost of iodinated contrast agent (ICA) [4]; however, the technique needs transjugular access and catheterization to hepatic vein, which is somewhat demanding and invasive. More recently, Hawkins reported the use of fine-needle transjugular by direct injection of CO₂ into liver parenchyma in TIPS procedure to show the portal venous anatomy as guidance, and confirmed the clinical potential of intraparenchymal CO₂ portography [10, 11]. We proposed fine-needle percutaneous transhepatic parenchymal portal venography by using CO₂, for the purpose of clinical diagnosis rather than that of TIPS or other interventional procedures. The purpose of this pilot study was to evaluate feasibility and safety of the technique and its potential in clinical applications.

Materials and methods

Three Belgian landrace pigs, aged 12–18 weeks, with body weight 28.5–36.2 kg were used in this study. All the procedures were performed in an authorized experimental laboratory of animal investigation (Centro de Cirugía de Mínima Invasión, Cáceres, Spain). The protocols were approved by the local Institutional Ethics Committee. After being fasted for 24 h, each pig was premedicated with diazepam 0.1 mg/kg, ketamine 10 mg/kg, and atropine 0.01 mg/kg intramuscularly. Intravenous hydration with normal saline was established by catheterization of the auricular vein with 18- to 22-G needles (Abbott Ireland, Sligo, Ireland) and maintained during angiography. Induction of anesthesia was performed with propofol 2 mg/kg intravenously. After the pig was endotracheally intubated, it was connected to anesthesia system (Ohmeda Excel 210 SE, Boc Group, Madison, Wis.) and mechanical ventilator (Ohmeda 7800, Boc Group, Madison, Wis.). Anesthesia was maintained with halothane 2–2.5%; blood pressure, ECG, O₂ saturation, end-tidal CO₂, and body temperature were monitored closely throughout the procedure. The pigs were fixed at operating table in supine position with cranial and caudal extension of the limbs. The pigs were given Synulox (Pfizer, New York, N.Y.) 0.15 ml/kg intramuscularly. The abdomens were shaved and draped in a sterile fashion.

Under fluoroscopic (Philips Mobile Digital Angiographic System-BV300, Philips, Eindhoven, The Netherlands) and ultrasonic (The Panther Ultrasound Scanner Type 2002, B&K Medical, Denmark) guidance, a puncture site was localized at right hypochondriac region and a 22-G biopsy Chiba needle (Cook, Denmark) was used to puncture percutaneously, and the tip of needle was placed in parenchyma of right medial lobe or left medial lobe of liver (Fig. 1). After confirming the tip of Chiba needle in proper position by fluoroscopy and ultrasonography, the core of needle was removed. Aspiration was made to ensure that the tip of Chiba needle was in the parenchyma if no blood, bile, air, or contents of stomach or bowel were aspirated out. Then the Chiba needle was connected directly to a dedicated CO₂ angiographic injector (CO₂ JECT Injector, Angiodynamics, New York, N.Y.). After the CO₂

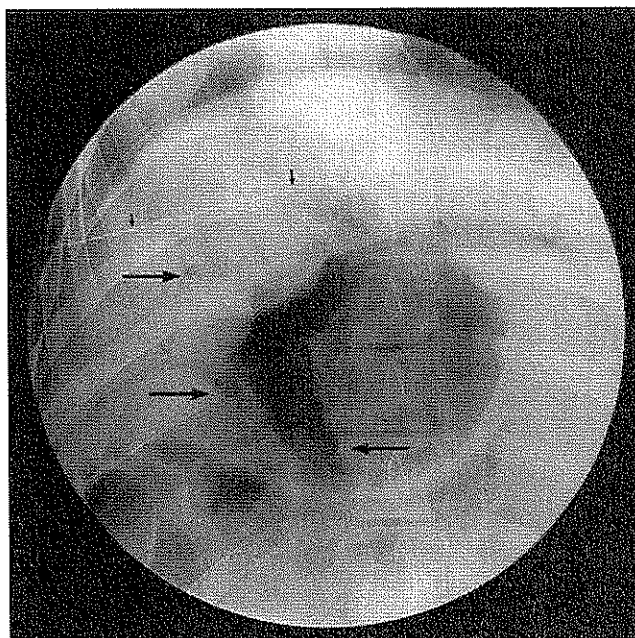


Fig. 1 Plain film of intraparenchymal CO₂ portal venography shows that the tip of fine needle is percutaneously placed at the left medial lobe of liver (*small arrows*). The portal tree is also visualized (*long arrows*)

connecting tube (CO₂NNECT set, Angiodynamics, New York, N.Y.) was purged automatically, the injection parameters of CO₂ were selected as 20 ml/s for 20 ml, 40 ml/s for 40 ml, 40 ml/s for 60 ml, and 40 ml/s for 80 ml, respectively, in each run of portography. After blocking breath of animal by temporarily switching off the power of anesthesia system and mechanical ventilator, the acquisition was obtained at rate of 12 frame/s in posterior–anterior projection with a C-arm angiographic system without the support of stacking program, which was believed to be particularly beneficial to CO₂ angiography. The interval between each injection was at least 5 min. The Chiba needle was removed after portography.

All three animals were evaluated with the same protocol described above for CO₂ portography. Furthermore, in the last pig, transarterial portal venography was performed as control after CO₂ portography. After skin preparation in groin area, percutaneous access in right femoral artery was established by Seldinger technique using 6-F introducer set (Terumo, Tokyo, Japan). A 5-F Cobra II angiographic catheter with two sideholes (Radifocus DB2500GM, Terumo, Tokyo, Japan) was advanced through arterial introducer sheath and catheterized selectively into cranial mesenteric artery. Arteriography was performed in posterior–anterior projection at acquisition rate of 5 frame/s when the ventilation of pig was blocked temporarily. The iodinated contrast agent, 76% urografin (Schering, Berlin, Germany) of 60 ml was injected through angiographic catheter with electronic power injector (Mark V Plus Injection System, Medrad, The Netherlands) at injection rate of 15 ml/s. After procedure, each animal was allowed to recover from anesthesia.

Twelve runs of CO₂ portography and one run of transarterial portal venography using ICA were reviewed postprocedurally. Only the best images in each run of portography were post-processed and printed. In total, thirteen images were evaluated and analyzed. A subjective evaluation of image quality was performed. A score of zero was assigned when no portal vein was opacified; a score of 1 when only part branches of portal tree were demonstrated; a

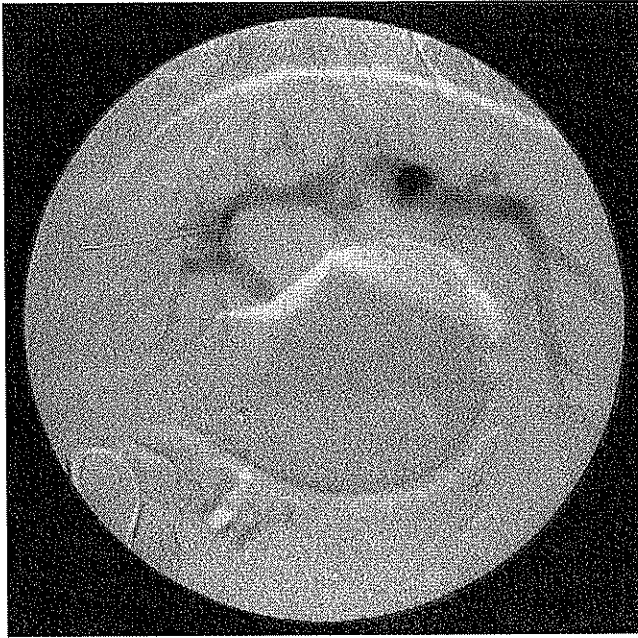

Fig. 2 Partial intrahepatic portal branches are demonstrated in the intraparenchymal CO₂ portal venography at injection rate of 20 ml/s in 20 ml of CO₂

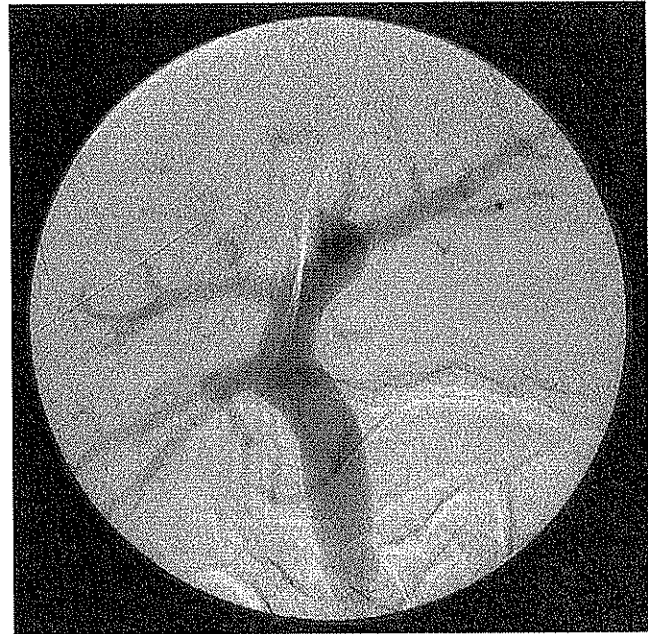

Fig. 3 Intraparenchymal CO₂ portal venography delineates the portal structures at the injection rate of 40 ml/s in 80 ml of CO₂

score of 2 when both extrahepatic portal vein and major branches (first- or second-order branch) of intrahepatic portal vein were visualized; a score of 3 when extrahepatic portal vein and intrahepatic portal vein with up to third-order fine branches was delineated; a score of 4 when part splenic vein as well as extrahepatic portal vein with third-order branch of intrahepatic portal vein was opacified.

Results

Portal tree filling with CO₂ retrogradely was demonstrated in overall series of CO₂ portography. In all the three low-dose and slow-injection (20 ml/s for 20 ml of CO₂) runs, only part branches of intrahepatic portal vein near the tip of fine needle were opacified with CO₂ (Fig. 2). Optimal CO₂ portograms, in which both extrahepatic and intrahepatic portal vein with its fourth-order branches were demonstrated, were obtained in all the other series at injection rate of 40 ml/s for 40 ml, 60 ml, and 80 ml of CO₂, respectively (Fig. 3). Comparing the images with different dose of CO₂, it seemed that 40 ml of CO₂ was sufficient to demonstrate portal anatomy up to its fourth-order branches, and that no significant improvement in image resolution was noted with the dose of CO₂ increasing to 60 ml or 80 ml even if more fine branches were opacified in high-dose runs. Part of splenic vein was also filled with CO₂ in some runs with injection of 60 ml and 80 ml of CO₂ (Fig. 4). Dynamic portography showed that the CO₂ diffused into the portal vein retrogradely imme-

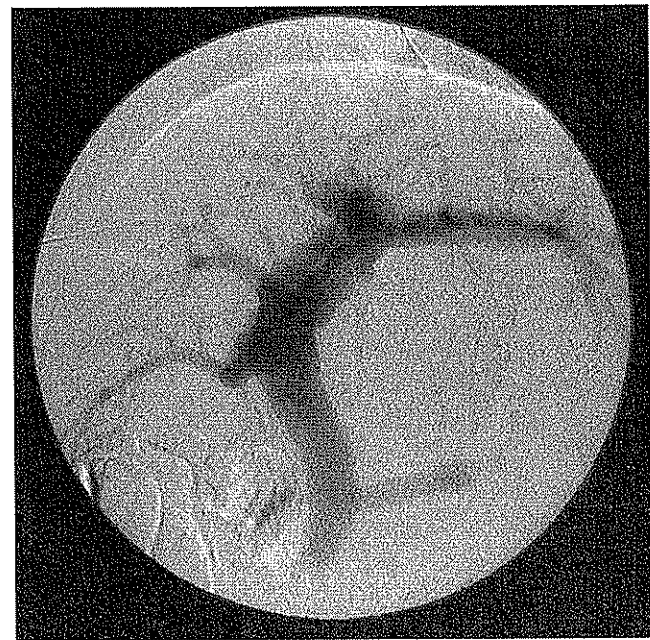


Fig. 4 Intraparenchymal CO₂ portal venography at injection rate of 40 ml/s in 60 ml of CO₂ depicts the portal venous anatomy and part of splenic vein

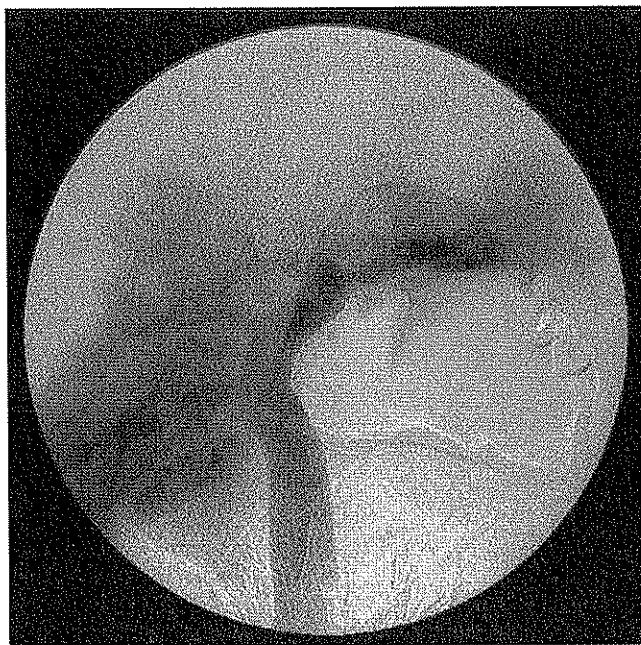


Fig. 5 Portal venogram obtained using cranial mesenteric arteriography with iodinated contrast agent

Table 1 Subjective scoring on image quality of CO₂ and iodinated contrast agent (ICA) portography

Animal	CO ₂ (20 ml/s) 20 ml ^a	CO ₂ (40 ml/s)			ICA (15 ml/s) 60 ml ^a
		40 ml ^a	60 ml ^a	80 ml ^a	
1	1	3	3	3	– ^b
2	1	3	4	4	– ^b
3	1	3	3	4	2

^a Injection volumes of contrast agents

^b Portography was not performed

diately after parenchymal injection and filled the major portal tree within 8 s in all the runs of CO₂ portography at injection rate of 40 ml/s. No peritoneal extravasation of CO₂ or other complications occurred and ECG remained normal during all the procedures of CO₂ portography.

Portal venograms were also obtained by cranial mesenteric arteriography with ICA in one pig (Fig. 5). The third-order branches of intrahepatic portal vein were not filled well with acquisition time for 23 s. Subjective scoring on visualization of portal anatomy suggested that the CO₂ portograms with CO₂ injection rate of 40 ml/s were much superior over transarterial portograms using ICA (Table 1).

Discussion

Carbon dioxide was first used in humans for insufflating the peritoneum in 1914, to delineate abdominal viscera

radiographically [12]. In the 1950s and 1960s, CO₂ was initially used intravenously for detecting pericardial effusions and capnohepatography [13]. Subsequently, in 1971, Hawkins pioneered the intra-arterial use of CO₂ for purpose of diagnosis both in the kidney and in the extremities [14]. In the 1980s, with the advent of digital subtraction angiography (DSA), CO₂ angiography was greatly improved in imaging quality. Since then, CO₂ DSA as a timely and promising technique was widely studied in animals and used in clinical practice, which demonstrated that CO₂ was a safe and reliable contrast agent without allergic potential and nephrotoxicity [11, 14, 15, 16]. Carbon dioxide has currently been used as a contrast agent of choice in patients with underlying renal insufficiency or known hypersensitivity reactions to ICA.

Fine-needle transhepatic parenchymal CO₂ portal venography is a variation from the Hawkins' intraparenchymal portal venography from a venous approach in TIPS. We modified the technique by percutaneous access, which looked easier to perform and less time-consuming for the procedure. According to literature [10], early in the 1980s Hawkins initially placed a fine needle percutaneously transhepatically into liver parenchyma and injected small dosage of CO₂ (20 ml) to demonstrate portal anatomy to facilitate various percutaneous procedures, such as transhepatic cholangiography, portal sampling, and portal vein embolization. In contrast, the technique we proposed here was fast injection of large volume of CO₂ for the purpose of clinical diagnosis of liver-related diseases.

Thanks to the extremely low viscosity, one of the unique physical properties of CO₂, portal venograms might be obtained by injecting a large dose of CO₂ in a short period of time through a fine needle. The CO₂ gas is 400 times less viscous than iodinated contrast [17]. Various techniques have been reported regarding injections of CO₂ through microcatheter, fine needle, and even between the guide wire and the needle or catheter in different interventional procedures to visualize portal venous anatomy [17, 18, 19]. In our study 22-G biopsy Chiba needle was used to puncture the liver percutaneously. Generally, it is believed to be a minimally invasive technique because of the very tiny caliber of the fine needle itself. Furthermore, compared with CO₂ wedged hepatic venography, fine-needle percutaneous transhepatic parenchyma portal venography seems to be safer with fewer complications. In order to obtain optimal portal venograms in the procedure of CO₂ wedged hepatic venous portography, a single end-hole angiographic catheter is generally placed in the peripheral part and close to the liver capsule. If enforced CO₂ injection in an explosive manner is done, extravasation might result [12]. Semba et al. [20] and Taylor et al. [21] reported hepatic laceration and peritoneal extravasation related to the procedure of CO₂ wedged hepatic venography, even

with the result of fatality. On the contrary, the tip of fine needle is placed at central part of the liver when CO₂ is injected during the procedure of CO₂ parenchymal portal venography. The likelihood of extravasation or liver laceration could be greatly reduced presumably. In Hawkins' report of CO₂ portal venography by fine-needle parenchymal injection in more than 120 patients during the procedure of TIPS, no evidence of capsular extravasation was found [11]. In Hawkins' 10 years of practice in other procedures percutaneously transhepatically placing a fine needle in hepatic parenchyma and injecting CO₂ to delineate portal anatomy, no extravasations or bleeding complications occurred [10]. However, Hawkins experienced three cases of extravasation of contrast agent into the peritoneal cavity in the procedure of wedged hepatic venous portography [22]. In our pilot study all the attempts of CO₂ portal venography in three pigs were performed without complication of extravasation or liver laceration. Although the effect of intraparenchymal injection of CO₂ on the liver biochemistry or pathology had not been evaluated in this pilot study, and needs assessing in our future series of pre-clinical studies, it seems reasonable to expect the low hepatotoxicity of CO₂ as a contrast agent and the safety of the technique of fine-needle percutaneous liver parenchymal CO₂ portal venography according the various literature. Mladinich et al. [23] reported the evaluation of CO₂ arterial infusion in a rabbit model and demonstrated no CO₂-related histopathologic damages and no long-term effect on hepatic biochemistry. Culp et al. [24] compared hepatic damage from parenchymal injection of CO₂ and ICA in animals, and revealed that CO₂ produced less severe hepatic damage and was preferred to meglumine diatrizoate for hepatic parenchymal injection.

Also, due to the extremely low viscosity of CO₂, optimal portal venograms might be obtained by parenchymal injection of CO₂. Presently, the mechanism of intraparenchymal CO₂ portal venography remains unclear. We postulated three major factors which have an impact on portal vein imaging. Firstly, extremely low viscosity of CO₂ might contribute greatly to success in imaging the portal venous anatomy. The very low viscosity of CO₂ gas makes it possible to easily and rapidly pass the fine passage (fine needle), to diffuse in the sinusoidal bed through intersinusoidal sphincters of liver, and to fill the portal tree retrogradely through inlet sphincters. Secondly, the unique microvascular architecture of liver would be essential for CO₂ intraparenchymal portal venography. The direct communication between portal vein and sinusoidal bed provides anatomical access for portal venography [21, 25, 26]. Thirdly, hepatic hemodynamics might play an important role in interacting hepatic circulation and be critical to the visualization of portal vein in CO₂ intraparenchymal portal venography. The relative low portal pressure gradient, ranging from 2 to 4 mm Hg [25], could probably partially explain why intraparen-

chymal CO₂ fills the portal tree exclusively, rather than the hepatic arterial system. Although some mechanisms are yet to be tested and answered, the high successful rate of portal visualization in the intraparenchymal CO₂ portal venography appear promising. Hawkins reported that the portal vein was visualized in 100% of the patients in CO₂ intraparenchymal portal venography in TIPS procedures; in contrast, portal vein visualization occurred in only 82–86% of the patients in CO₂ wedged hepatic venography [9, 11]. Debernardi-Venon et al. reported on five cirrhotic patients without visualization of portal vein in CO₂ wedged hepatic venography which was believed to be due to hepatic venous-venous communications that precluded adequately wedged venography since the injected CO₂ escaped through another hepatic vein [9]; however, fine-needle percutaneous transhepatic parenchymal CO₂ portal venography can overcome the limitation from hepatic venous-venous communications because of direct injection of CO₂ into the parenchyma, and elevate the visualization rate of portal venography. This technique we propose appears to be more reliable compared with CO₂ wedged hepatic venography. In our study, complete portal venous anatomy was visualized in all the runs of CO₂ intraparenchymal portal venography, except for those with injection rate of CO₂ at 20 ml/s in volume of 20 ml, in which only partial branches were delineated. It seems that the major reason for partial visualization of portal vein would be the lower injection rate of 20 ml/s, rather than the limited volume of 20 ml.

It is the extremely low viscosity of CO₂ also that facilitates visualization of the collateral vessels, permits arteriovenous shunting in malignant tumors being demonstrated only with CO₂, and improves the detection of minute amounts of arterial bleeding [17, 19, 22]. Digital subtraction angiography using CO₂ as a contrast agent has been suggested by some authors as the best technique for detection of vascular shuntings in patients with hepatocellular carcinoma [27]. Portal venography by intra-arterial injection of CO₂ was also reported to evaluate hepatic metastatic tumors [18]. There seems to be an attractive potential in clinical application of the technique of CO₂ intraparenchymal portal venography in clinical diagnosis and pathological study of hepatic tumors, especially of liver metastases. Although the animals received general anesthesia in this study, local anesthesia or combining with sedation when necessary might be sufficient to maintain the procedure of fine-needle percutaneous transhepatic parenchymal CO₂ portography if it were used in humans in clinical practice, so that the procedure might be performed on an out-patient basis. Another advantage of this technique in future clinical application might be the shorter acquisition time. In our study, major portal tree was opacified in less than 8 s in all the runs of CO₂ portography with the injection rate of 40 ml/s, in 23 s in transarterial portal venography with

ICA. Shorter acquisition time is especially useful for the patients with difficulty in holding breath for a long time.

However, there existed several limitations concerning evaluation of the technique of CO₂ portal venography in this pilot study. There were only three animals used in the study. In addition, the statistical comparisons of the results in different groups were not available due to the very small sample size of animals. Optimizing the parameters of CO₂ injection (injection rate and volume of CO₂) needs to be tested in more animals. Because of buoyancy, another unique and important physical property, the upper or nondependent branches in the area of interest will be readily filled with CO₂ in the portal venography; therefore, the position of the animal during portal venography affects visualization of portal branches. As the main purpose of the study was to evaluate the feasibility and safety of the technique, all the animals were fixed at angiographic table in supine position in the procedures of por-

tal venography. The CO₂ portal venography has to be further investigated with the animal in abdominal prone, left lateral decubitus, or oblique positions.

Conclusion

In conclusion, fine-needle transhepatic parenchymal CO₂ portal venography seems to be a reliable technique with great potential in clinical applications. The major advantages of the technique include optimal image quality, less invasivity, it is easy to perform, less time-consuming, less costly, and there are fewer complications. Since CO₂ is used as a contrast agent in this procedure, the technique is especially helpful in work-up of patients with history of allergy to iodinated contrast agents and in cases of renal insufficiency, although the safety of the technique needs further evaluation.

References

- Okumura A, Watanabe Y, Dohke M, Ishimori T, Amoh Y, Oda K, Dodo Y (1999) Contrast-enhanced three-dimensional MR portography. *Radiographics* 19:973-987
- Taylor CR (1992) Computed tomography in the evaluation of the portal venous system. *J Clin Gastroenterol* 14:167-172
- Shaked A, Busuttill RW (1991) Liver transplantation in patients with portal vein thrombosis and central portocaval shunts. *Ann Surg* 214:696-702
- Vlachogiannakos J, Patch D, Watkinson A, Tibballs J, Burroughs AK (2000) Carbon-dioxide portography: an expanding role? *Lancet* 355:987-988
- Rummeny EJ, Marchal G (1997) Liver imaging: clinical applications and future perspectives. *Acta Radiol* 38:626-630
- Inaba Y, Arai Y, Kanematsu M, Takeuchi Y, Matsueda K, Yasui K, Hoshi H, Itai Y (2000) Revealing hepatic metastases from colorectal cancer: value of combined helical CT during arterial portography and CT hepatic arteriography with a unified CT and angiography system. *Am J Roentgenol* 174:955-961
- Mahfouz AE, Hamm B, Mathieu D (1996) Imaging of metastases to the liver. *Eur Radiol* 6:607-614
- Earls JP (2000) Comparison studies of CT and MRI in patients with hepatic metastases. *Oncology* 14 (Suppl 3): 21-28
- Debernardi-Venon W, Bandi JC, García-Pagán JC, Moitinho E, Andreu V, Real M, Escorsell A, Montanyá X, Bosch J (2000) CO₂ wedged hepatic venography in the evaluation of portal hypertension. *Gut* 46:856-860
- Hawkins IF Jr, Johnson AW, Caridi JG, Weingarten KE (1997) CO₂ fine-needle TIPS. *J Vasc Interv Radiol* 8:235-239
- Hawkins IF Jr, Caridi JG (1999) Fine-needle transjugular intrahepatic portosystemic shunt procedure with CO₂. *Am J Roentgenol* 173:625-629
- Caridi JG, Hawkins IF Jr (1997) CO₂ digital subtraction angiography: potential complications and their prevention. *J Vasc Interv Radiol* 8:383-391
- Dockray KT, Burns RR, Moore J (1965) Capnohepatography: intravenous retrograde gas angiography of liver vein with carbon dioxide. *Radiology* 85:740-742
- Hawkins IF Jr, Wilcox CS, Kerns SR, Sabatelli FW (1994) CO₂ digital angiography: a safer contrast agent for renal vascular imaging? *Am J Kidney Dis* 24:685-694
- Hawkins IF Jr, Caridi JG (1995) CO₂ digital subtraction arteriography: advantages and current solutions for delivery and imaging [comment]. *Cardiovasc Intervent Radiol* 18:150-152
- Hawkins IF Jr, Caridi JG, Klioze SD, Mladinich CR (2001) Modified plastic bag system with O-Ring fitting connection for carbon dioxide angiography. *Am J Radiol* 176:229-232
- Back MR, Caridi JG, Hawkins IF Jr, Seeger JM (1998) Angiography with carbon dioxide. *Surg Clin North Am* 78:575-591
- Miyazono N, Inoue H, Kanetsuki I, Nakajo M (1994) Retrograde visualization of the portal venous system using CO₂ intraarterial digital subtraction angiography. *Abdom Imaging* 19:330-332
- Hawkins IF Jr, Maynar M (1997) Carbon dioxide digital subtraction angiography. In: Castañeda-Zúñiga WR, Tadavarthy SM, Qian Z et al. (eds) *Interventional radiology*, 3rd edn. Williams and Wilkins, Baltimore, pp 429-443
- Semba CP, Saperstein L, Nyman U, Dake MD (1996) Hepatic laceration from wedged venography performed before transjugular intrahepatic portosystemic shunt placement. *J Vasc Interv Radiol* 7:143-146
- Taylor FC, Smith DC, Watkins GE, Kohne RE, Suh RD (1999) Balloon occlusion versus wedged hepatic venography using carbon dioxide for portal vein opacification during TIPS. *Cardiovasc Intervent Radiol* 22:150-151
- Hawkins IF Jr, Caridi JG (1998) Carbon dioxide digital subtraction angiography: 26-year experience at the University of Florida. *Eur Radiol* 8:391-402
- Mladinich CR, Hawkins IF Jr, Heaton-Jones TG, Shiroma JT, Weingarten K, Kiehl A, Mays MB, Kublis P (1995) Effects of carbon dioxide arterial infusion on hepatic biochemistry and histology in a rabbit model. *Invest Radiol* 30:192-195

-
24. Culp WC, Mladinich CR, Hawkins IF Jr (1999) Comparison of hepatic damage from direct injections of iodinated contrast agents and carbon dioxide. *J Vasc Interv Radiol* 10:1265-1270
 25. Ekataksin W, Kaneda K (1999) Liver microvascular architecture: an insight into the pathophysiology of portal hypertension. *Semin Liver Dis* 19:359-382
 26. McCuskey RS (2000) Morphological mechanisms for regulating blood flow through hepatic sinusoids. *Liver* 20:3-7
 27. Yang X, Manninen H, Soimakallio S (1995) Carbon dioxide in vascular imaging and intervention. *Acta Radiol* 36:330-337