

Upper-Extremity Venography: CO₂ versus Iodinated Contrast Material¹

Sam Heye, MD
Geert Maleux, MD
Guy J. Marchal, MD, PhD

Purpose:

To determine prospectively the diagnostic performance of CO₂ venography, by using conventional venography with iodinated contrast material as the reference standard, for the preoperative evaluation of upper-limb and central veins before creation of fistulas for hemodialysis access.

Materials and Methods:

The study was approved by the institutional review board, and informed consent was obtained from all patients. Twenty-two patients underwent comparative CO₂ and conventional venography of upper-extremity and central veins. Two independent observers evaluated the opacification of the veins and grade of stenosis, if present. Interobserver agreements were estimated with the Cohen κ coefficient. Calculations of sensitivity, specificity, and accuracy were used for intertechnique observations.

Results:

For CO₂ venography, global interobserver agreement was good, with a κ value of 0.90 (range, 0.71–1.00; 95% confidence interval: 0.84, 0.95). A κ value of 0.96 (range, 0.86–1.00; 95% confidence interval: 0.93, 0.99) was calculated for global interobserver agreement for conventional venography. The sensitivity, specificity, and accuracy of CO₂ venography for all vein segments were 97%, 85%, and 95%, respectively.

Conclusion:

CO₂ venography had a sensitivity of 97% and a specificity of 85% in the assessment of upper-limb and central vein patency and stenosis, with conventional venography used as the reference standard.

© RSNA, 2006

¹ From the Department of Radiology, University Hospitals Gasthuisberg, Herestraat 49, B-3000 Leuven, Belgium. Received April 28, 2005; revision requested June 23; revision received September 7; accepted September 21; final version accepted November 23. Address correspondence to S.H. (e-mail: sam.hey@uz.kuleuven.ac.be).

In patients with end-stage renal disease who require hemodialysis, providing vascular access by creating an arteriovenous fistula (AVF) is the preferred approach (1,2). Radiocephalic fistulas are preferred because of a lower complication rate and a greater longevity. However, when the creation of these passages is not possible, other surgical arteriovenous anastomoses such as primary brachiocephalic or transposed brachio basilic fistulas in the elbow can be made, or even a polytetrafluoroethylene graft can be inserted (1,2).

In the preoperative assessment before creation of a fistula for hemodialysis access, conventional venography of the upper limbs and the central venous system has been considered the reference standard. Indications for venography include poorly developed superficial veins in the upper limbs at physical examination and evaluation of potential stenosis of the central veins, especially in patients in whom central catheters were previously placed. Because some patients will not have undergone dialysis before creation of the AVF, venography with noniodinated contrast material may be required for preoperative mapping of the veins.

CO₂ has shown its value as an alternative contrast agent for evaluating infradiaphragmatic arteries in patients in whom the use of iodinated contrast material is contraindicated, usually because of the high risk of renal toxicity or allergic reactions (3,4). It has also been recommended as a useful alternative contrast agent for venography (5,6), where the use of CO₂ resulted in better-quality images of the upper-limb central veins compared with the use of iodinated contrast material (5).

The aim of our study was to determine prospectively the diagnostic per-

formance of CO₂ venography, by using conventional venography with iodinated contrast material as the reference standard, for the preoperative evaluation of upper-limb and central veins before creation of fistulas for hemodialysis access.

Materials and Methods

Patient Population

The study was approved by the institutional review board, and informed consent was obtained from all patients. During a 15-month period (June 2003 through August 2004), 22 patients meeting our inclusion criteria (nine men, 13 women; age range, 25–82 years; mean age, 60.6 years) underwent upper-extremity venography. Sixteen patients underwent venography of both upper extremities, and six patients required unilateral upper-limb venography (four right arms, two left arms).

Patients were included in the study if they were older than 18 years, needed venous mapping before AVF creation, and either had a normal serum creatinine level (<1.4 mg/dL) or were already undergoing hemodialysis, ensuring that venography with iodinated contrast material could be performed safely. For this reason, patients with a previous severe allergic reaction to iodine were excluded.

In all patients but one, the indication for venography was preoperative assessment of the superficial venous structures and the central veins for creation of a hemodialysis access fistula. In one patient, who had hereditary hemochromatosis, venography was performed before the creation of an AVF for future frequent venotomies. All patients except this one—who had a serum creatinine level of 0.95 mg/dL—were already undergoing hemodialysis before venography, with use of a central venous catheter ($n = 17$) or a femoral dialysis catheter ($n = 4$); no residual renal function was demonstrated.

Venography Procedure

All venographic examinations (conventional and CO₂) were performed by one of six angiography nurses (8–33 years

of experience; mean, 16.7 years) following a standardized protocol for upper-limb venography. In all patients, CO₂ venography was started first and conventional venography was started 5 minutes later. When both procedures were done, the images were evaluated for their technical success by a resident.

After placement of a tourniquet at the level of the forearm, a superficial vein at the dorsum of the hand was punctured with a winged 18-gauge cannula (Insyte-W; Becton-Dickinson, Ermbodegem, Belgium), either bilaterally or unilaterally. If no vein in the hand could be punctured (six [16%] of 38 examinations), a superficial vein in the distal part of the forearm was cannulated. A vasodilator (nitroglycerin, 0.1 mg) was injected before venography to dilate the veins and to prevent vasospasm. The arm was positioned in supination and in slight abduction to enable anatomically positioned images without pseudostenosis in the axillary region. No complications occurred during the venographic procedures.

All CO₂ venograms were obtained with a CO₂ injector (CO₂ NNECT Auto-Flush Set; Angiodynamics, Queensbury, NY). The injection rate remained the same for all series (10 mL/sec). The first injection was always performed with a volume of 10 mL to accustom the patient to the sensation of a CO₂ injection. Thereafter, the volume varied between 10 and 30 mL for the upper-extremity veins and between 30 and 50 mL for the central veins. CO₂ injections were well

Advance in Knowledge

- CO₂ venography is an acceptable alternative (sensitivity, 97%; specificity, 85%; accuracy, 95%) for those patients with a contraindication to conventional venography with iodinated contrast material.

Published online before print
10.1148/radiol.2411050714

Radiology 2006; 241:291–297

Abbreviations:

AVF = arteriovenous fistula
CI = confidence interval

Author contributions:

Guarantors of integrity of entire study, all authors; study concepts/study design or data acquisition or data analysis/interpretation, all authors; manuscript drafting or manuscript revision for important intellectual content, all authors; manuscript final version approval, all authors; literature research, S.H.; clinical studies, S.H., G.M.; statistical analysis, S.H.; and manuscript editing, S.H., G.M.

Authors stated no financial relationship to disclose.

tolerated by all patients, without substantial discomfort.

Nonionic low-osmolarity iodinated contrast material (iohexol [Omnipaque], 240 mg of iodine per milliliter; GE Healthcare, Wemmel, Belgium) was used for conventional venography in all patients. For opacification of the upper-extremity veins, the axillary vein, and part of the subclavian vein, a digital subtraction angiographic series of the forearm and upper arm was performed by manually injecting 10 mL of iodinated contrast material per series. The medial part of the subclavian vein, the brachiocephalic vein, and the superior vena cava were opacified by manually injecting 20 mL of iodinated contrast material. If the flow was too slow in the central veins, additional manual compression of the upper arm was performed.

Image Analysis

All images were evaluated independently on a picture archiving and communication system workstation (Impax DS300; Agfa-Gevaert, Kontich, Belgium) by two vascular radiologists (S.H., G.M.) with 3 and 9 years of experience, respectively, in vascular and interventional radiology. The cannulation site (hand or wrist, radial or ulnar side) was noted for all examinations. The vein segments that were examined were the cephalic and basilic veins in the forearm and upper arm, the axillary vein, the subclavian vein, the brachiocephalic vein, and the superior vena cava. The categories used for evaluation were no opacification, segmental opacification, total opacification without stenosis, total opacification with stenosis of less than 50%, and total opacification with stenosis of 50% or more. Segmental opacification was defined as opacification of at least 75% of the vein. Occlusion of a vein was included in the "no opacification" category since the clinical consequence (no surgery at the given level) was the same for both circumstances. If the central veins could not be assessed adequately (owing to technical problems, such as respiratory motion artifacts or insufficient amount of contrast material reaching level of central veins), this was noted, and these seg-

ments were not used for calculation. All detected stenoses were graded by means of visual estimation; if a central venous catheter was present at the level of the stenosis, this was noted in the patient record.

The CO₂ and conventional venograms were evaluated in two different sessions. To prevent bias, the studies of different patients were presented in random order during both evaluation sessions. In the event of a discrepancy, the observers reached a consensus by reviewing the images.

Statistical Analysis

The interobserver agreement for CO₂ and conventional venography was evaluated by using the Cohen κ coefficient. A weighted version of κ was used for the 3 × 3 and 4 × 4 tables. The agreement

was calculated for the cephalic and basilic veins in both the forearm and the upper arm and for the axillary, subclavian, and innominate veins. Perfect agreement resulted in a κ value of 1; agreement expected on the basis of chance alone resulted in a κ value of 0. Confidence intervals (CIs) were only indicative, because they were constructed on the assumption of independent observations, and no CIs were calculated if the observed agreement was perfect. Sensitivity, specificity, and accuracy were calculated by using a dichotomous scale; findings of no opacification at both conventional and CO₂ venography were considered true-negative findings, and findings of opacification (any type) at both procedures were considered true-positive findings.

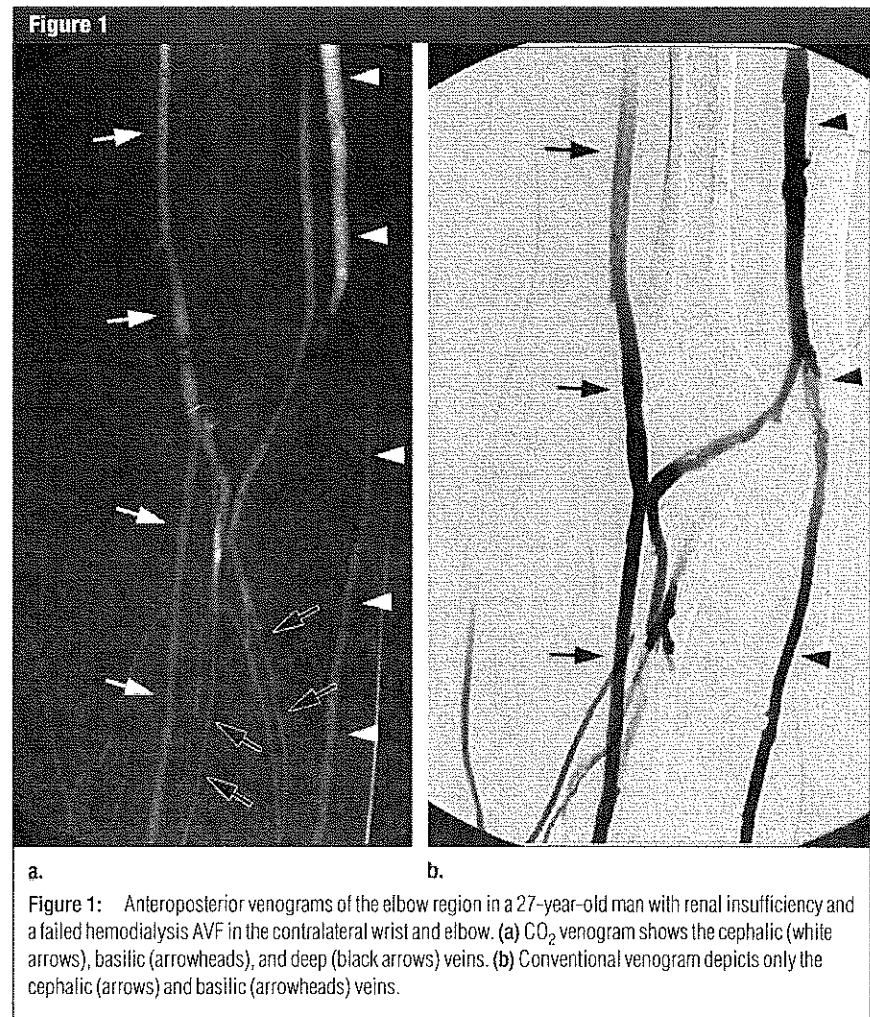


Figure 1: Anteroposterior venograms of the elbow region in a 27-year-old man with renal insufficiency and a failed hemodialysis AVF in the contralateral wrist and elbow. (a) CO₂ venogram shows the cephalic (white arrows), basilic (arrowheads), and deep (black arrows) veins. (b) Conventional venogram depicts only the cephalic (arrows) and basilic (arrowheads) veins.

Results differing by one or more categories were considered discrepant; the exception was segmental opacification versus total opacification without stenosis, because the clinical and therapeutic consequences for these categories would be the same. All analyses were performed with

the SAS (version 9.1) for Windows (SAS Institute, Cary, NC) statistical package.

Results

Most cannulations were performed in a superficial vein on the back of the hand,

more on the radial side (*n* = 21) than on the ulnar side (*n* = 11). In six of the 38 examinations (16%), however, this was not possible, so a superficial vein in the wrist (cephalic vein in five of six examinations) was punctured. Global interobserver agreement was high for both conventional and CO₂ venography, with a mean κ value of 0.96 (95% CI: 0.93, 0.99) for the conventional venographic studies and a mean κ value of 0.90 (95% CI: 0.84, 0.95) for the CO₂ series (Table 1).

Consensus results are presented in Table 2. Three segments were not used for the calculations of sensitivity, specificity, and accuracy (one brachiocephalic vein segment, two superior vena cava segments) because they were interpreted as not assessable at conventional or CO₂ venography. Conventional venography failed to depict these segments because of technical problems (too slow flow and/or important motion artifacts), while CO₂ venography revealed patent vein segments.

With conventional venography used as the reference standard, the sensitivity, specificity, and accuracy of CO₂ venography were 97% (95% CI: 94%, 98%), 85% (95% CI: 69%, 94%), and 95% (95% CI: 92%, 98%), respectively (Figs 1, 2). Results were discrepant in 20 of 285 vein segments (7.0%). Seven vein segments (35%) were not seen with CO₂ venography, although conventional venography revealed segmental or total opacification. This discrepancy occurred only with regard to the cephalic and basilic veins in the forearm (Fig 3). In five of 20 segments (25%), the cephalic vein in the upper arm was either segmentally or totally opacified with CO₂, but conventional venography did not depict this segment. This also occurred with one cephalic vein segment in the forearm.

Stenosis was underestimated in the central veins in six of 20 segments (30%). In four segments, conventional venography revealed less than 50% stenosis of the subclavian and brachiocephalic veins, but CO₂ venography depicted normal patent segments. In one segment, CO₂ venography was unable to depict stenosis of 50% or more in the subclavian vein, and in one segment,

Table 1

Interobserver Agreement for the Different Vein Segments

Vein Segment	CO ₂ Venography		Conventional Venography	
	κ Value	95% CI	κ Value	95% CI
Forearm				
Cephalic vein	0.94	0.86,1.00	1.00	...
Basilic vein	0.70	0.50,0.91	0.92	0.80,1.00
Upper arm				
Cephalic vein	0.90	0.78,1.00	0.97	0.91,1.00
Basilic vein	1.00	...	1.00	...
Axillary vein	1.00	...	1.00	...
Subclavian vein	0.84	0.62,1.00	0.86	0.71,1.00
Innominate vein	1.00	...	1.00	...
Superior vena cava	1.00	...	1.00	...

Figure 2

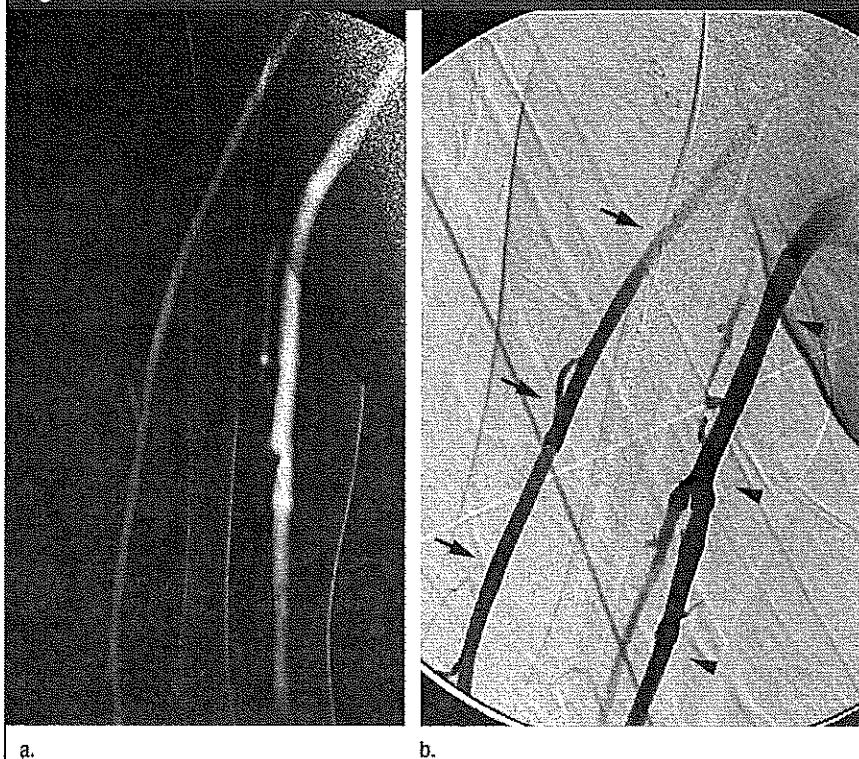


Figure 2: Anteroposterior venograms of the right upper arm in the 27-year-old man described for Figure 1. (a) CO₂ and (b) conventional venograms show patent cephalic (arrows) and basilic (arrowheads) veins.

stenosis of 50% or more was interpreted as stenosis of less than 50%. In five of the six segments, a central vein dialysis catheter was present at the stenosis site (four inserted via the subclavian vein and one inserted via the internal jugular vein). In the sixth segment, conventional venography revealed subclavian vein stenosis at the level of the clavicle, which was probably due to imperfect subtraction images (caused by motion artifacts).

In one segment (5%), stenosis was overestimated with CO₂ venography: A stenosis of 50% or more was observed at the level of the subclavian vein compared with a finding of no stenosis at conventional venography. A subclavian vein catheter for hemodialysis was present at the stenosis site (Fig 4).

Discussion

Preoperative evaluation of the veins in the upper extremity before creation of a fistula for hemodialysis access is usually conducted by means of physical examination. However, if the superficial veins are poorly developed or not visible throughout their course, or if evaluation of these veins is difficult owing to obese arms, previous multiple venopunctures, or previous surgical AVFs, venography is the investigation modality of choice. Another indication for preoperative venography is the evaluation of the central veins to assess for possible stenosis, especially in patients with a history of central venous catheters (2,7).

CO₂ venography has been recommended as a useful alternative to conventional venography (5,6), and our study results confirm these findings. Overall interobserver agreement was almost perfect (8) for vein evaluation with conventional and CO₂ venography, indicating that CO₂ venography is a reproducible technique.

The problem of central veins not being assessable or visible with iodinated contrast material because of technical problems such as too slow flow or motion artifacts can be avoided in most cases by performing an additional cannulation of a cubital vein to shorten the distance between the contrast material

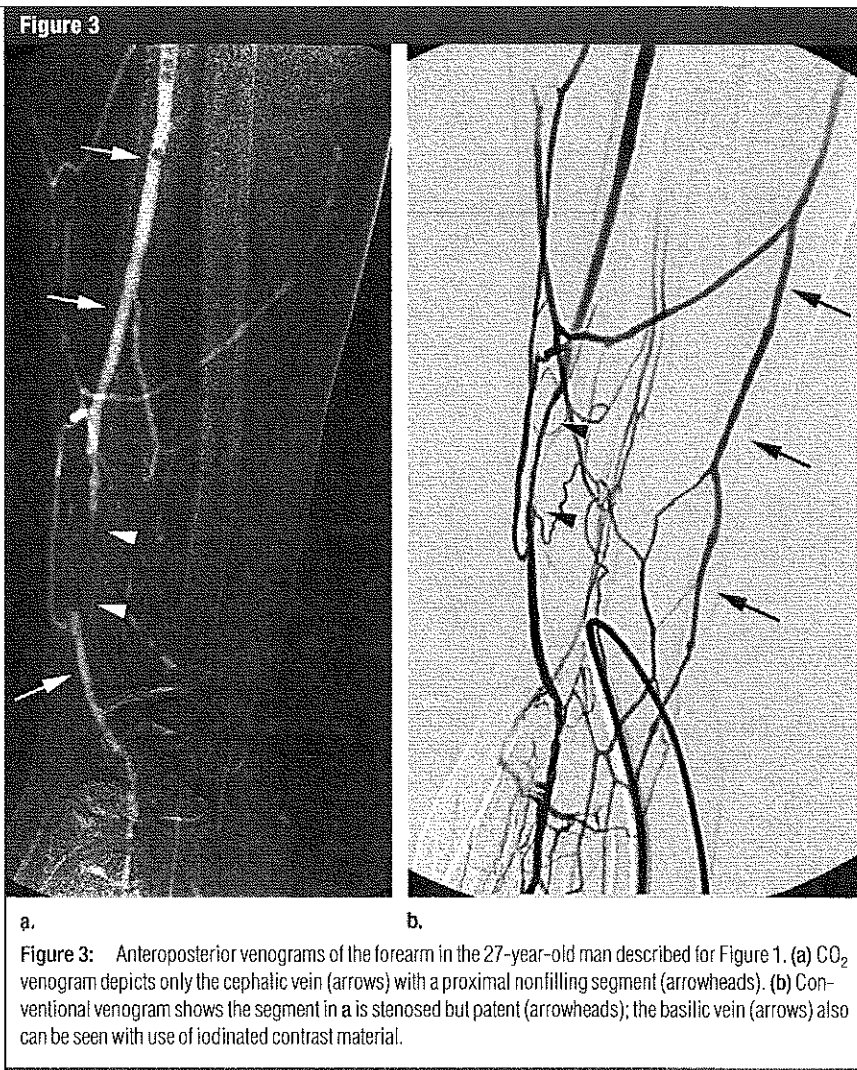


Figure 3: Anteroposterior venograms of the forearm in the 27-year-old man described for Figure 1. (a) CO₂ venogram depicts only the cephalic vein (arrows) with a proximal nonfilling segment (arrowheads). (b) Conventional venogram shows the segment in a is stenosed but patent (arrowheads); the basilic vein (arrows) also can be seen with use of iodinated contrast material.

injection site and the central veins. However, even with this adaptation, these vein segments may not be assessable, typically because the venous flow remains too slow or the patient's clinical condition is poor. In such instances, CO₂ can be very valuable for showing the patency of the central venous structures, as mentioned by Sullivan et al (5).

The high sensitivity of CO₂ venography with only moderate specificity can affect treatment decisions. For venography performed before hemodialysis access, high sensitivity is most important, because false-positive findings will result in failed surgery (because a vein is actually absent or stenosed, increasing the risk that a surgical AVF will not

mature sufficiently). False-positive findings, however, are more preferable than false-negative findings, which may result in a patient not receiving an AVF even though the vein is patent.

The veins in the forearm are less opacified with CO₂ than with iodinated contrast material. The reason for this difference could be the low viscosity of CO₂ (about 400 times less viscous than iodine). In our study, after iodinated contrast material was injected into the radial side of the hand dorsum, the cephalic vein was visualized and the basilic vein also was opacified owing to contrast material reaching this vessel through small superficial veins in the forearm. CO₂ proceeded more straight-

forwardly in the cephalic vein, and those small superficial veins were less often opacified. A possible solution to this problem may be to use a tourniquet, which is commonly used in some centers to fill collaterals to the basilic vein and to evaluate the possible distention of the veins (9). A disadvantage of using a tourniquet is the vasospasm that

may occur and that may even be resistant to vasodilative drugs.

Underestimation of the stenosis grade at CO₂ venography, compared with that at conventional venography, occurred more frequently than overestimation. These findings differ from those of some other studies (10,11), in which the degree of stenosis was consistently

overestimated with CO₂ venography. Such overestimation can occur because CO₂ begins to dissolve in the blood immediately after intraarterial injection, and slow blood flow accentuates this dissolution owing to a longer period of blood-gas contact (12).

Moresco et al (13), however, demonstrated that CO₂ yielded significantly larger vessel diameter compared with conventional angiography and intravascular ultrasonography in an aortoiliac flow model. They assumed that this difference may be caused by the elastic nature of the vessel walls and the explosive nature of CO₂ at the moment it exits the injection catheter (13). This may at least partially explain the underestimation of the degree of stenosis, especially in patients with relatively large central vein catheters for hemodialysis, in whom the luminal diameter may sometimes be more difficult to determine.

Our study had several limitations. First, the number of patients was relatively small. Second, the presence of central venous catheters—which were necessary because they served as temporary hemodialysis catheters—made evaluation of vein stenosis more difficult. Third, to enable statistical analysis, we used the term *occlusion* to describe those segments that were not opacified at venography. However, this term is not completely correct: There may be causes other than occlusion for a nonvisualized vein, such as vasospasm or simple nonfilling of the vein (caused by too slow flow or preferential filling of other veins). The clinical consequences for either nonopacified or occluded veins, however, would be the same. Finally, our results were undoubtedly influenced by our venography technique, which did not include the use of tourniquets. Tourniquets have the advantages of revealing more veins, especially in the forearm, and demonstrating the diameters of dilated veins. The risk of inducing vasospasm, however, is a disadvantage.

In conclusion, compared with conventional venography as the reference standard, CO₂ venography allows assessment of the upper-limb veins before the creation of hemodialysis access fistulas, with a sensitivity of 97% and a

Table 2

Consensus Results for CO₂ and Conventional Venography

Findings at CO ₂ Venography	Findings at Conventional Venography					Total
	No Opacification	Segmental Opacification	Total Opacification Without Stenosis	Total Opacification With Stenosis < 50%	Total Opacification With Stenosis ≥ 50%	
No opacification	33	4	3	0	0	40
Segmental opacification	4	14	6	0	0	24
Total opacification						
Without stenosis	2	2	202	4	1	211
With stenosis < 50%	0	0	0	7	1	8
With stenosis ≥ 50%	0	0	1	0	1	2
Total	39	20	212	11	3	285

Note.—Results are given as numbers of vein segments.

Figure 4

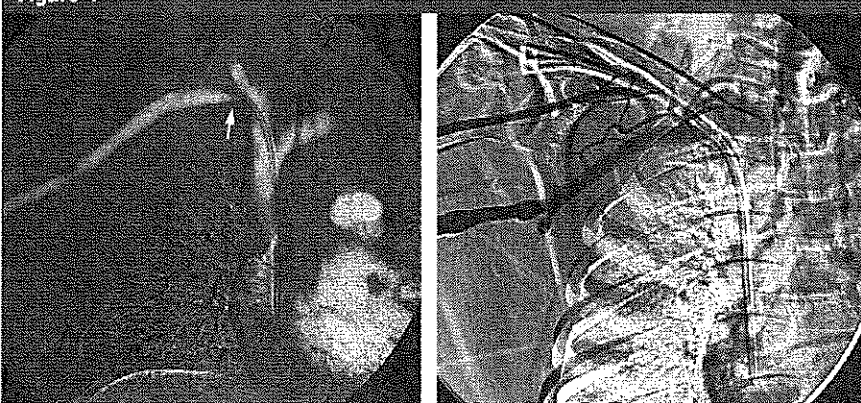


Figure 4: Anteroposterior venograms of the right central veins in the 27-year-old man described for Figure 1. (a) CO₂ venogram shows patency of the central veins but also stenosis (arrow) of the subclavian vein at the level of the central venous catheter. (b) Conventional venogram shows the innominate vein and superior vena cava are not assessable because of motion artifacts caused by respiration and too slow flow in the central veins.

specificity of 85%. We believe it could be an acceptable alternative for those patients with a contraindication to conventional venography with iodinated contrast material, such as residual renal function or allergy.

References

1. Menegazzo D, Laissy JP, Durrbach A, et al. Hemodialysis access fistula creation: preoperative assessment with MR venography and comparison with conventional venography. *Radiology* 1998;209:723-728.
2. Robbin ML, Gallichio MH, Deierhoi MH, Young CJ, Weber TM, Alon M. US vascular mapping before hemodialysis access placement. *Radiology* 2000;217:83-88.
3. Oliva VL, Denbow N, Thérasse E, et al. Digital subtraction angiography of the abdominal aorta and lower extremities: carbon dioxide versus iodinated contrast material. *J Vasc Interv Radiol* 1999;10:723-731.
4. Diaz LP, Pinto IP, Garcia JA, de la Cal Lopez MA. Assessment of CO₂ arteriography in arterial occlusive disease of the lower extremities. *J Vasc Interv Radiol* 2000;11:163-169.
5. Sullivan KL, Bonn J, Shapiro MJ, Gardiner GA. Venography with carbon dioxide as a contrast agent. *Cardiovasc Intervent Radiol* 1995;18:141-145.
6. Hahn ST, Pfammatter T, Cho KJ. Carbon dioxide gas as a venous contrast agent to guide upper-arm insertion of central venous catheters. *Cardiovasc Intervent Radiol* 1995;18:146-149.
7. Turmel-Rodrigues L, Bourquelot P, Raynaud A, Beyssen B, Sapoval M. Hemodialysis fistula: preoperative MR venography—a promising but partial view. *Radiology* 2000;214:302-303.
8. Landis JR, Koch GC. The measurement of observer agreement for categorical data. *Biometrics* 1977;33:159-174.
9. Raynaud AC. Venography before angioaccess creation. In: Gray RJ, Sands JJ, eds. *Dialysis access: a multidisciplinary approach*. Philadelphia, Pa: Lippincott Williams & Wilkins, 2002; 67-73.
10. Ehrman KO, Taber TE, Gaylord GM, Brown PB, Hage JP. Comparison of diagnostic accuracy with carbon dioxide versus iodinated contrast material in the imaging of hemodialysis access fistulas. *J Vasc Interv Radiol* 1994;5:771-775.
11. Black CM, Laug EV, Kusnick CA, et al. 1996 AUR Memorial Award: densitometric analysis of eccentric vascular stenoses—comparison of CO₂ and iodinated contrast media. *Acad Radiol* 1996;3:985-993.
12. Kerns SR, Hawkins IF Jr. Carbon dioxide digital subtraction angiography: expanding applications and technical evolution. *AJR Am J Roentgenol* 1995;164:735-741.
13. Moresco KP, Patel N, Johnson MS, Trobridge D, Bergan KA, Lalka SG. Accuracy of CO₂ angiography in vessel diameter assessment: a comparative study of CO₂ versus iodinated contrast material in an aortoiliac flow model. *J Vasc Interv Radiol* 2000;11:437-444.